

Endovascular Stent Grafting for Isolated Spontaneous Dissection of the Superior Mesenteric Artery by Transradial Approach

Case Presenter : Sung Gyun Ahn

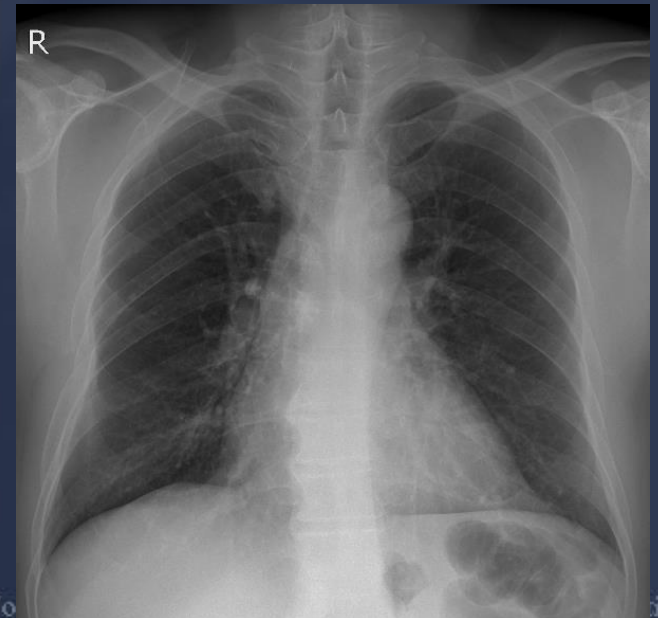
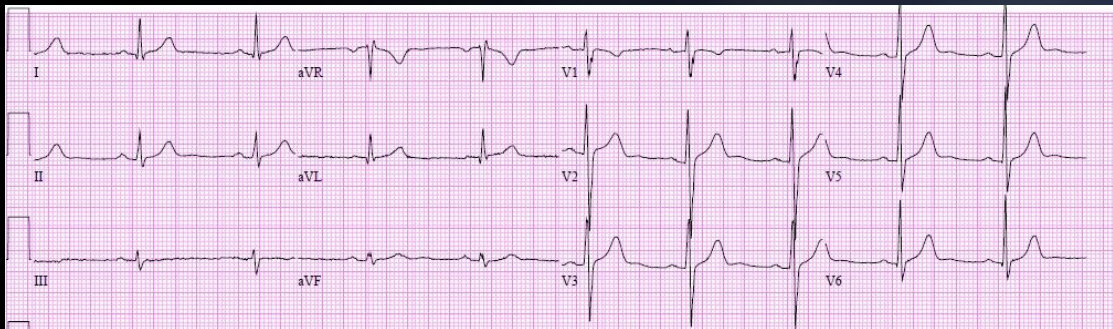
Operator : Sung Gyun Ahn

Wonju Christian Hospital, Wonju College of Medicine,
Yonsei University

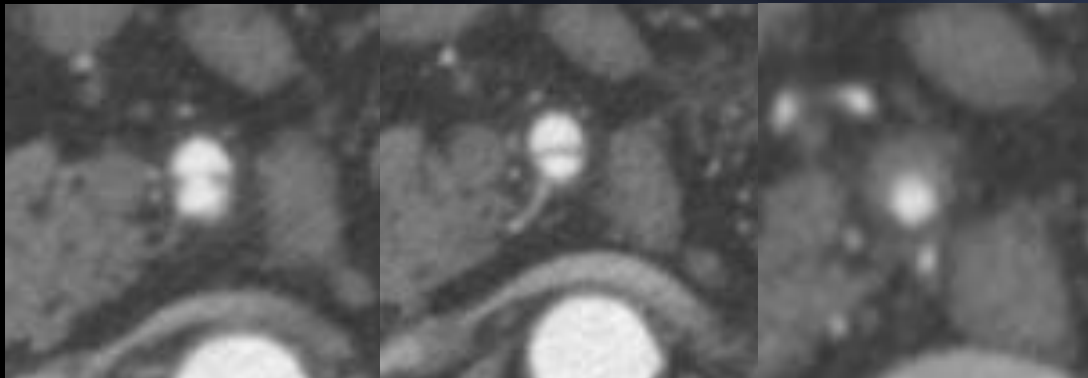
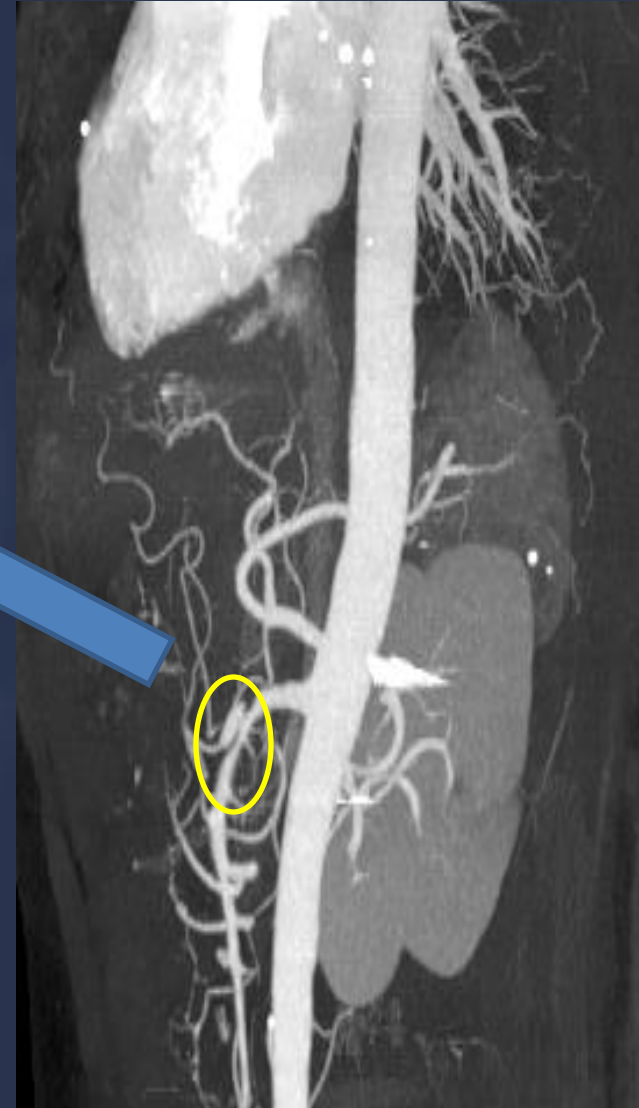
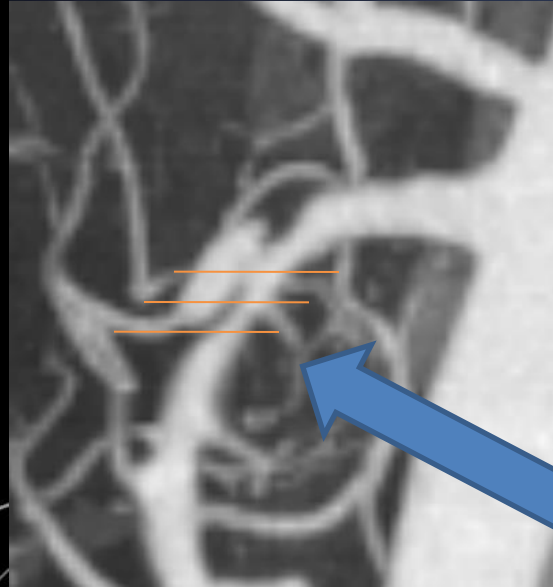
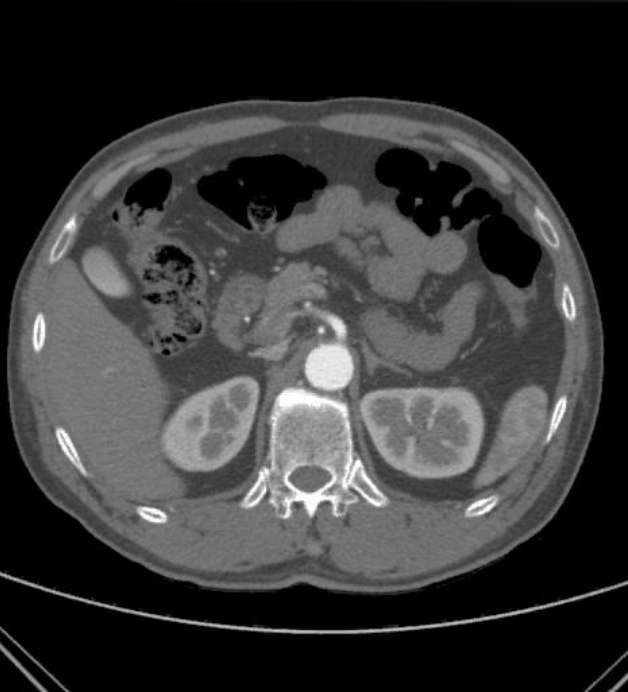

Case

- A 56-year-old male
- C.C. & Duration: Abrupt onset of epigastric and back pain for 4 hr
- No CAD risk factors except for current smoking
- P.I.: Referred from a local clinic with suspicion of the superior mesenteric artery(SMA) thrombosis on abdominal CT scan



Celiac & SMA CT Angiography



How would you treat?

I. Medical therapy

- A. Watch & see
- B. Only aspirin (&/or Clopidogrel)
- C. Anticoagulation
- D. BB?



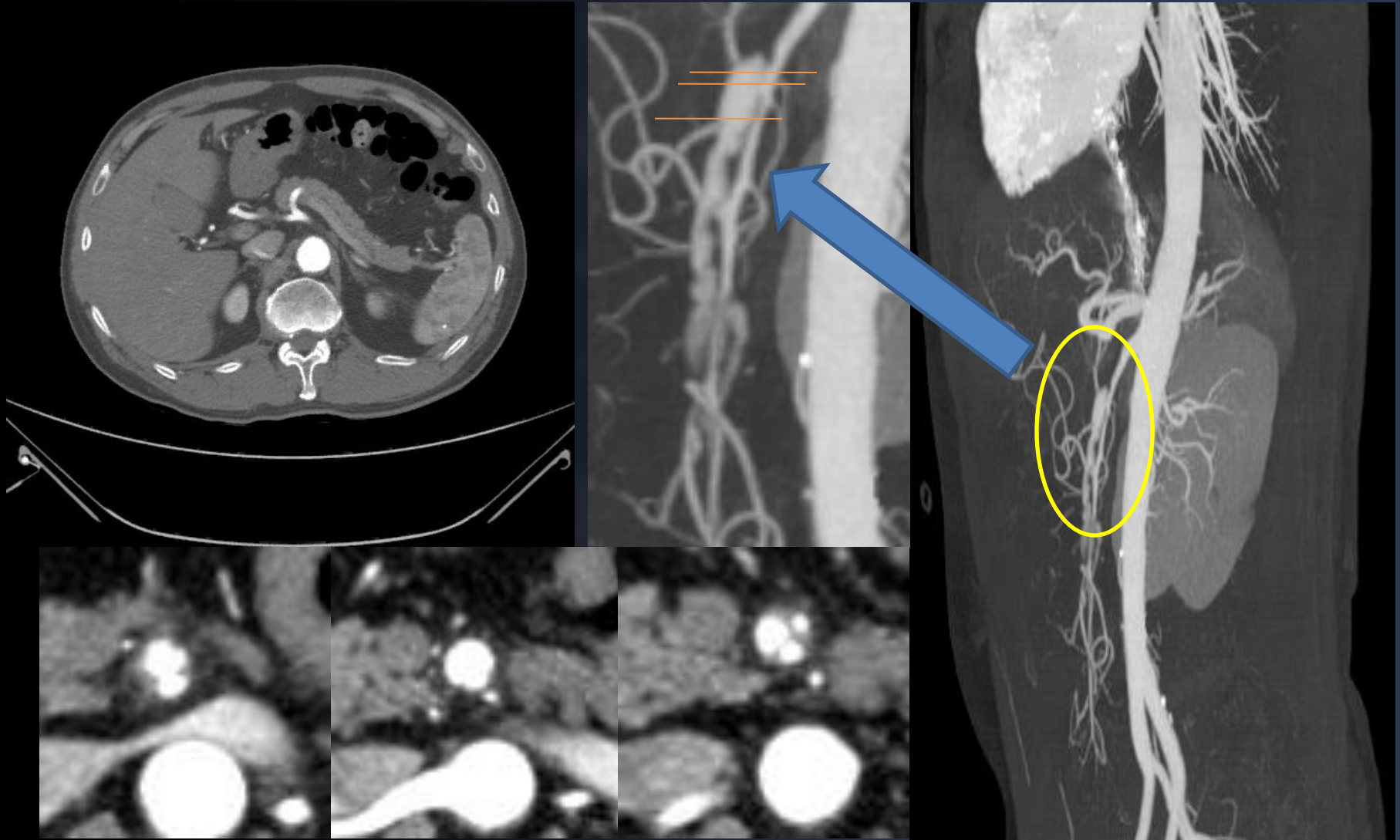
VS

II. Intervention

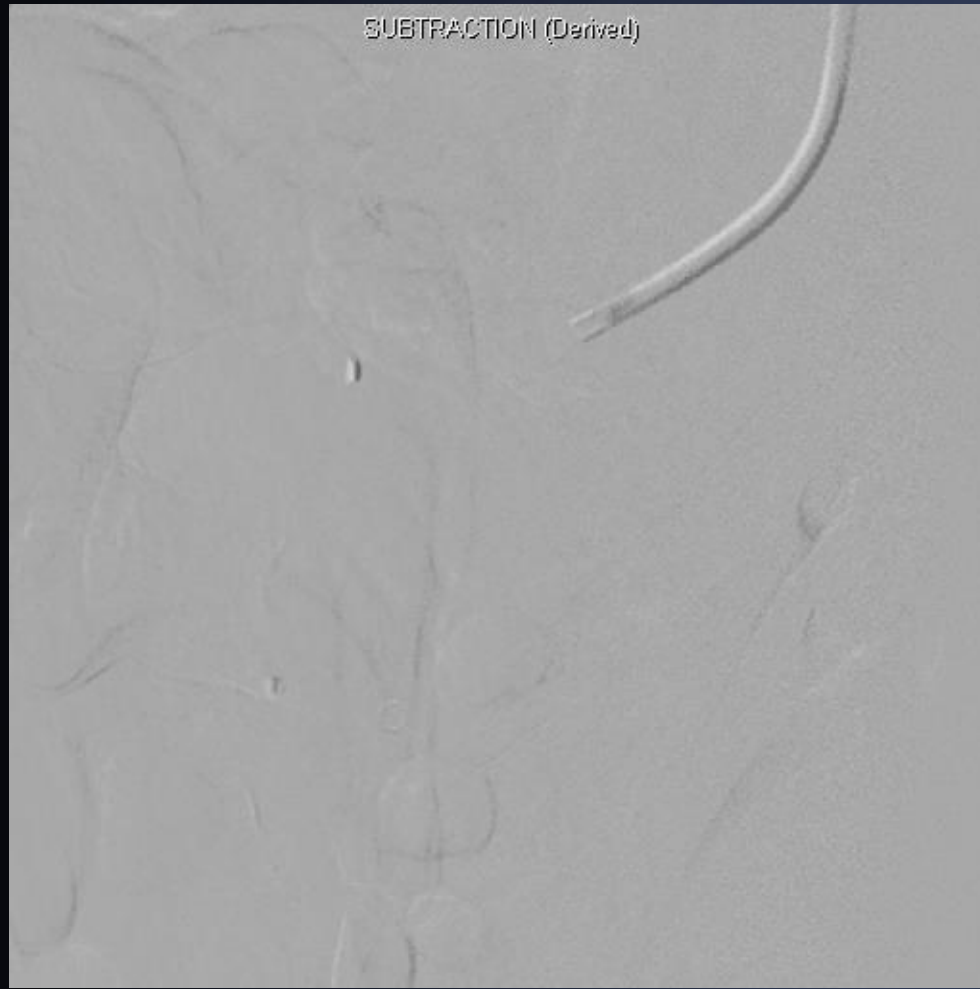- A. Endovascular intervention
- B. Surgical repair



F/U Celiac & SMA CTA at 1 wk



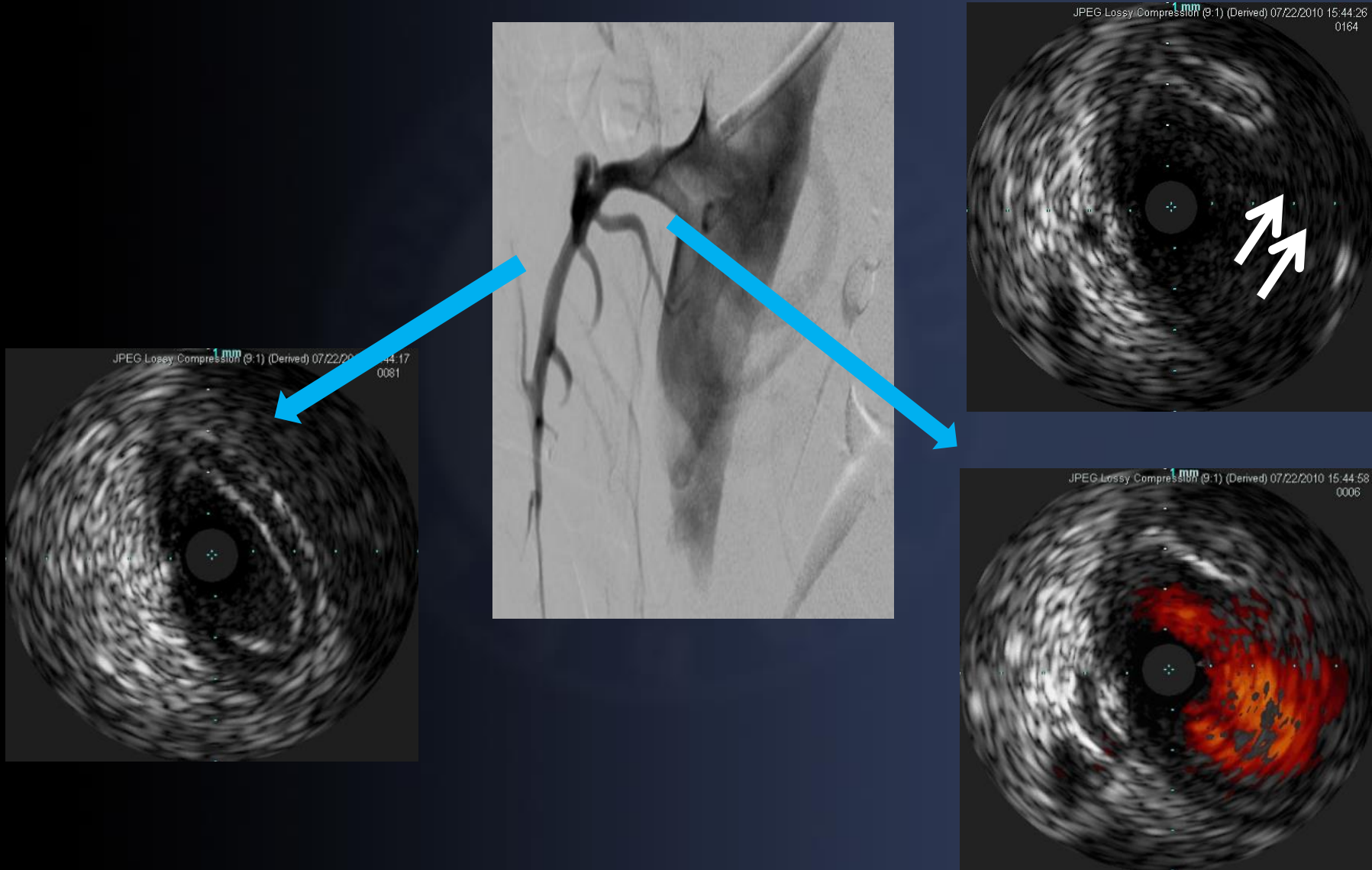
DSA SMA angiography



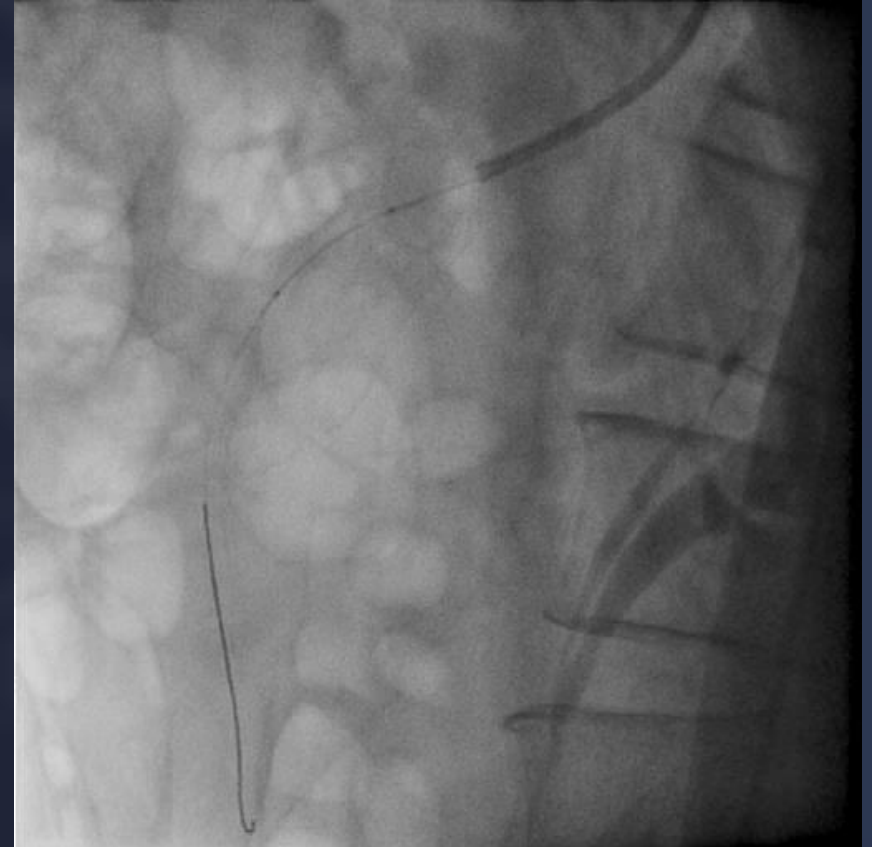
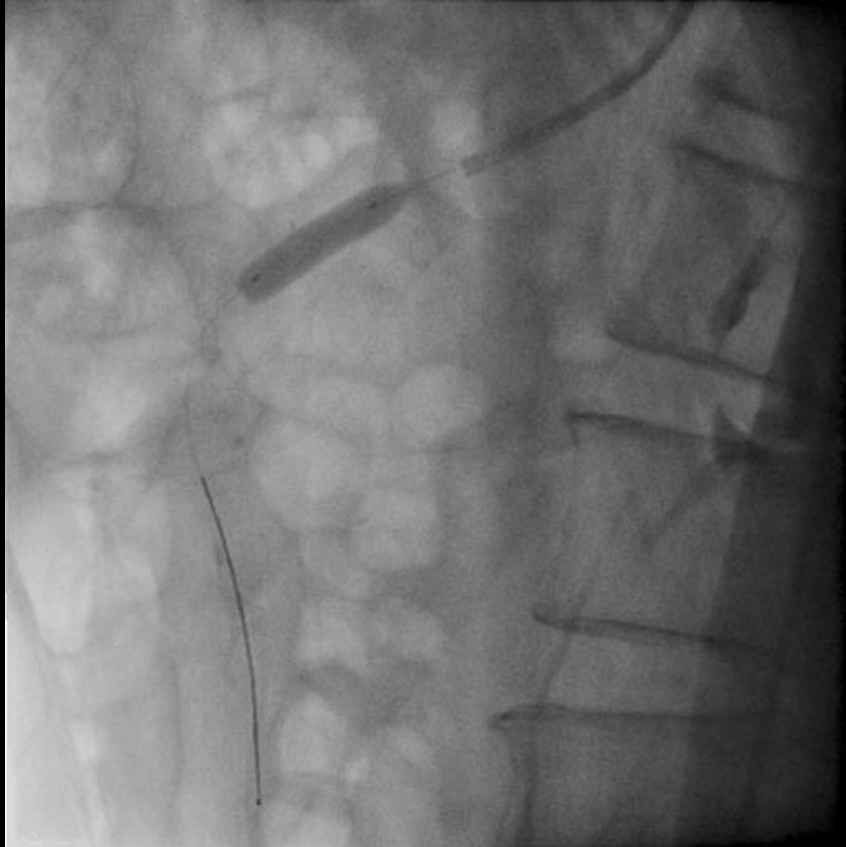
Lt. radial approach, 7Fr MPA1



IVUS interrogation



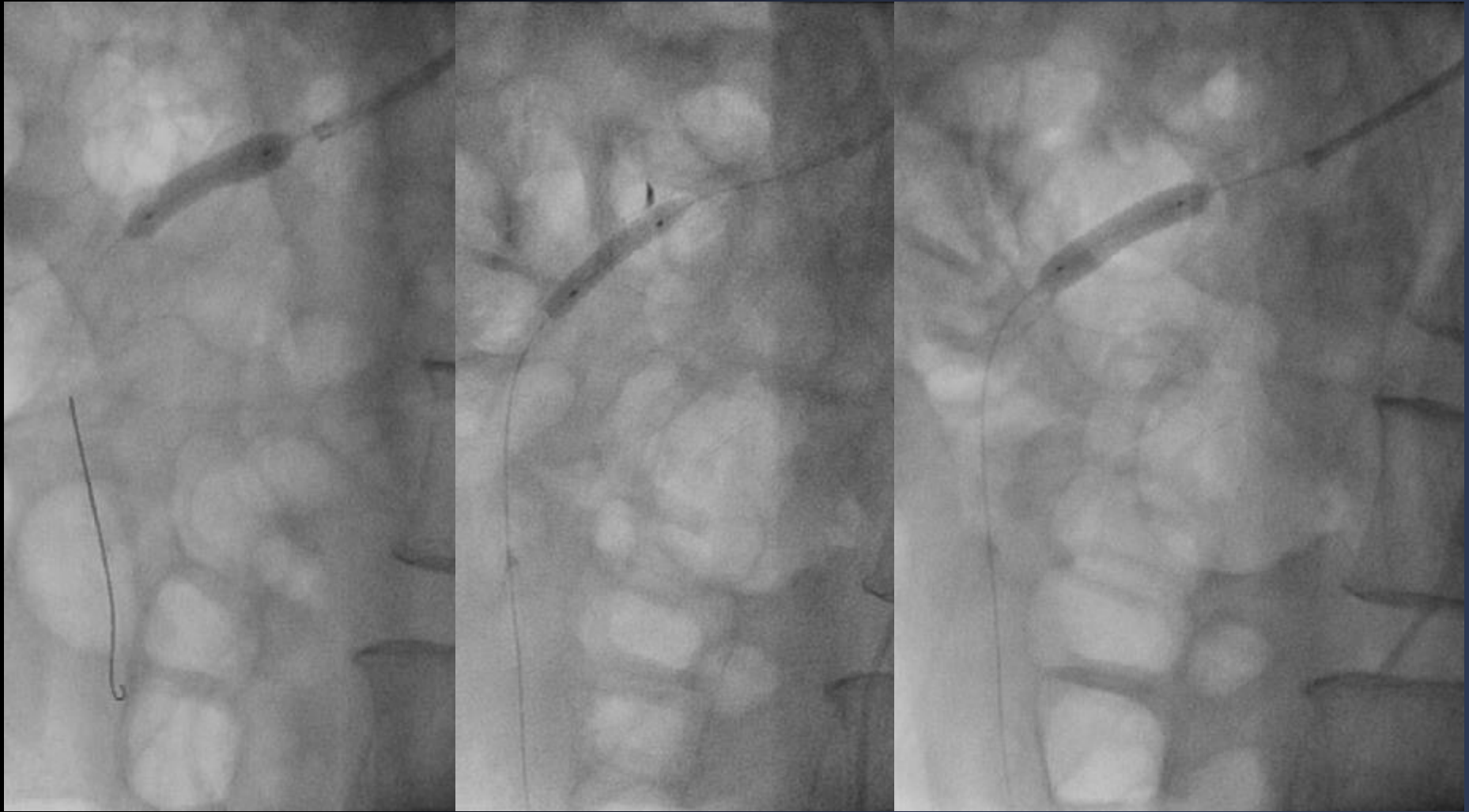Occlusion Ballooning



Aviator 6 x 20 mm, up to 6 ATM for 470 sec



Graft Stenting

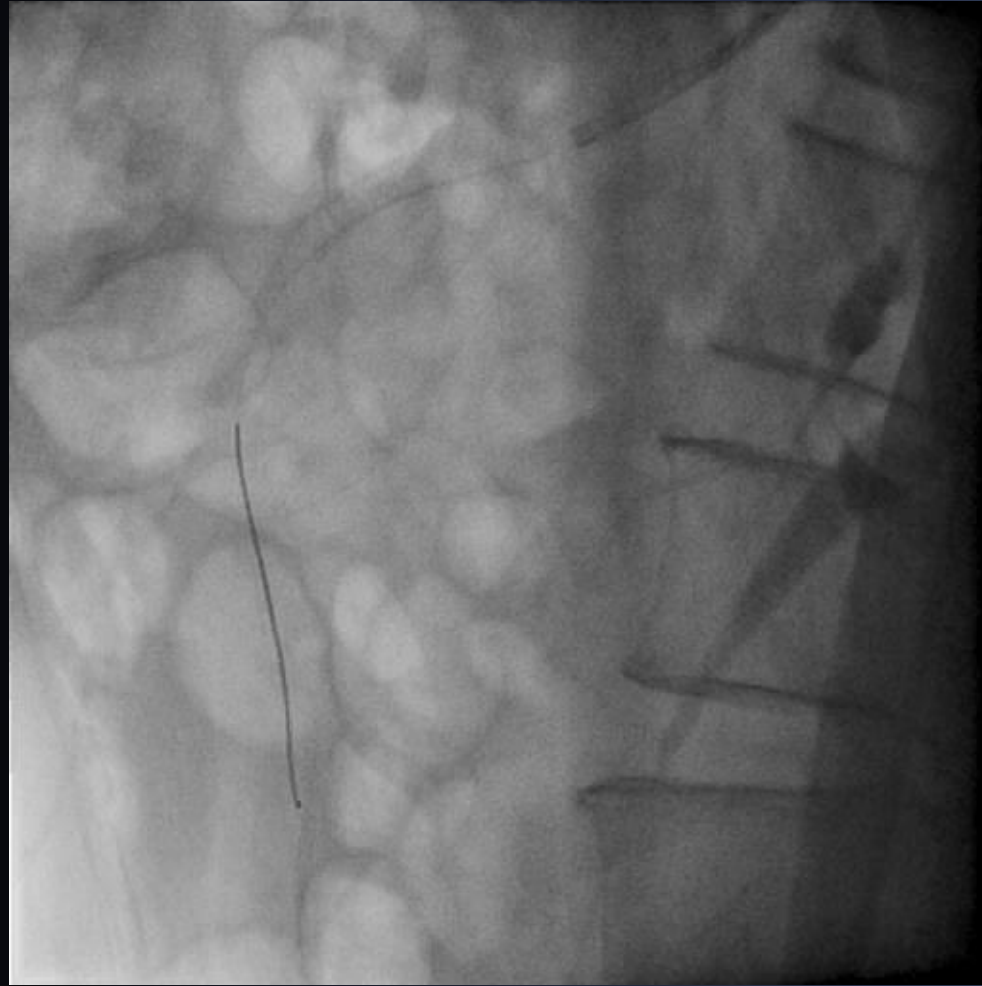

Graftmaster 3.5 x 19 + 3.5 x 16 mm up to 20 atm

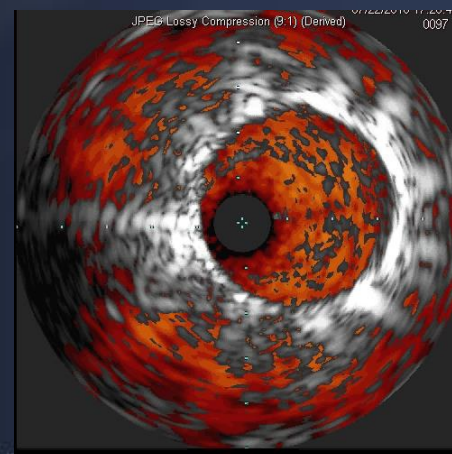
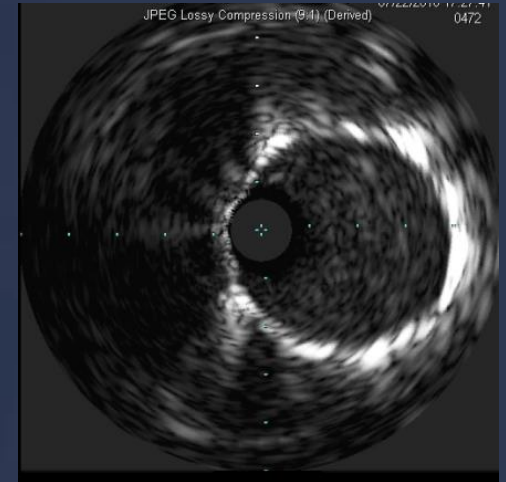
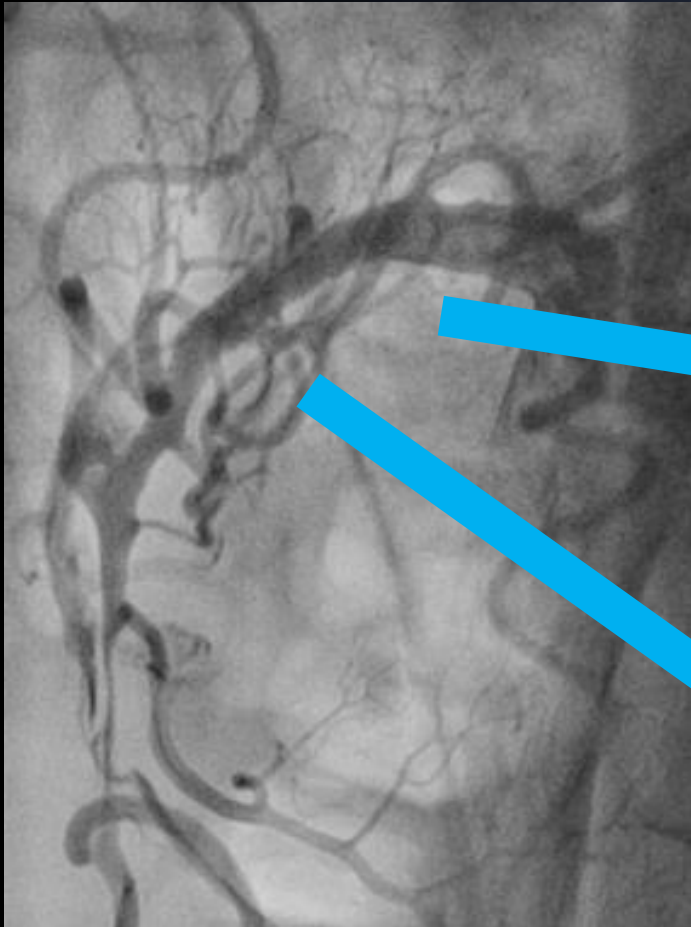
Aviator 6 x 20 mm at 6 atm



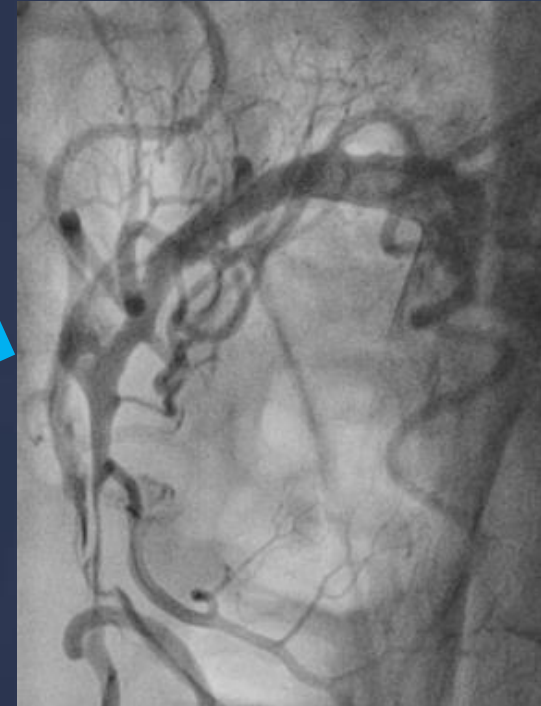
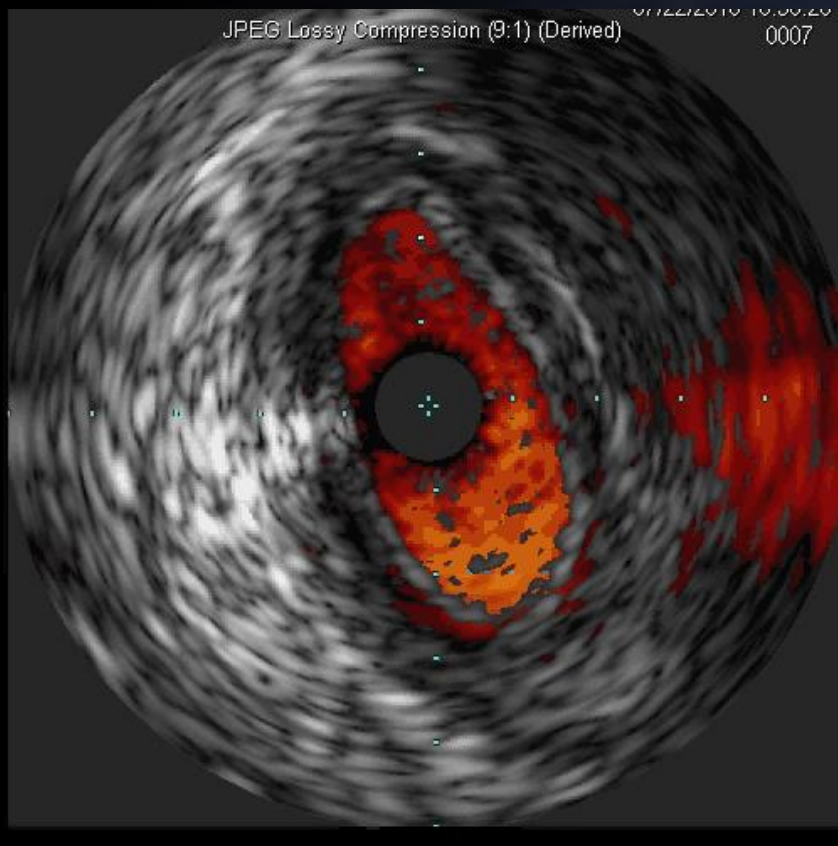
Final Angiography



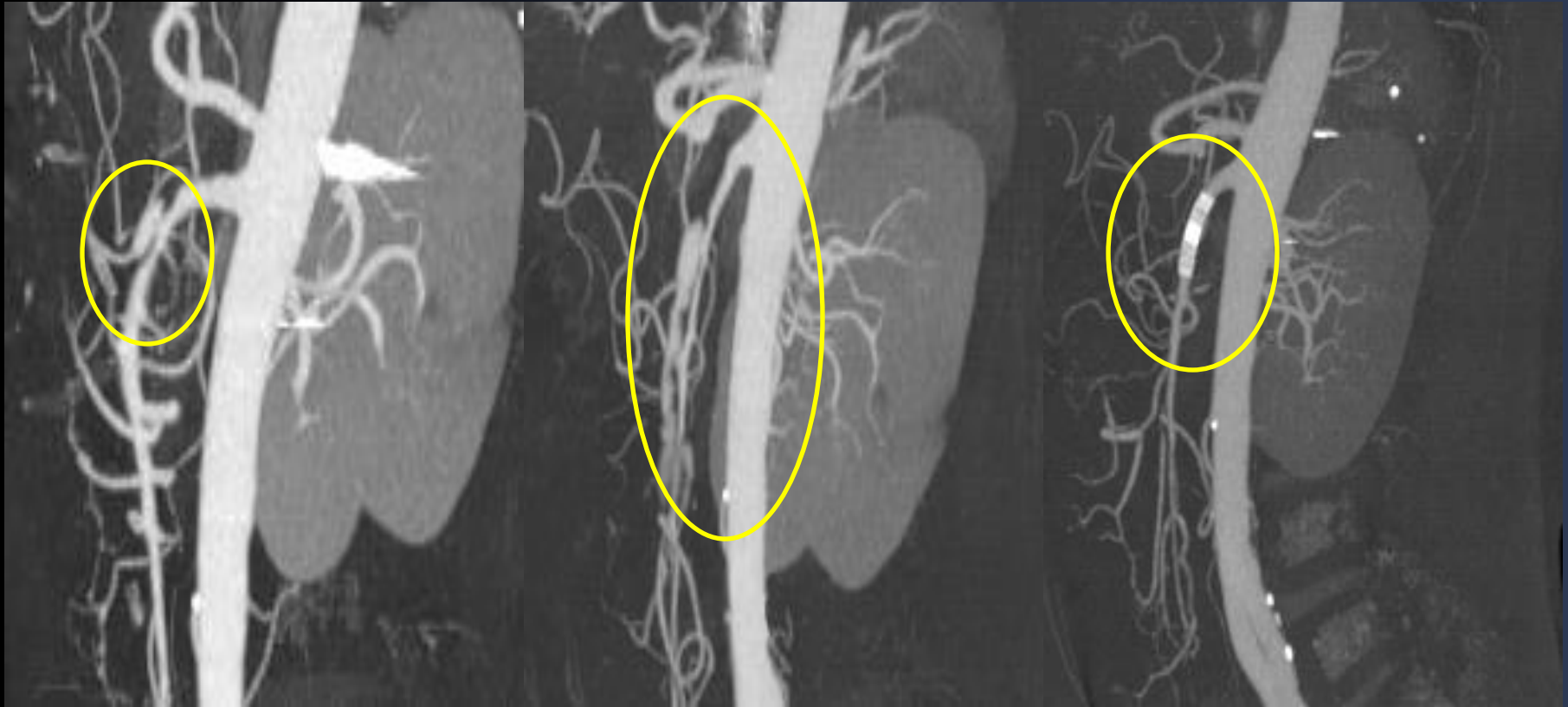Final IVUS (1)



Final IVUS (2)



Follow CTA scan



Initial

1 wk

1month

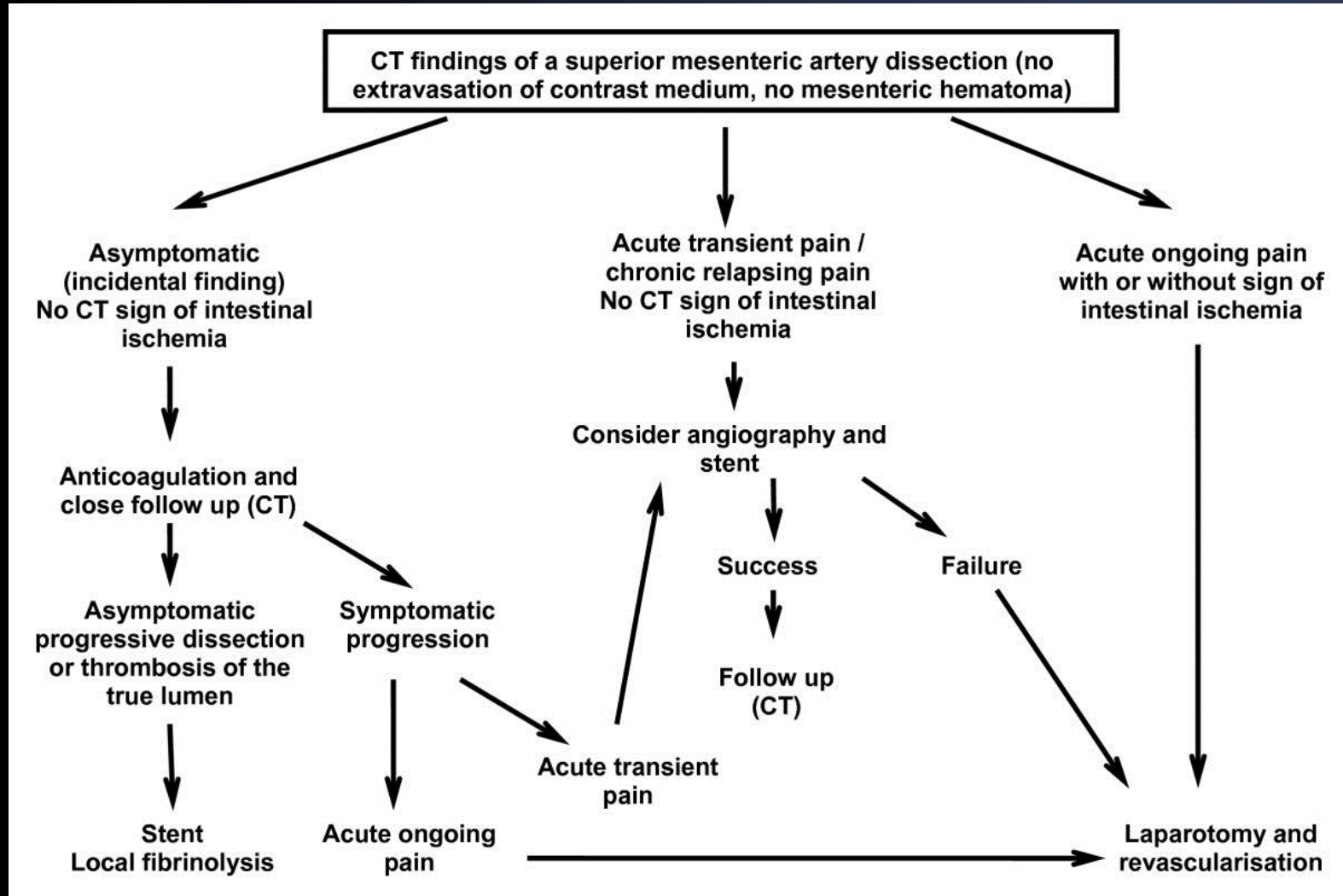


Discussion Points

1. What would be the optimal treatment for this patients?
 - Medical treatment
 - Aspirin (and/or clopidogrel)
 - Anticoagulation
2. Which type of stent between graft stent and bare-metal stent would be better ?
3. TFI vs. TRI



Algorithm of Tx for Isolated SMA dissection





Case Report:

Successful recanalization of chronic total occlusion of the superior mesenteric artery by transradial approach

Woo Taek KIM, Sung Gyun AHN, Jun-Won LEE, Joong Kyung SUNG, Seung Hwan LEE, Junghan YOON^{†‡}

(Division of Cardiology, Wonju College of Medicine, Yonsei University, Wonju 220-701, Korea)

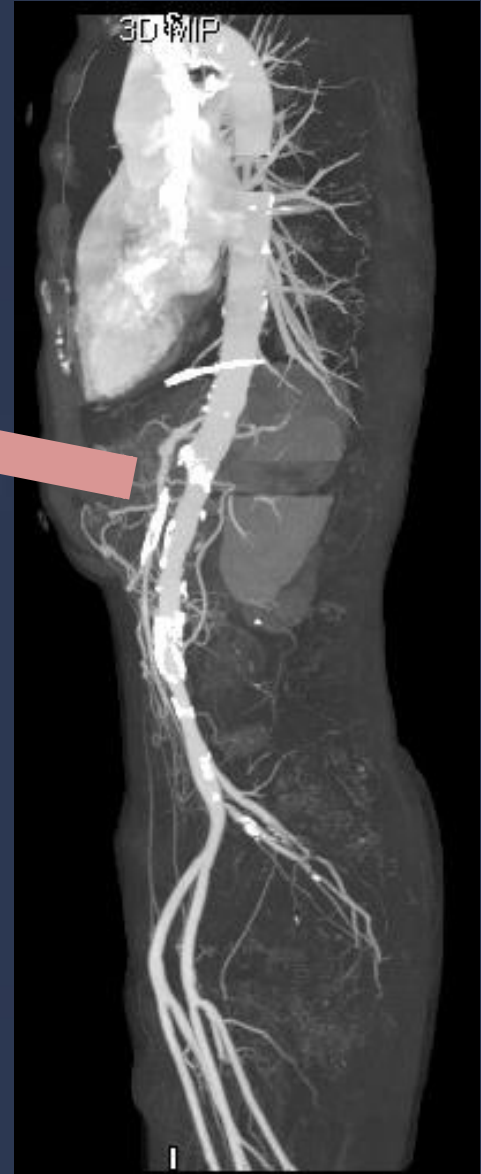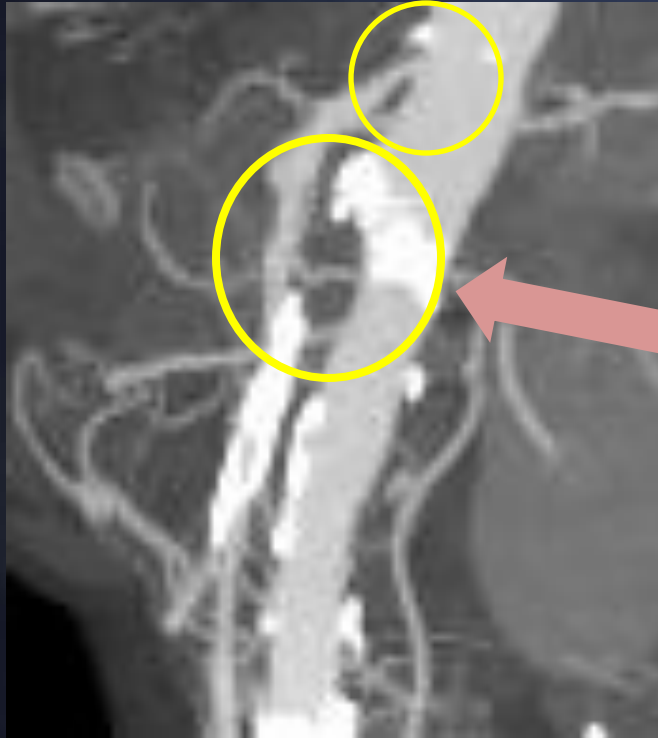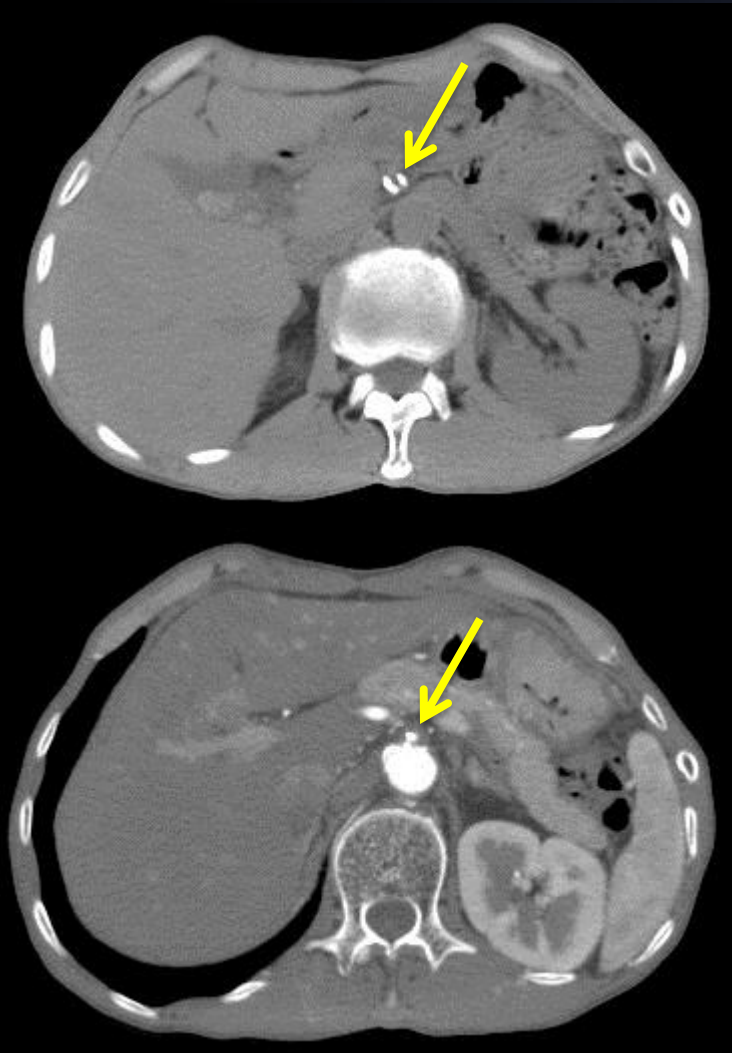
[†]E-mail: jyoona@yonsei.ac.kr

Received June 30, 2010; Revision accepted July 15, 2010; Crosschecked July 6, 2010



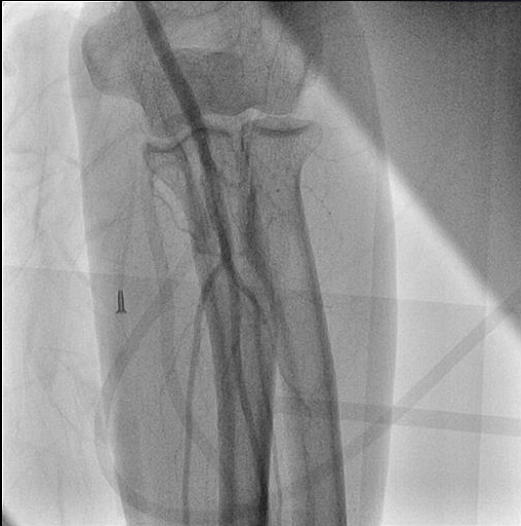SMA CTO (58/M)

postprandial pain, weight loss

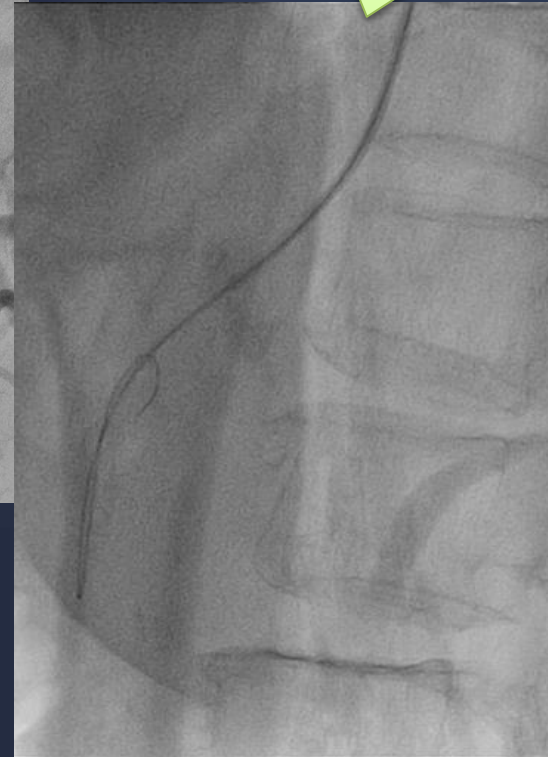
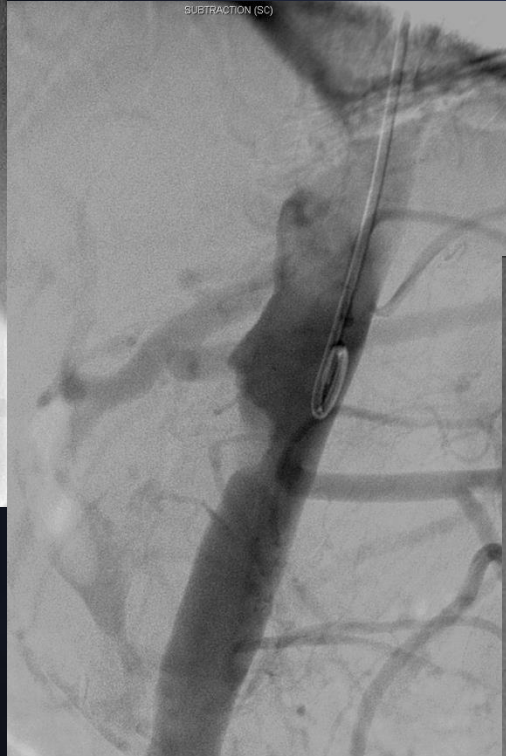

SMA total occlusion (1.8cm)
with calcification
Celiac a. significant stenosis

Lt Radial Approach



6 Fr introducer sheath (12cm)

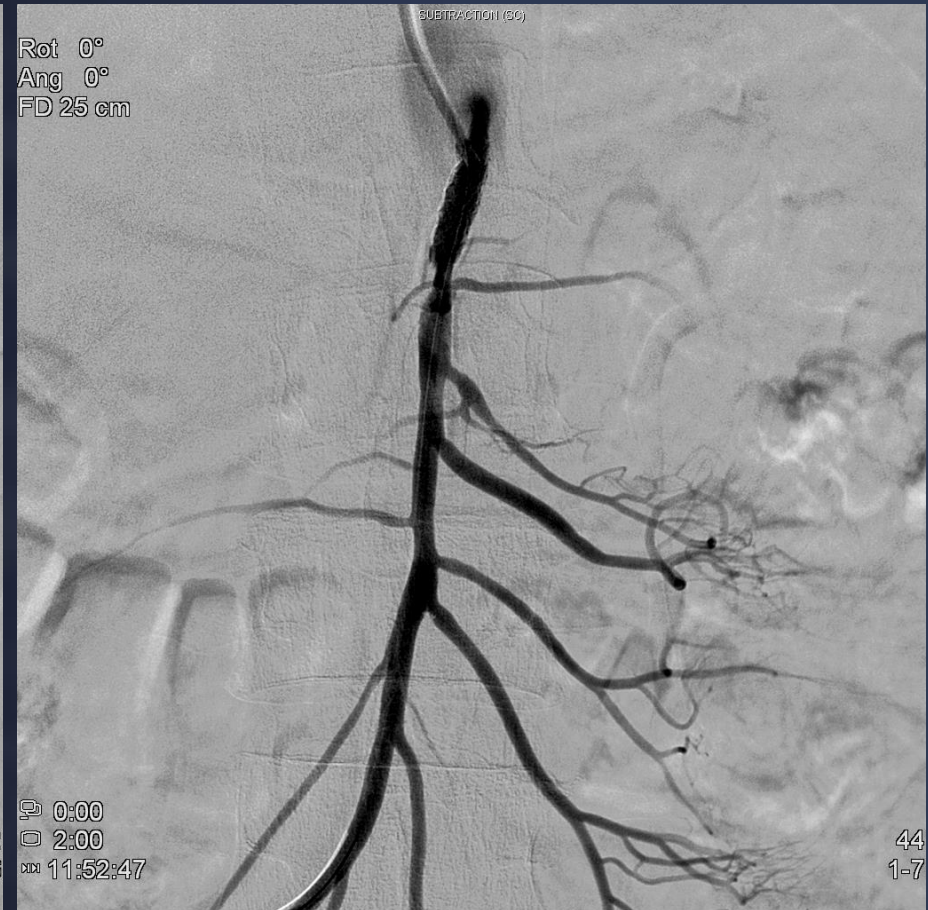
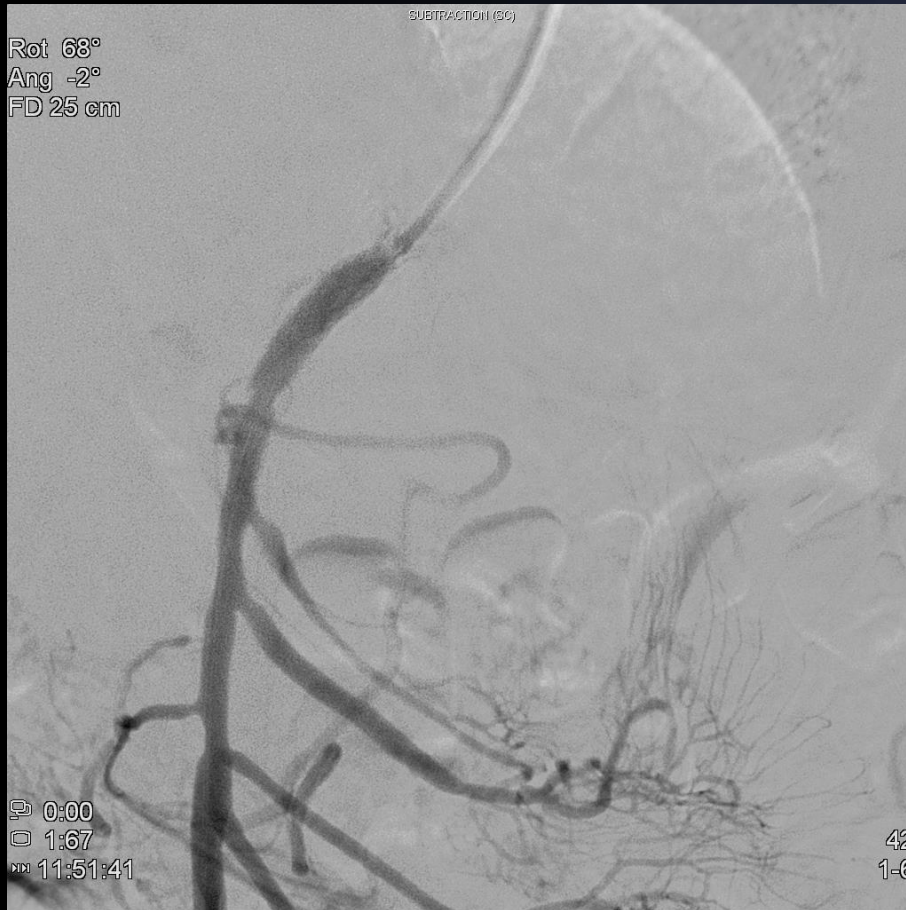
6 Fr MPA1

Ideal Coaxial alignment
&
Good back-up



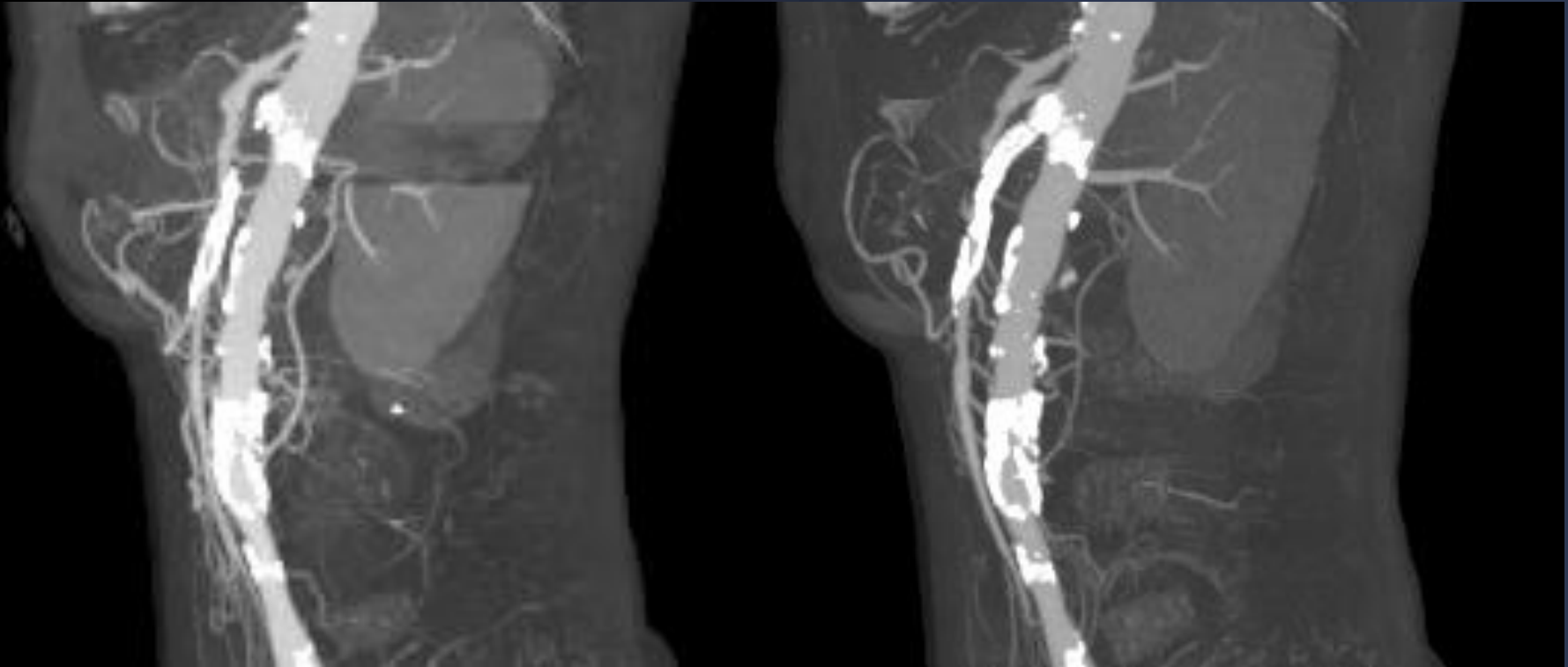
Final angiography



Final angiogram showed fully recovery of the flow on SMA.
Minimal dissection on the distal stent was observed,
but the lumen area was expanded enough.



Follow up CTA



Before

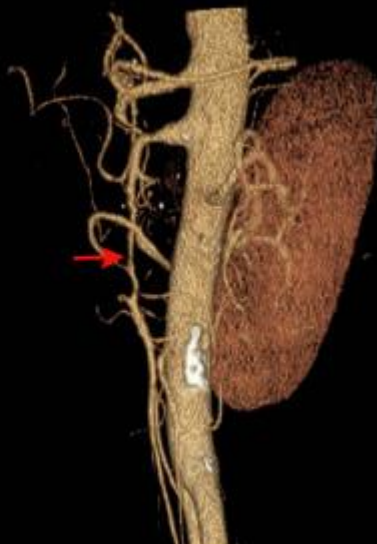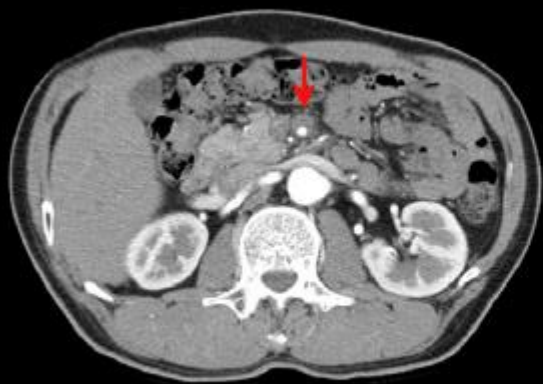3 months after

GENESIS (Cordis[®], USA) 6.0 x 24 mm (12 atm)

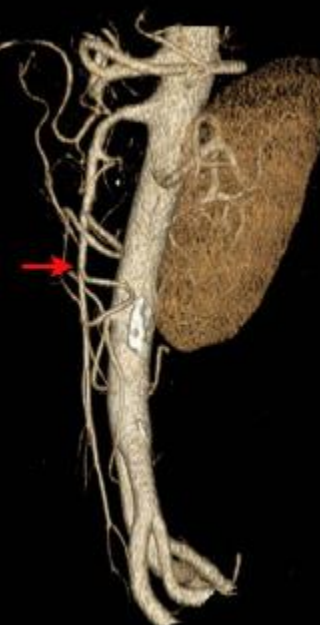
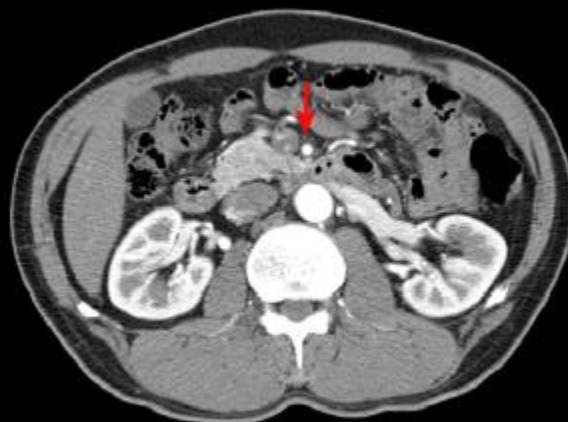
Isolated Intramural Hematoma of the SMA

Initial



4 mo



Take Home Messages

1. Diagnosing isolated dissection of the SMA is challenging because the incidence is rare. For accuracy of the diagnosis, it is important having high clinical suspicion.
2. The causes are unknown and the treatment options vary, and include surgery, endovascular treatment, or conservative management dependent on the extent of dissection and the associated complications.
3. IVUS and Chroma-flow image (Volcano) are very useful in the endovascular treatment for the SMA lesions.



Take Home Messages

4. It illustrates that transradial endovascular therapy for SMA occlusion is feasible and may have beneficial effects on hemostasis following the procedure.

The transradial approach may offer better coaxial alignment and strong back-up support of the guiding catheter for the SMA intervention.

Thus, transradial endovascular therapy may be a good option in the treatment of the SMA lesions.



Thank you for your attention

