

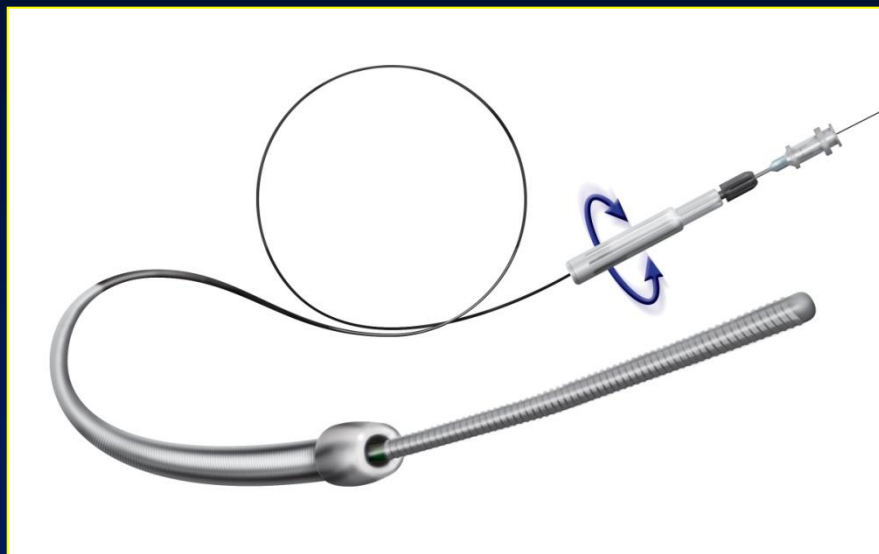
**New Antegrade Approach Device
using Dissection and Re-entry
The BridgePoint System**

Etsuo Tsuchikane, MD, PhD

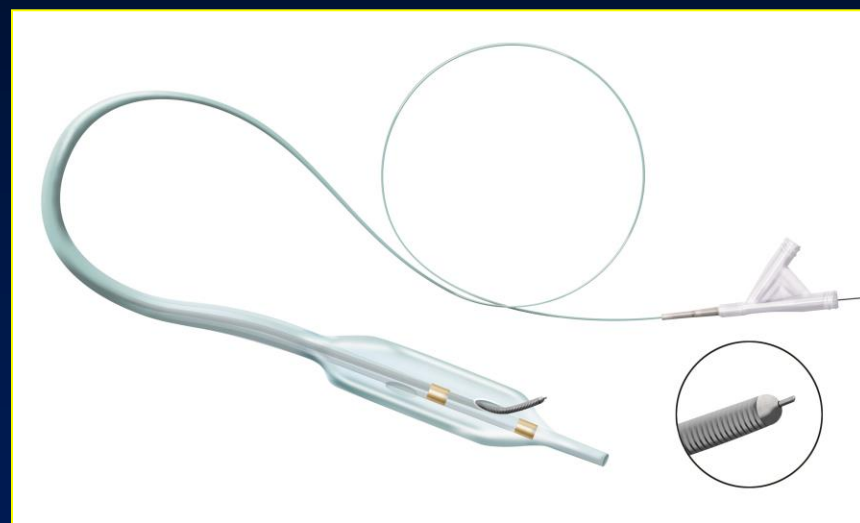
Toyohashi Heart Center, Japan

The BridgePoint System

CrossBoss Catheter



Stingray Re-Entry System



CrossBoss™ CATHETER

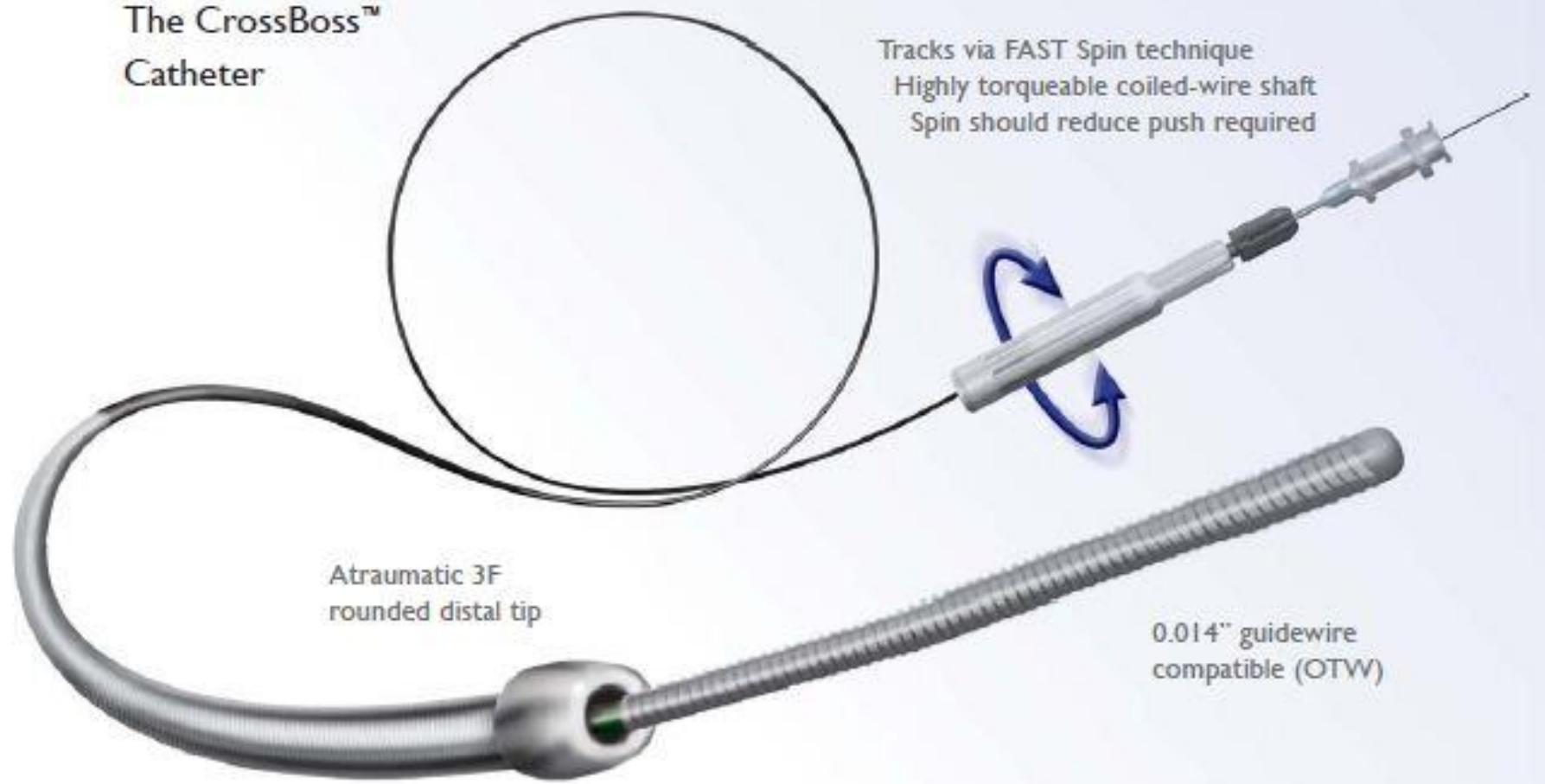
The CrossBoss™
Catheter

Tracks via FAST Spin technique
Highly torqueable coiled-wire shaft
Spin should reduce push required

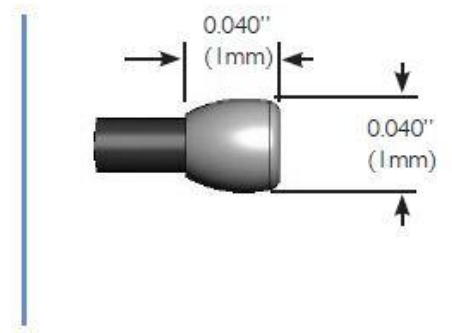
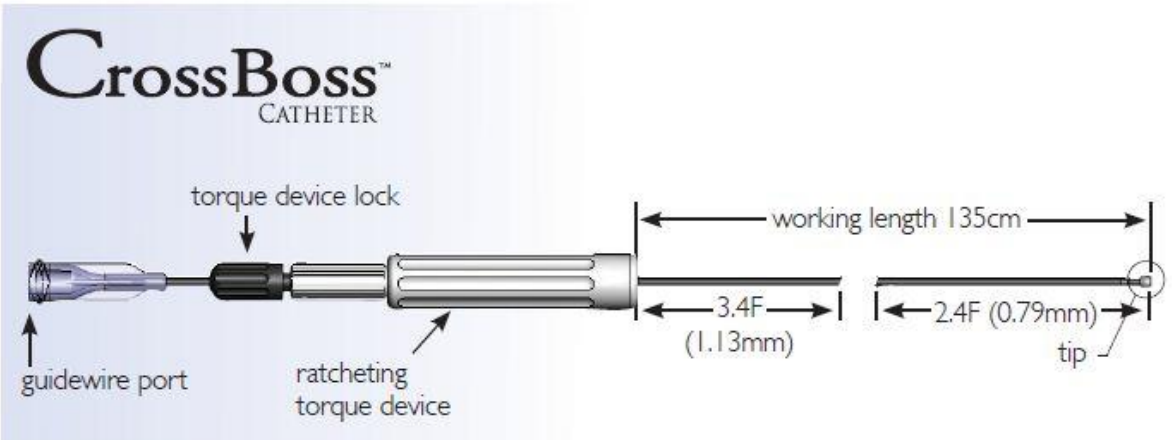
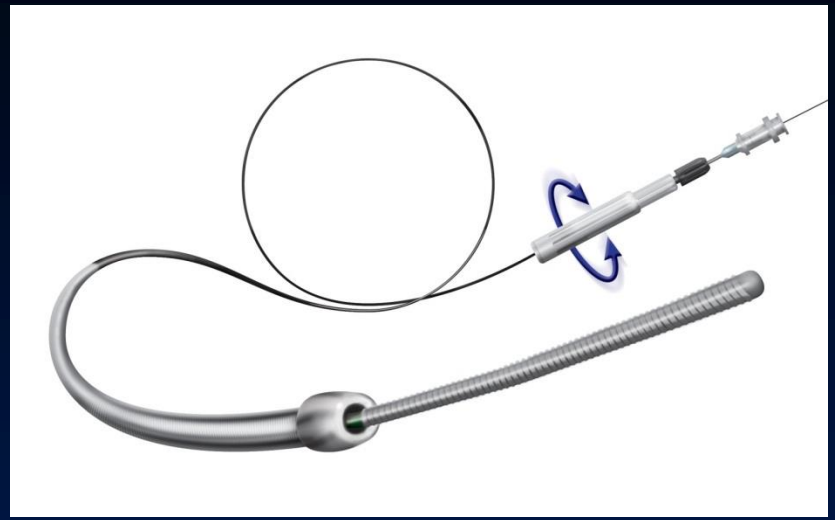

Atraumatic 3F
rounded distal tip

0.014" guidewire
compatible (OTW)

2.4F distal shaft diameter
6F guide catheter compatible

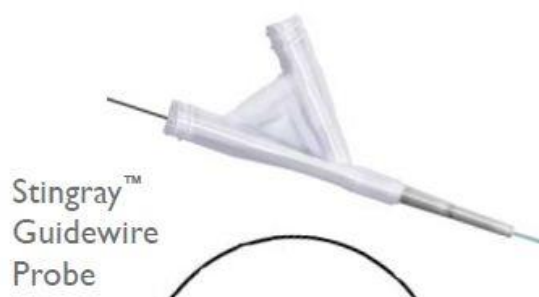

CrossBoss™ CATHETER



CATHETER Stingray™

The Stingray™ Catheter
& The Stingray™ Guidewire



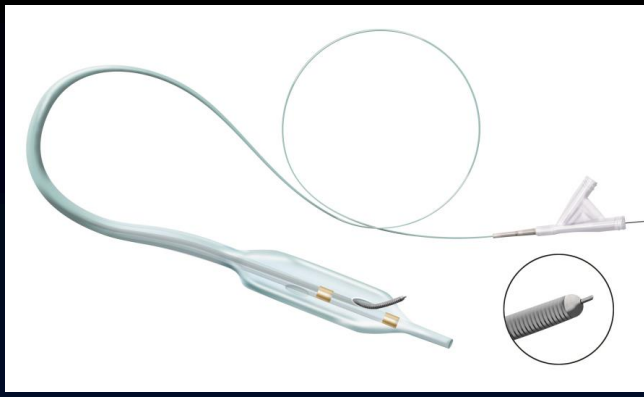
0.019" diameter (0.48mm)
lesion entry profile

Self-orienting
balloon has flat shape

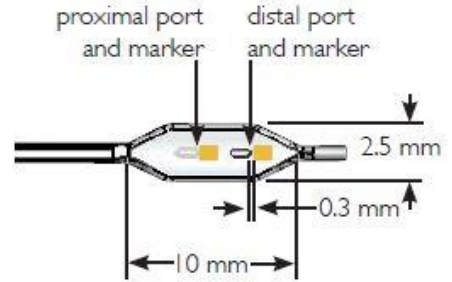
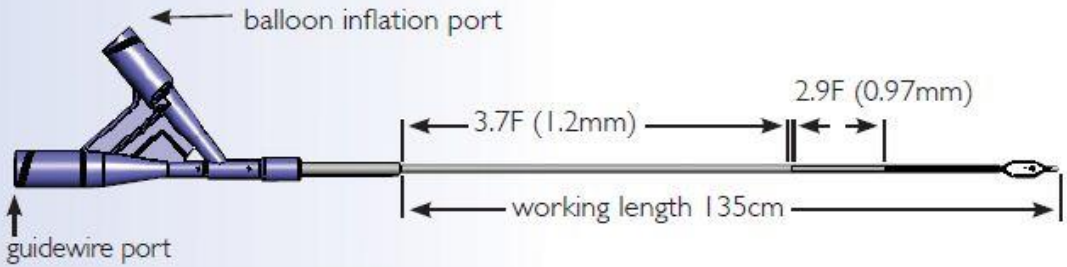
Compatibility:
0.014" guidewire
6F guide catheter

Offset exit ports for
Stingray™ Guidewire

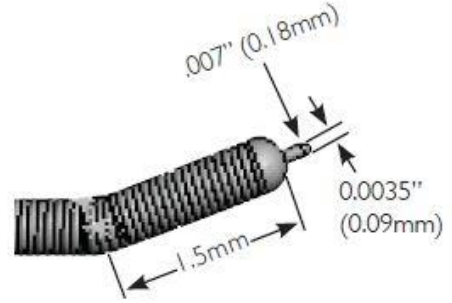
GUIDEWIRE Stingray™




Stingray™ CATHETER

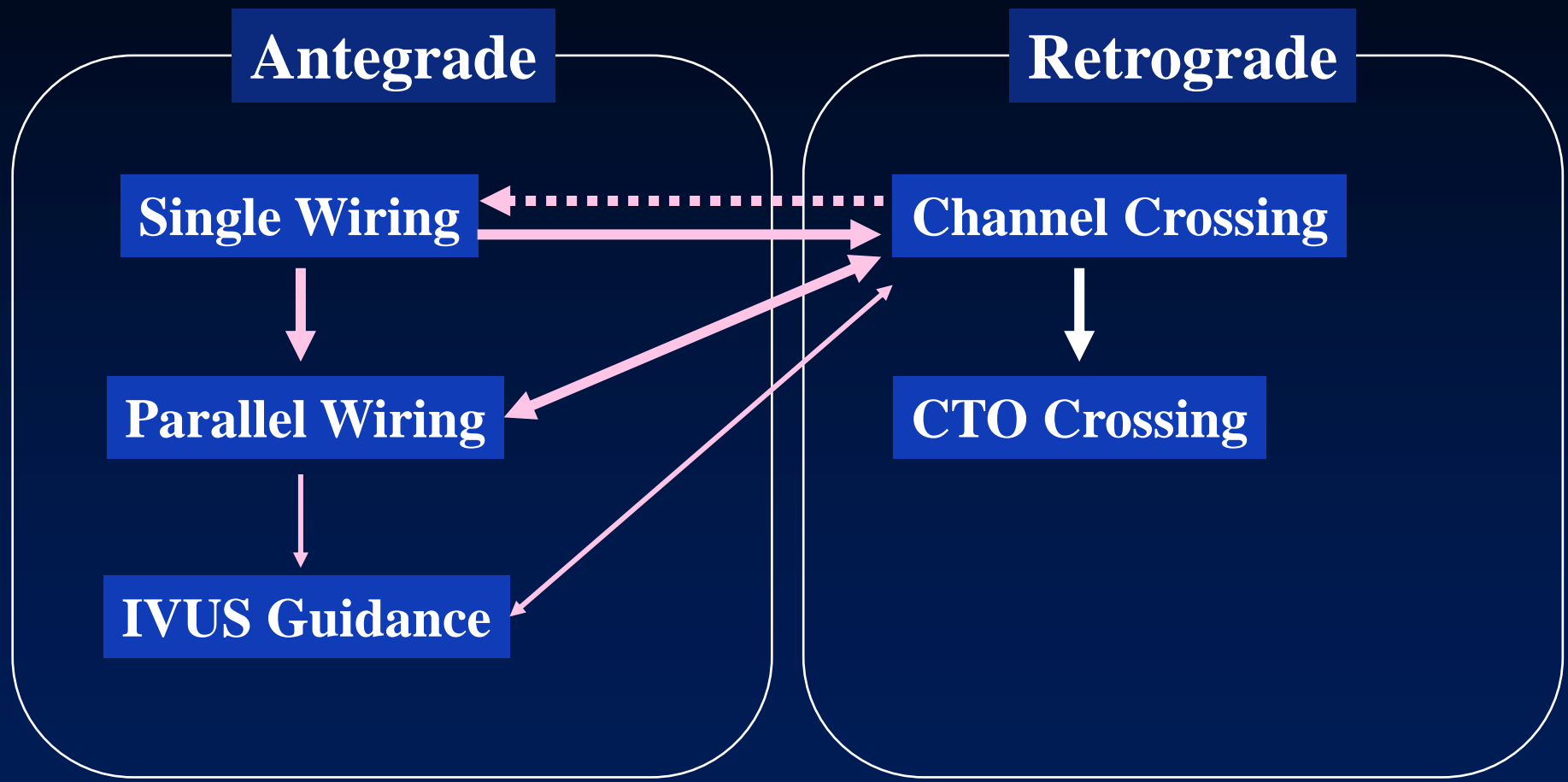


Stingray™ GUIDEWIRE



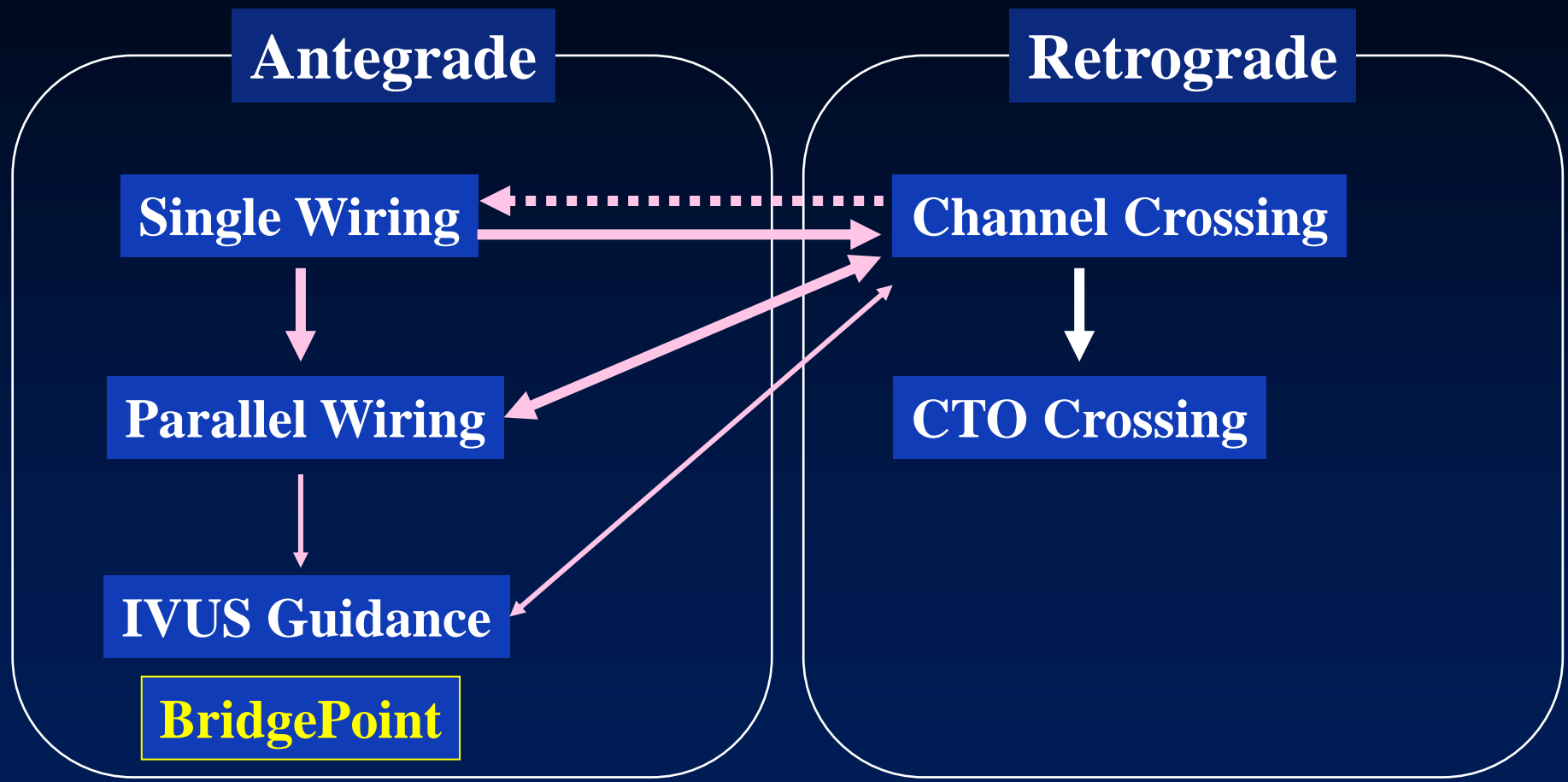


BridgePoint: When and Where?



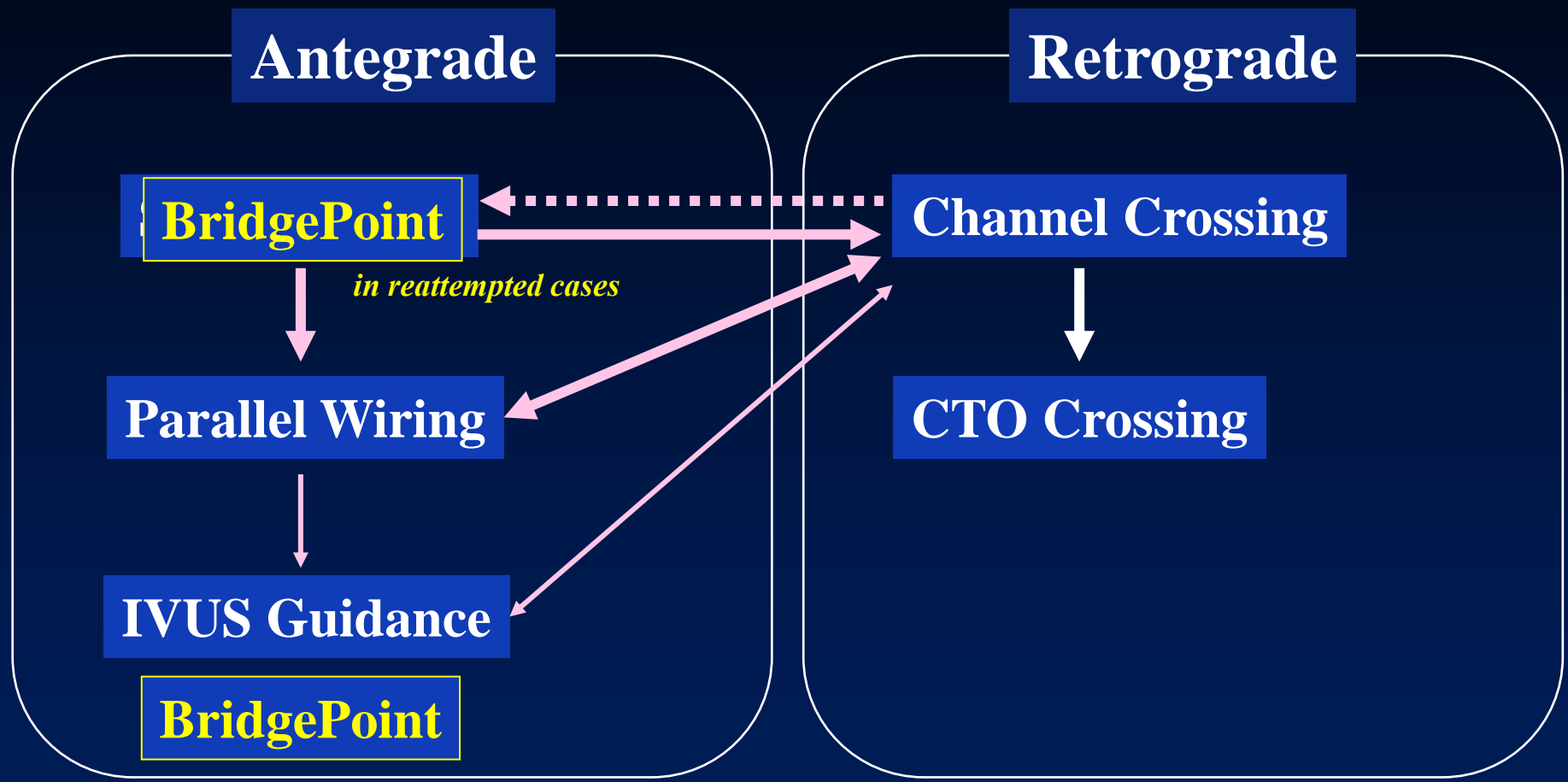
  **unsuccessful**

BridgePoint: When and Where?



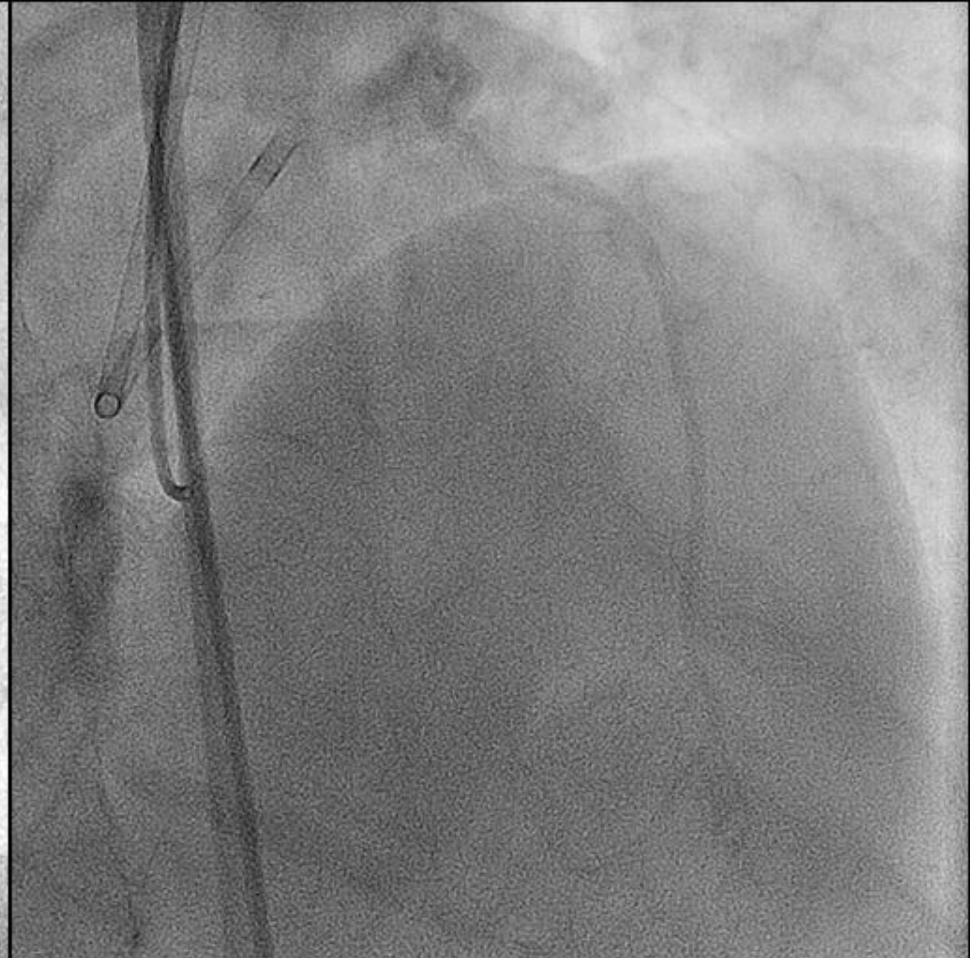
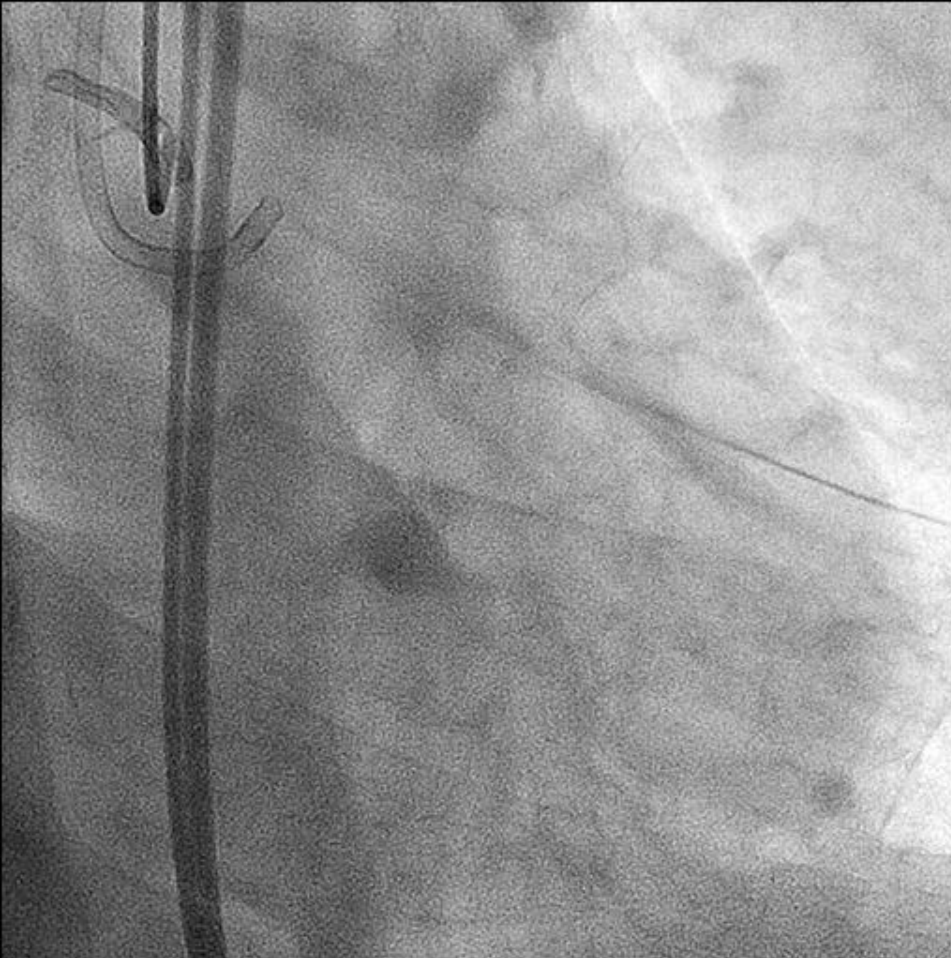
  **unsuccessful**

BridgePoint: When and Where?




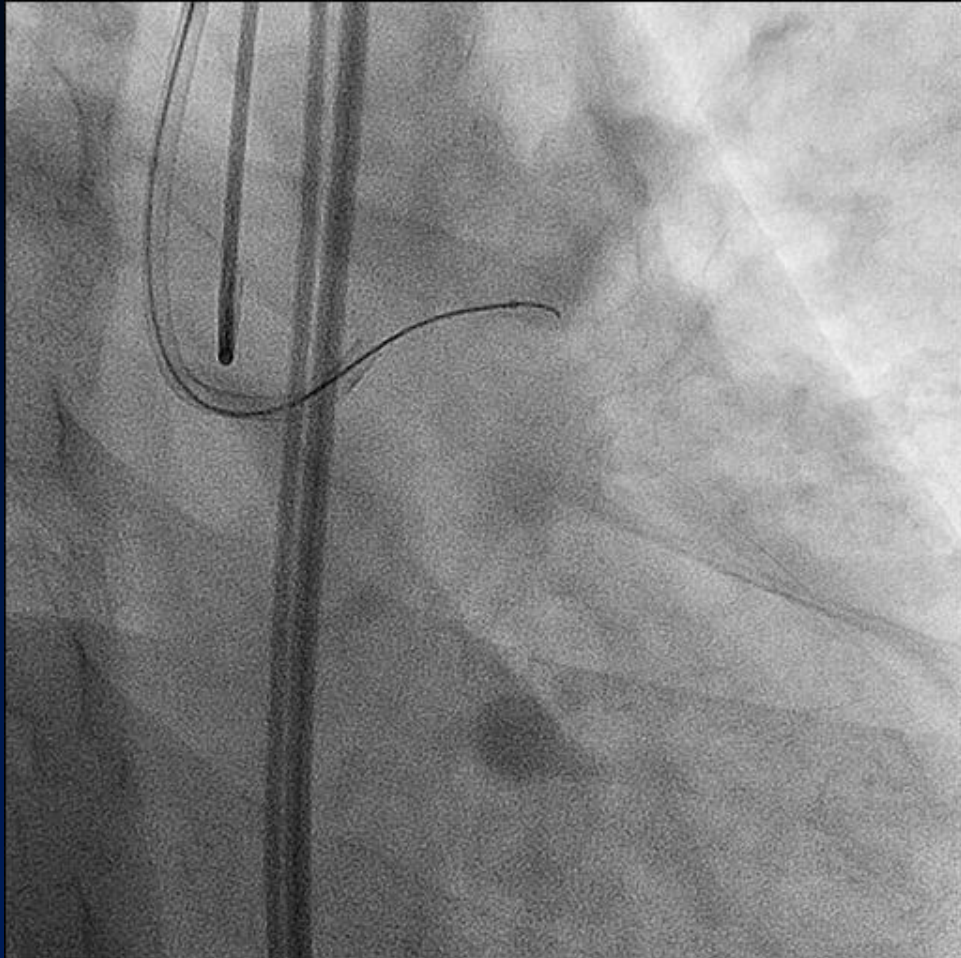
  **unsuccessful**

Case: Primary Use (Reattempt)



2008.9.19


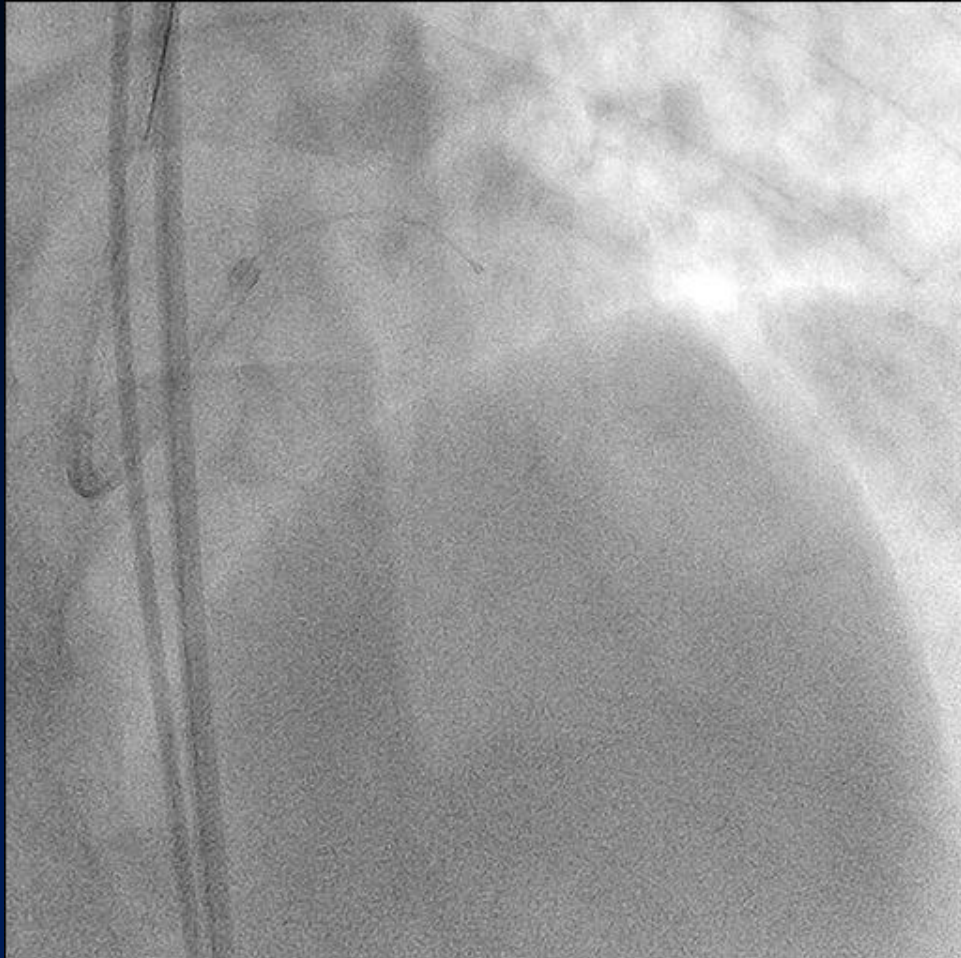
1st Step: CrossBoss



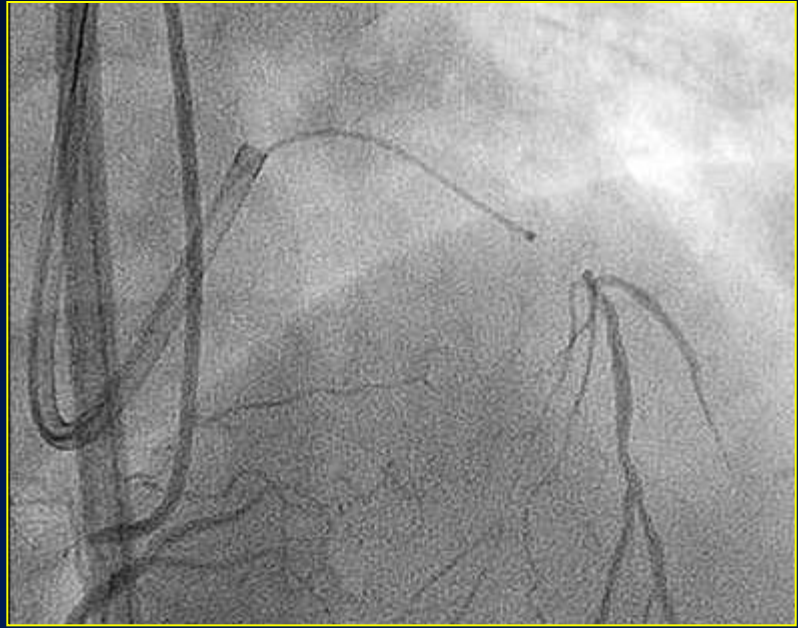
CrossBoss

Advance of CrossBoss

1st Step: CrossBoss




CrossBoss

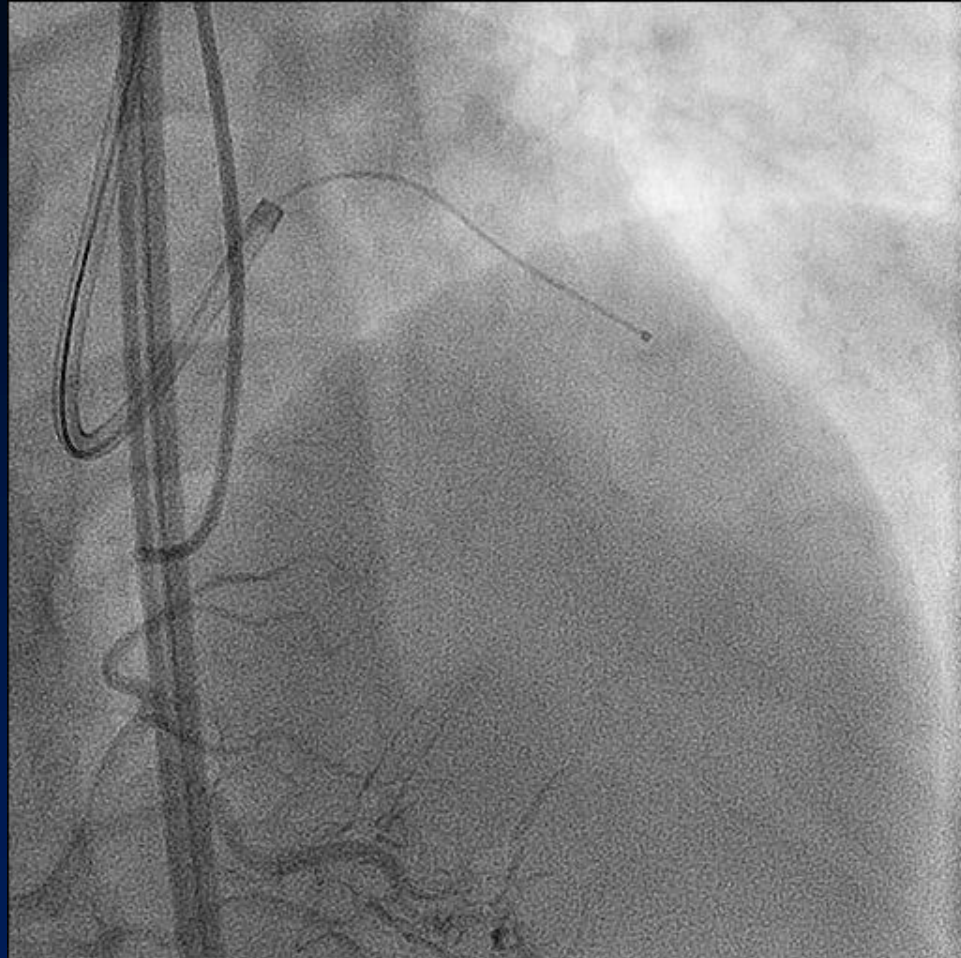


Rotation of CrossBoss

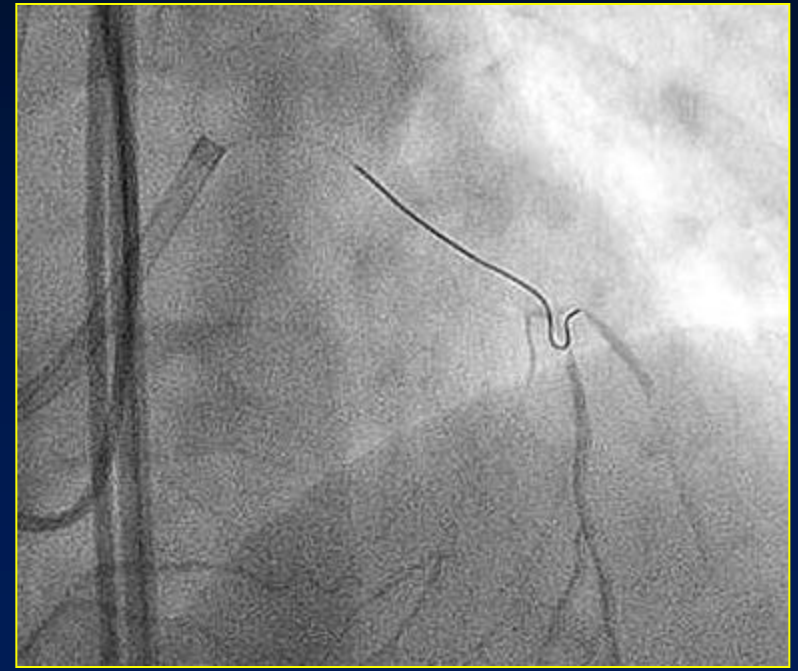
1st Step: CrossBoss



CrossBoss

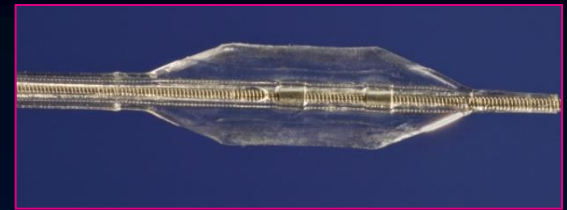


Rotation of CrossBoss

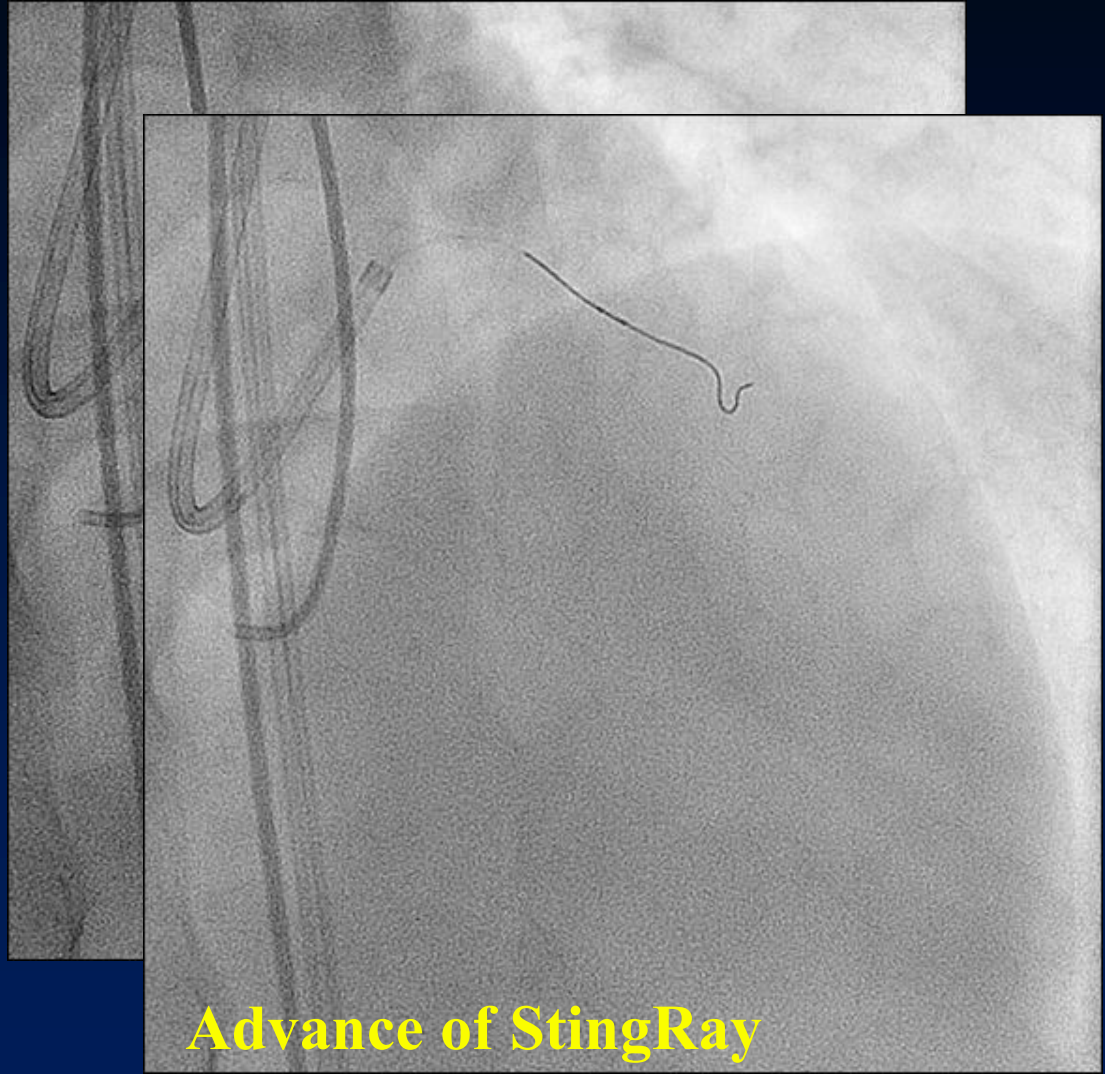


After removal of CrossBoss

2nd Step: StingRay

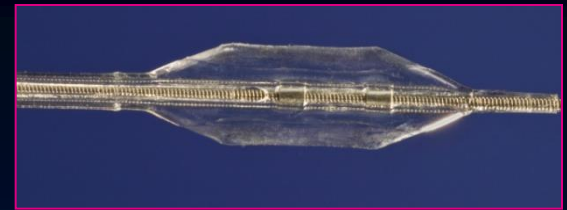


StingRay

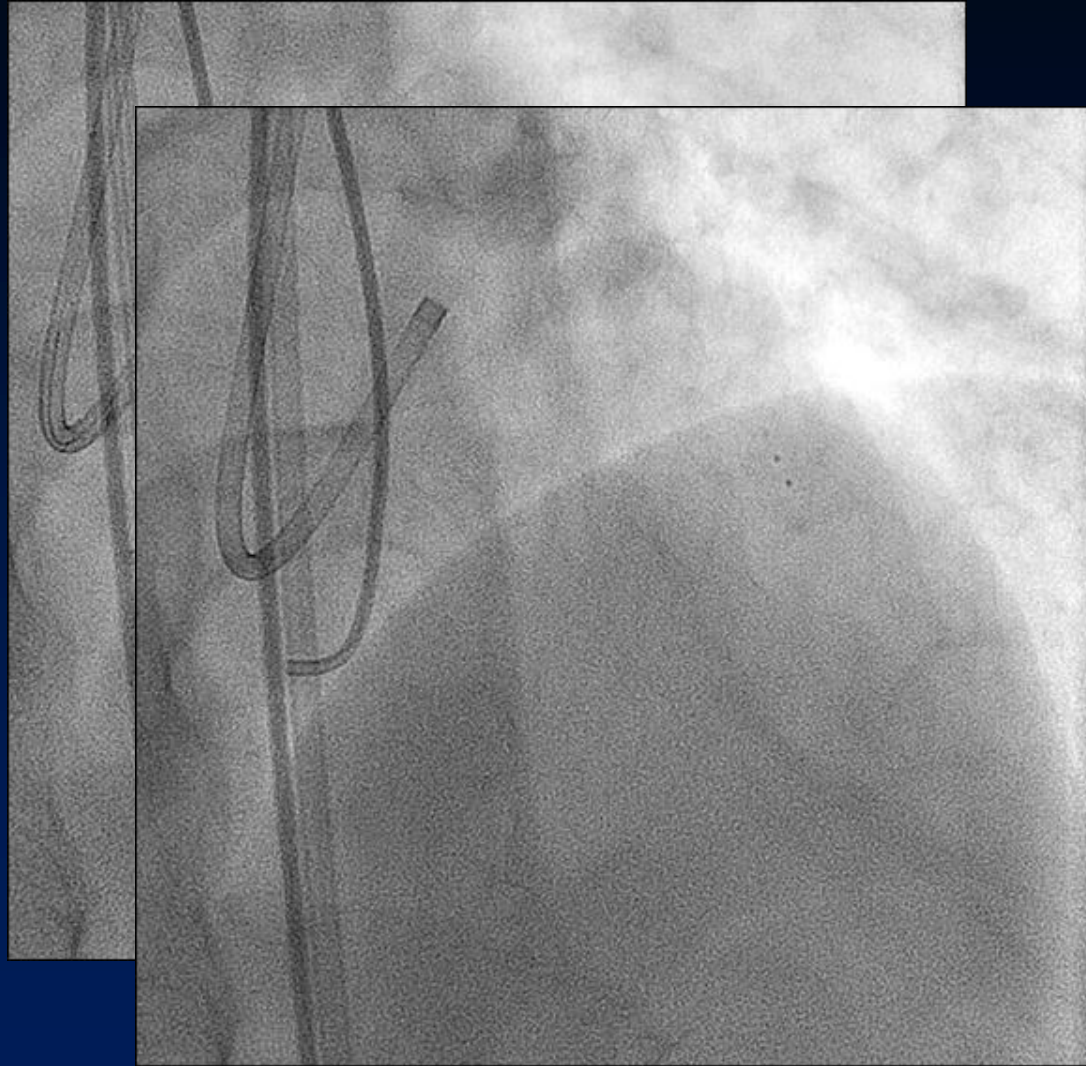


Advance of StingRay

2nd Step: StingRay


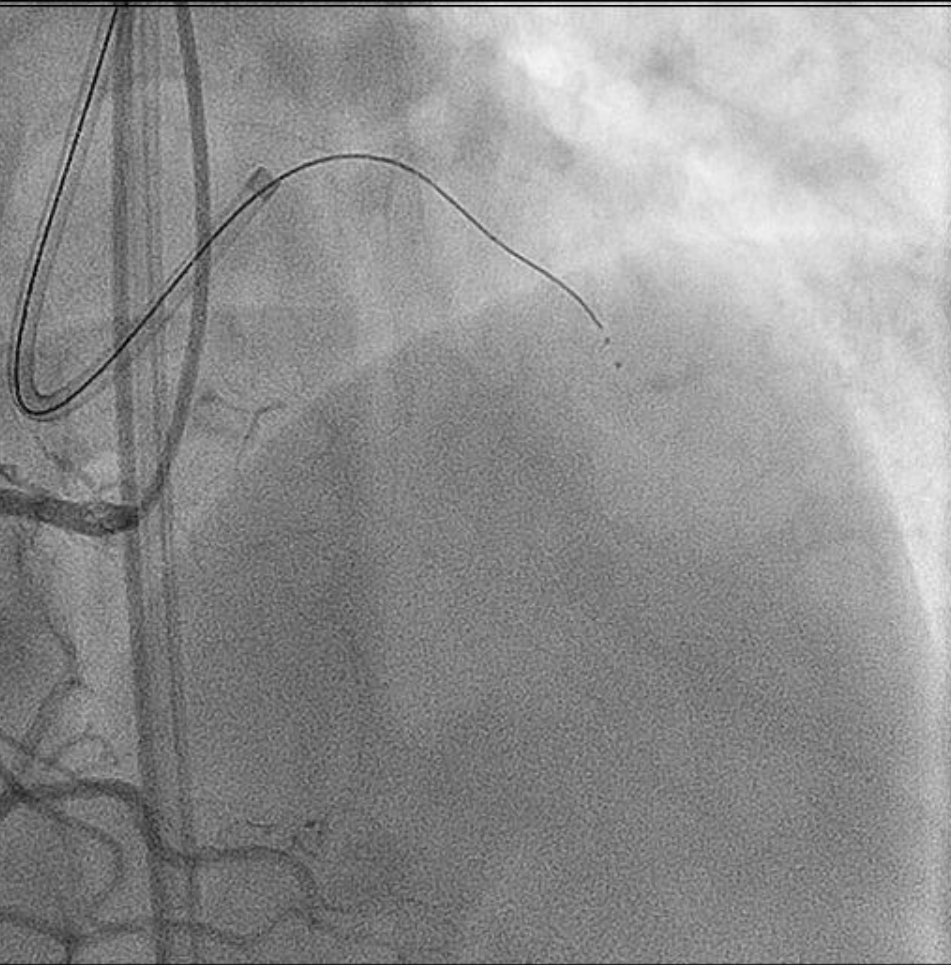


StingRay

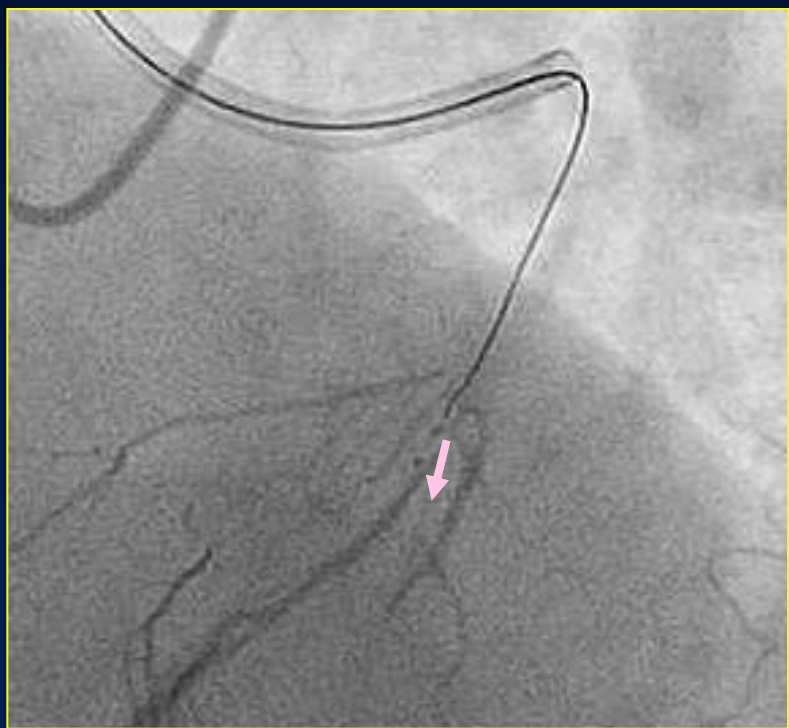


Inflation of StingRay

3rd Step: Reentry Wire


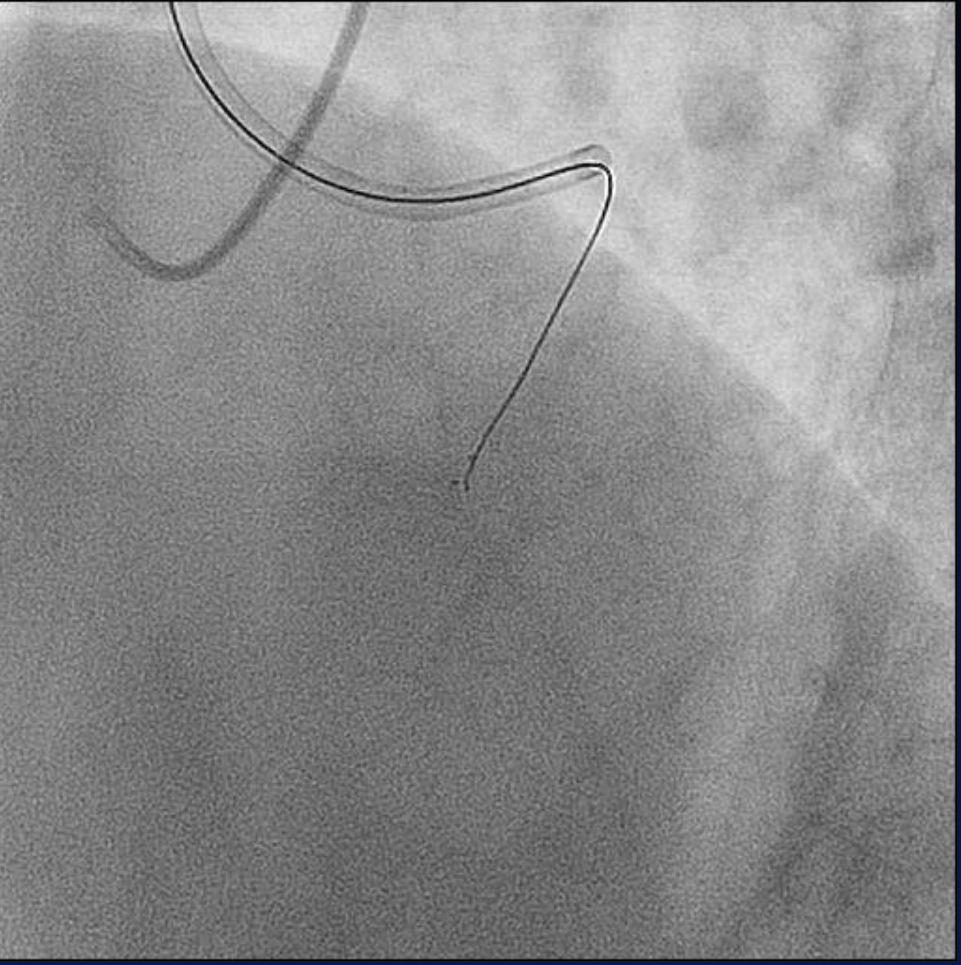


Reentry Wire

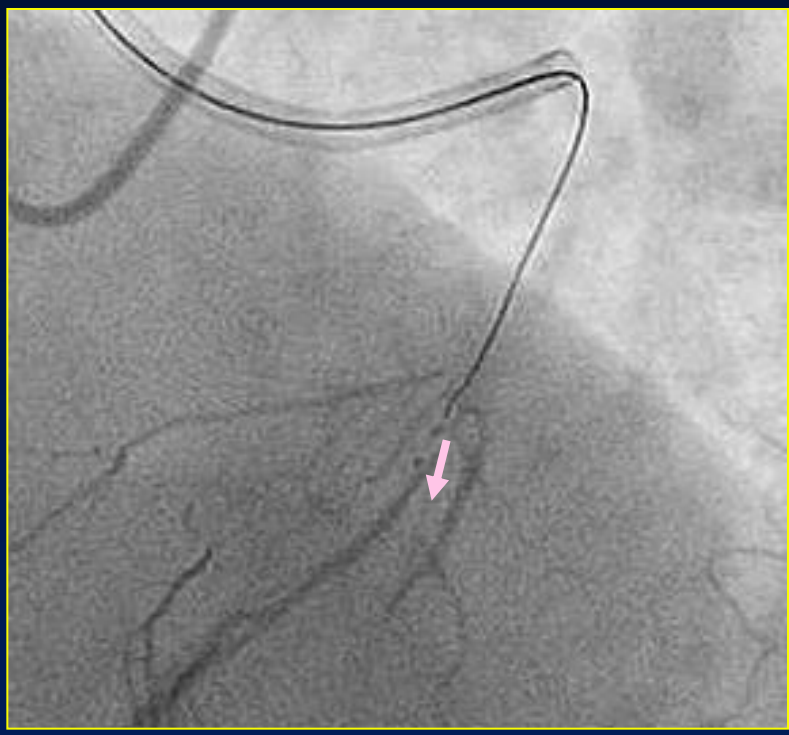


Checking of puncture direction

3rd Step: Reentry Wire

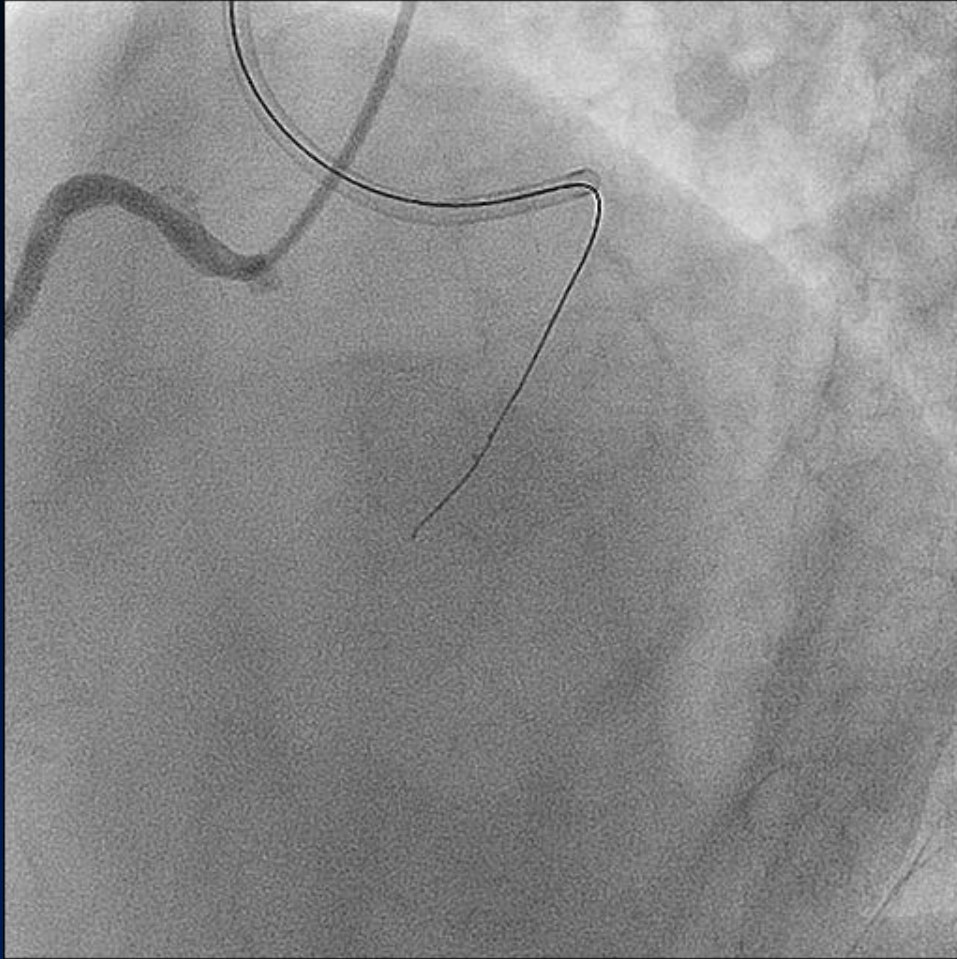


Reentry Wire




Wire comes out from proximal port

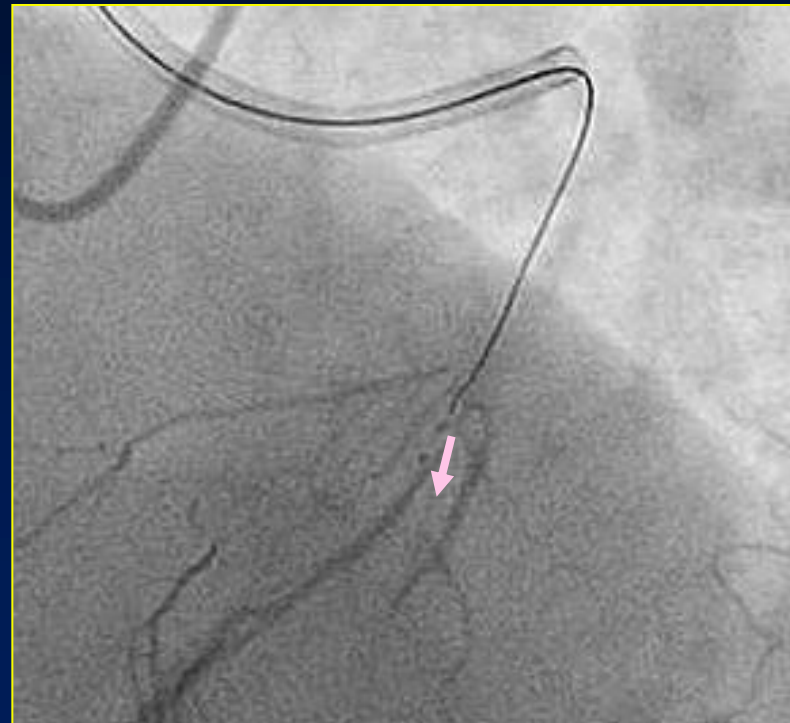3rd Step: Reentry Wire

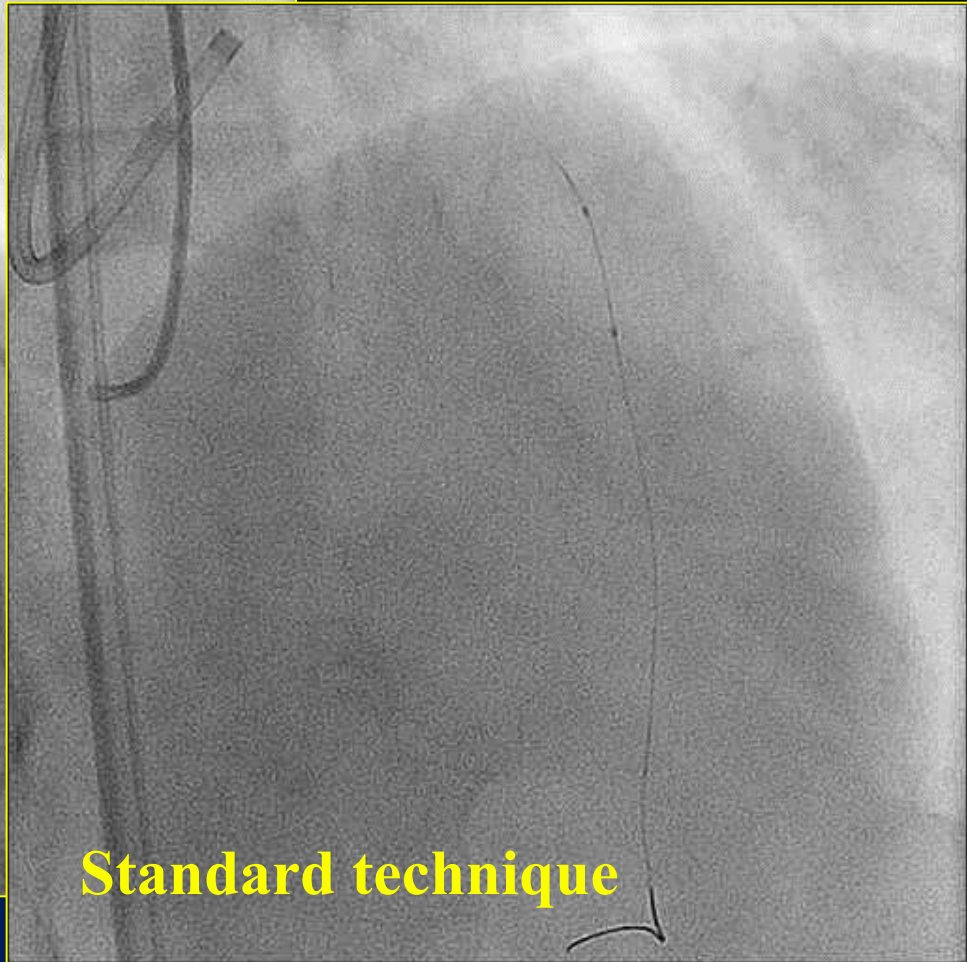
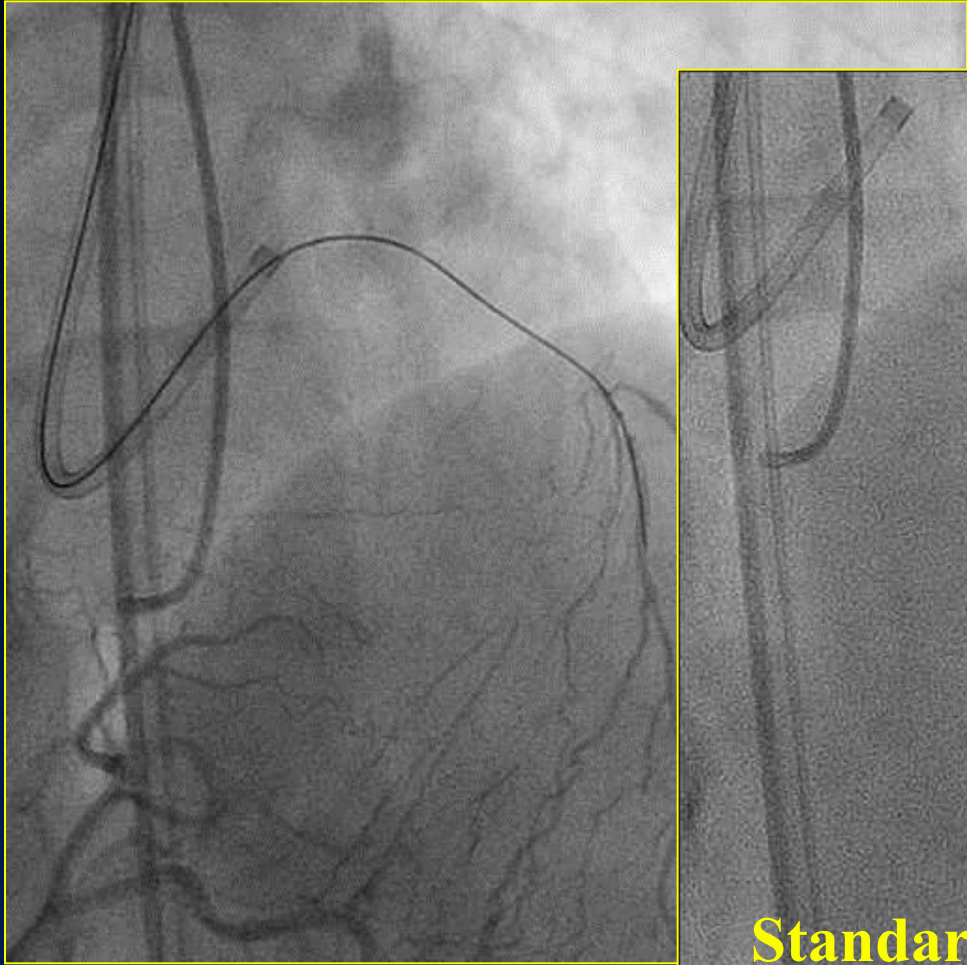


Successful puncture



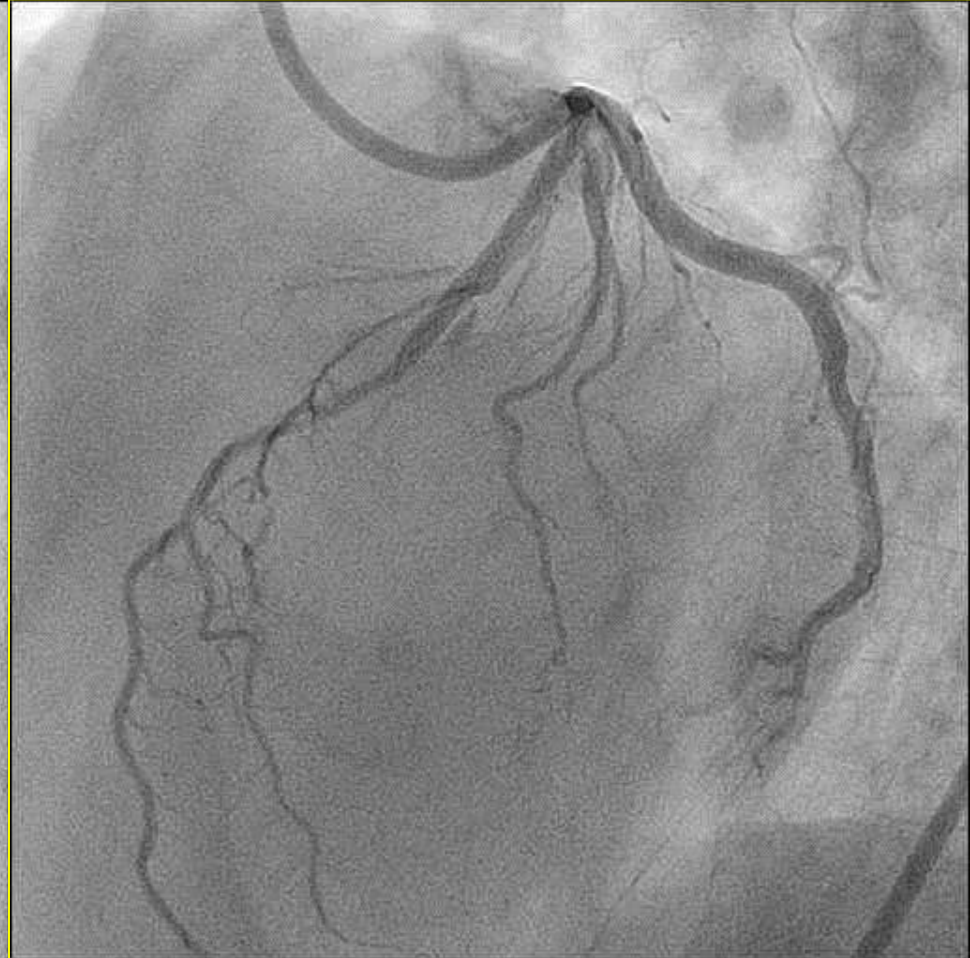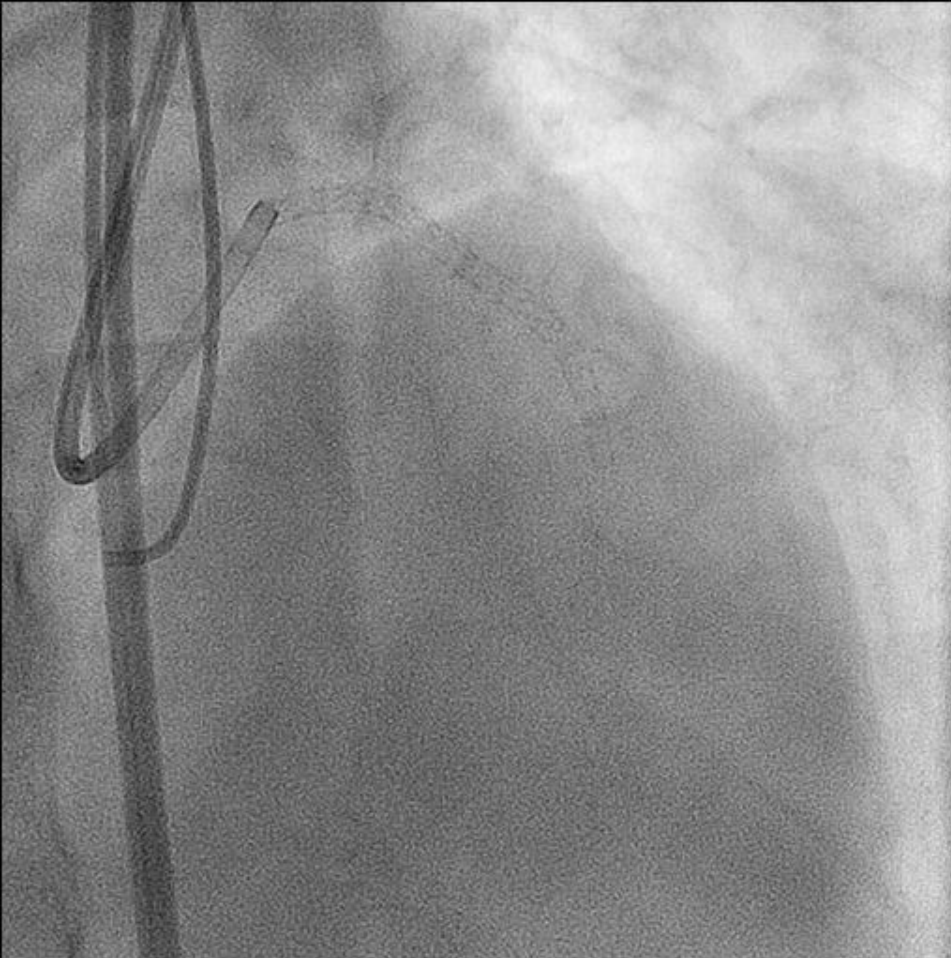
Reentry Wire



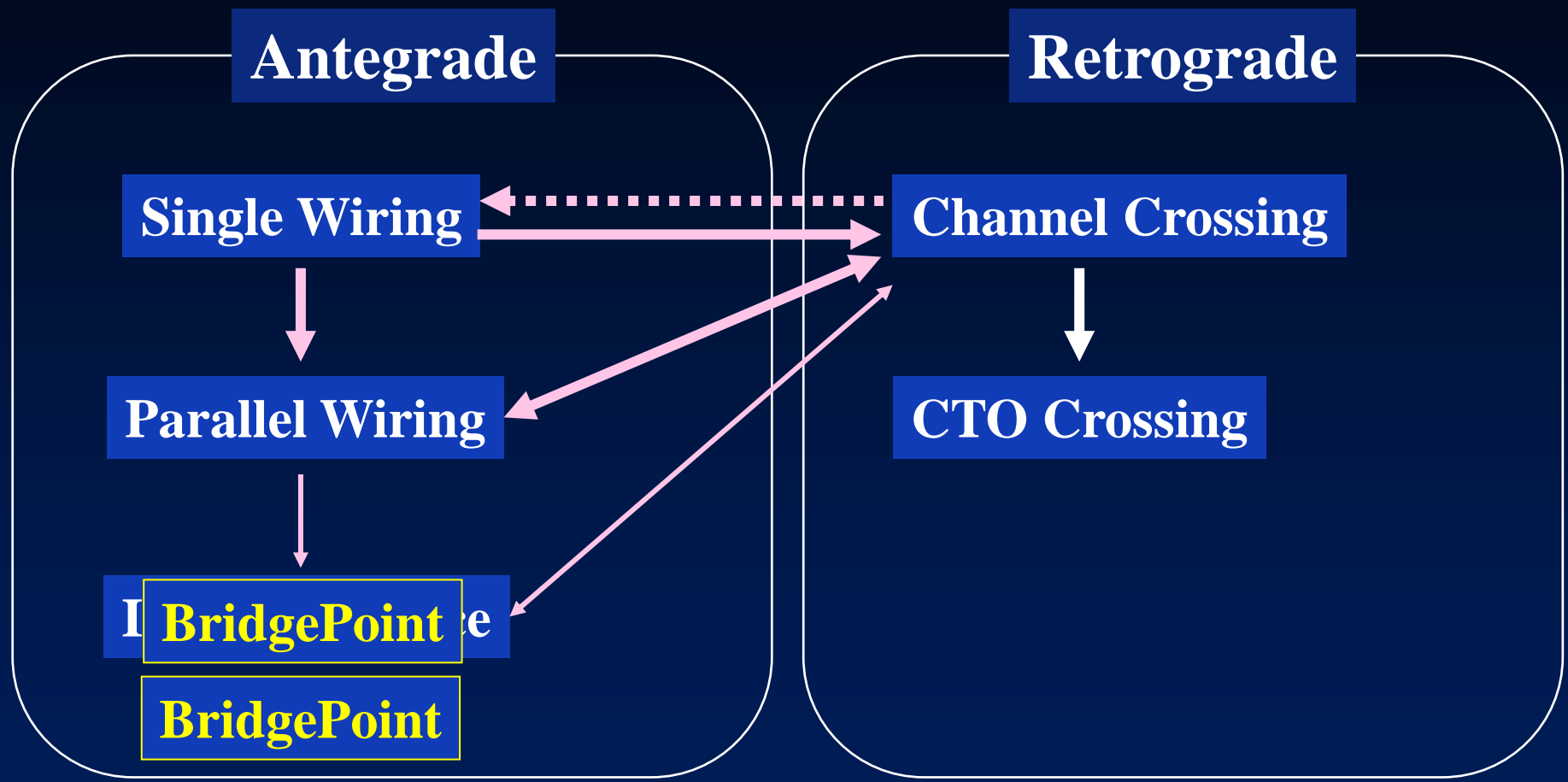


Standard technique

Final Angiogram

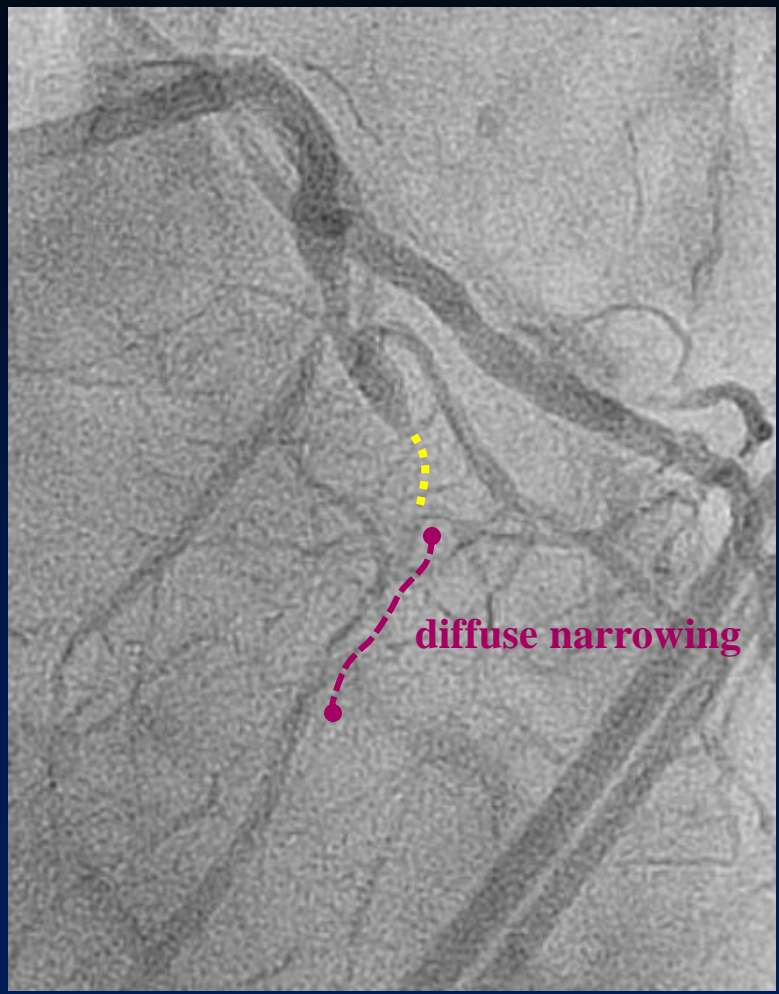
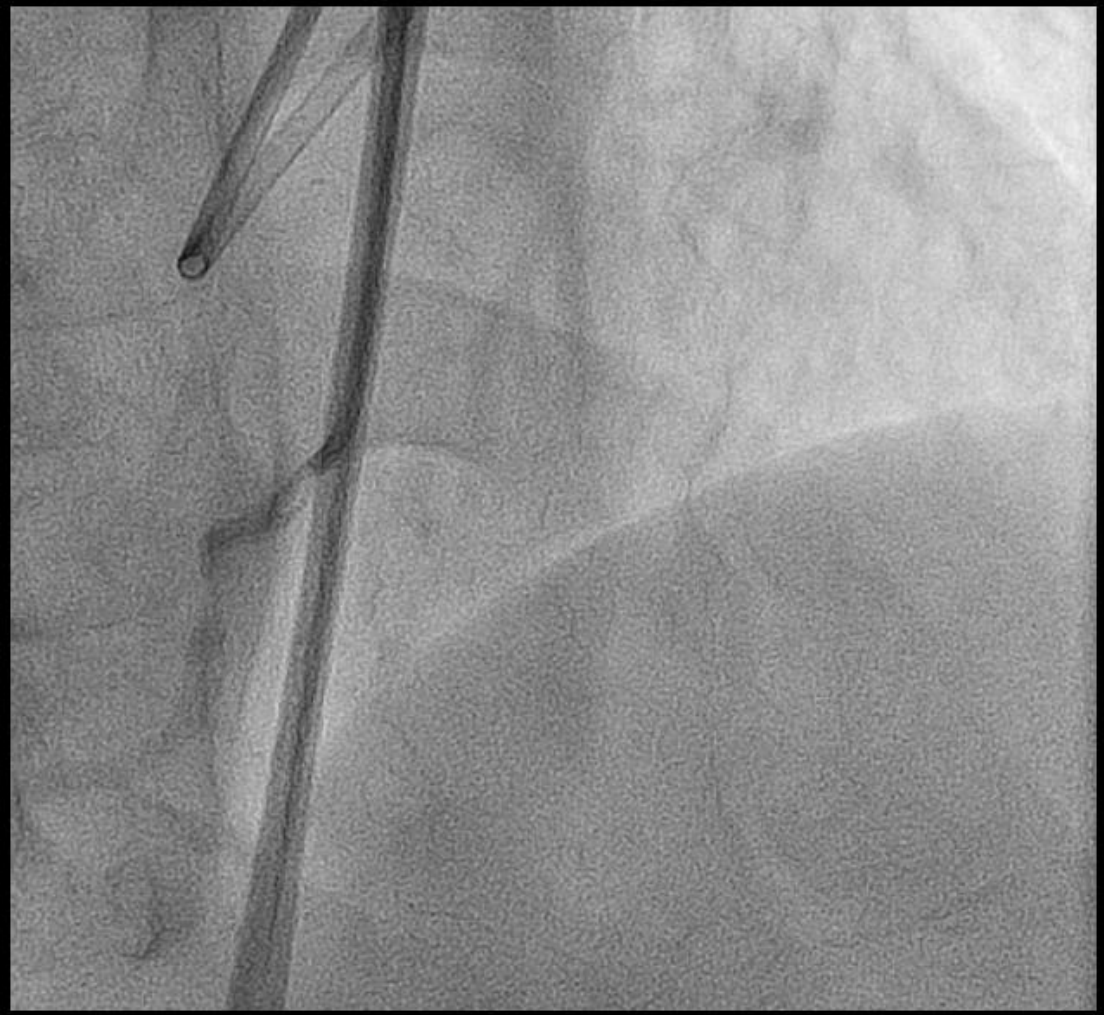

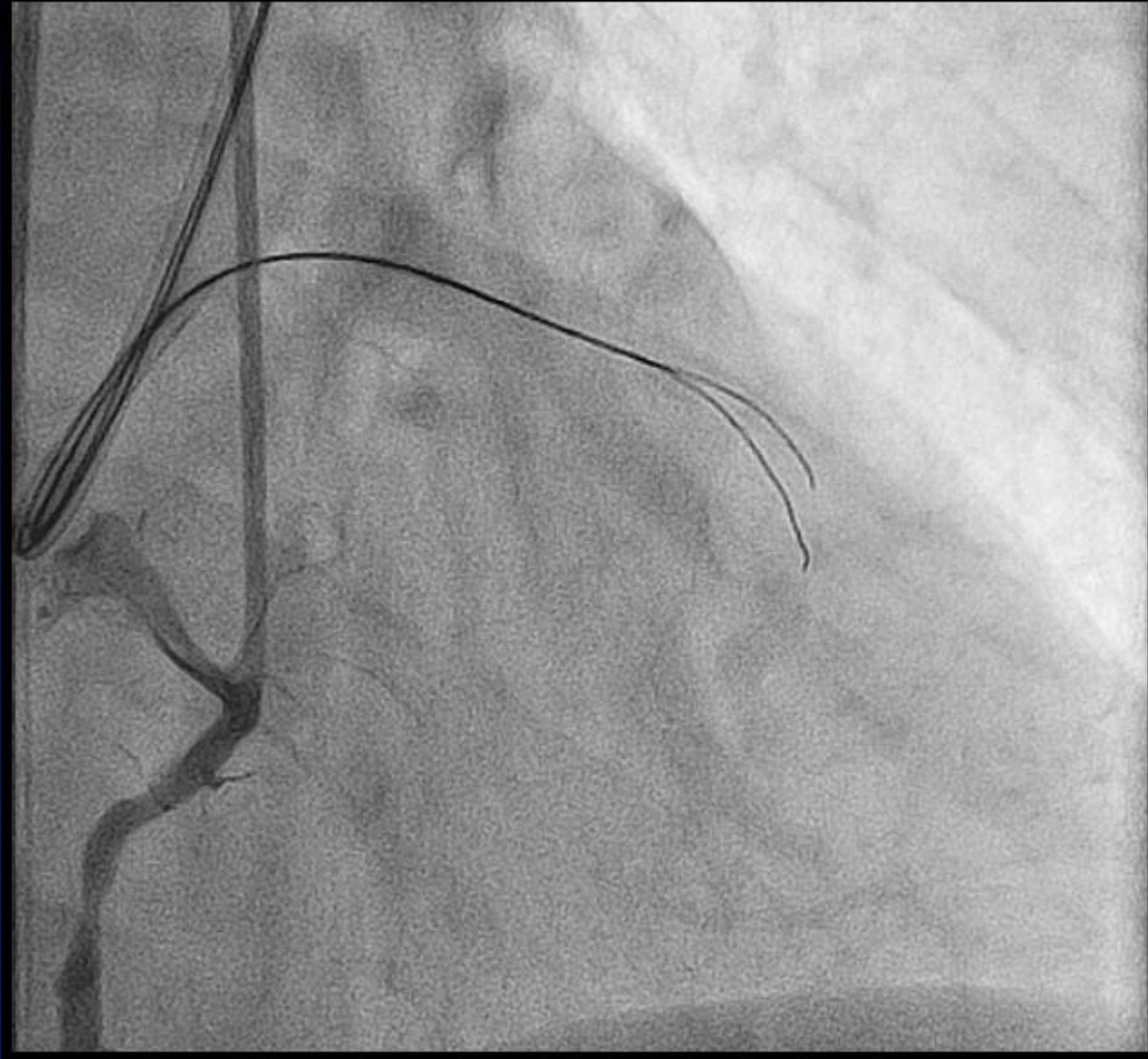
BridgePoint: When and Where?



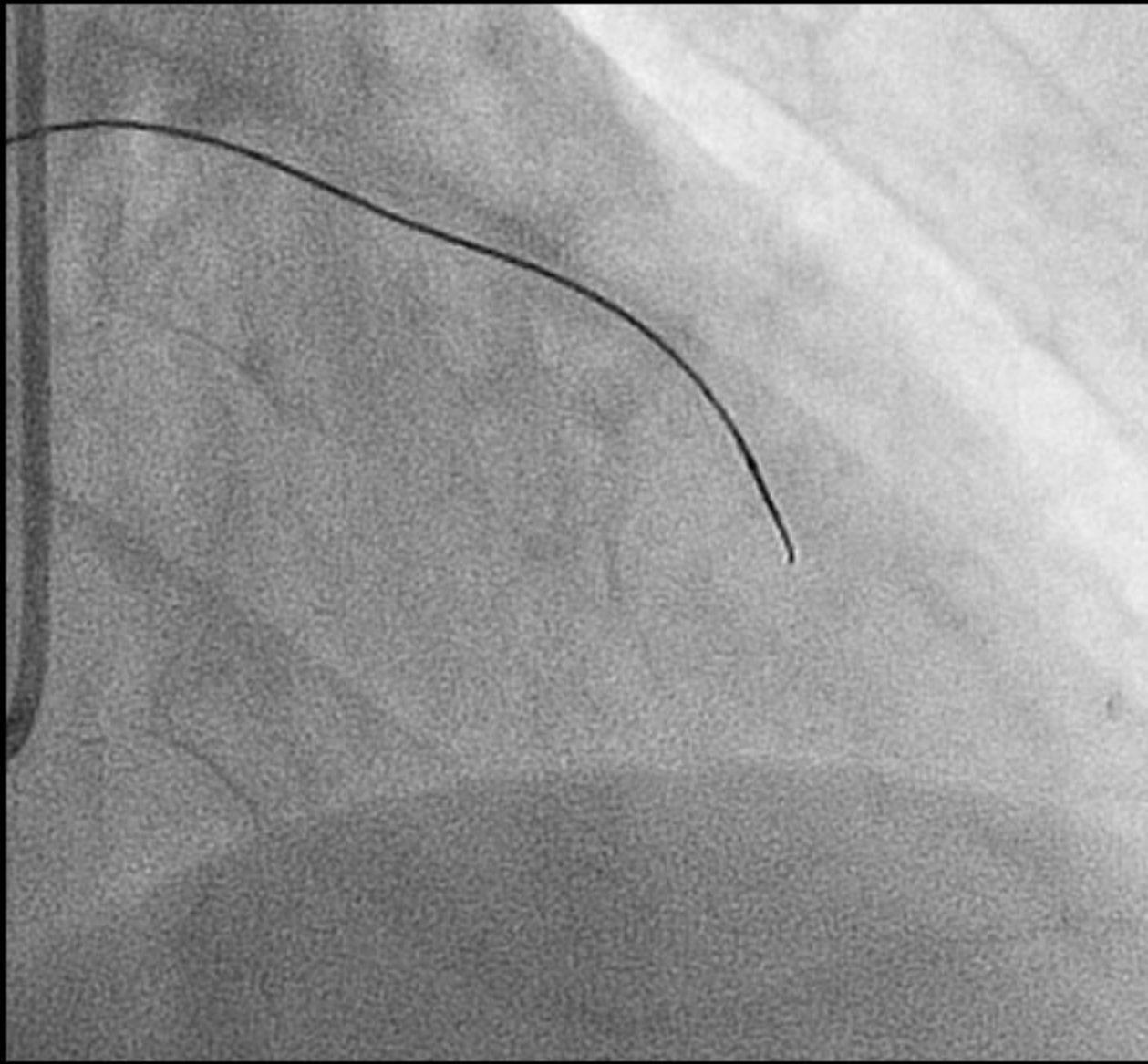
  **unsuccessful**

1st Attempt for LAD-CTO: Bail-out Use

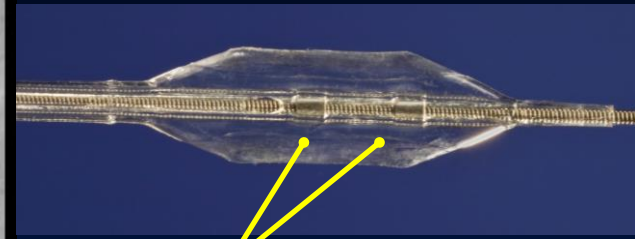
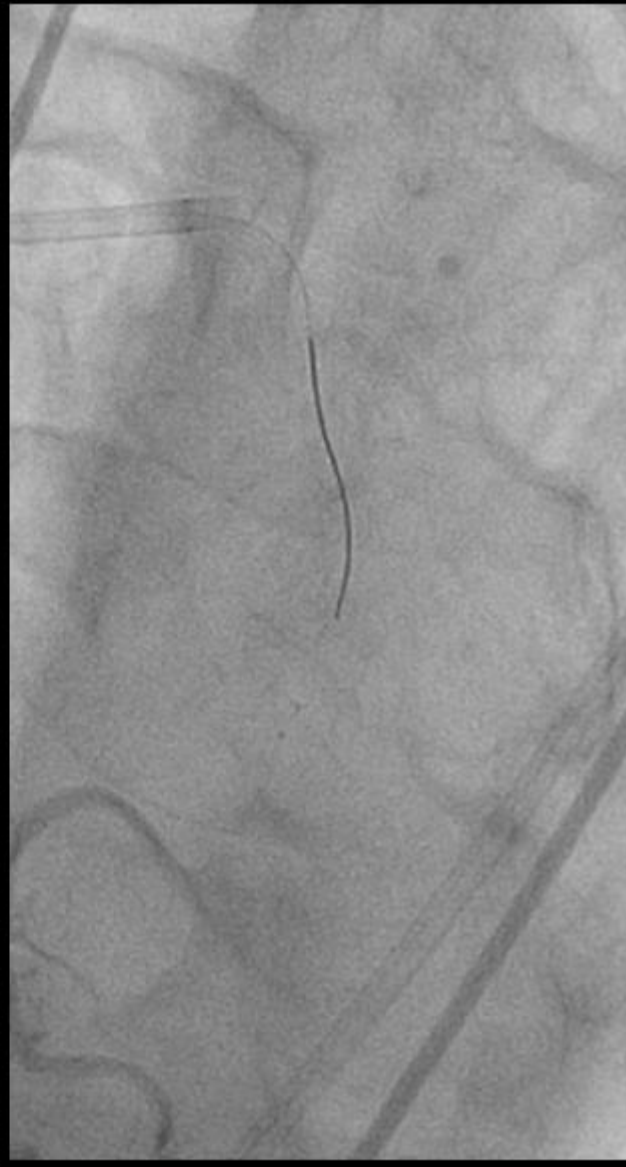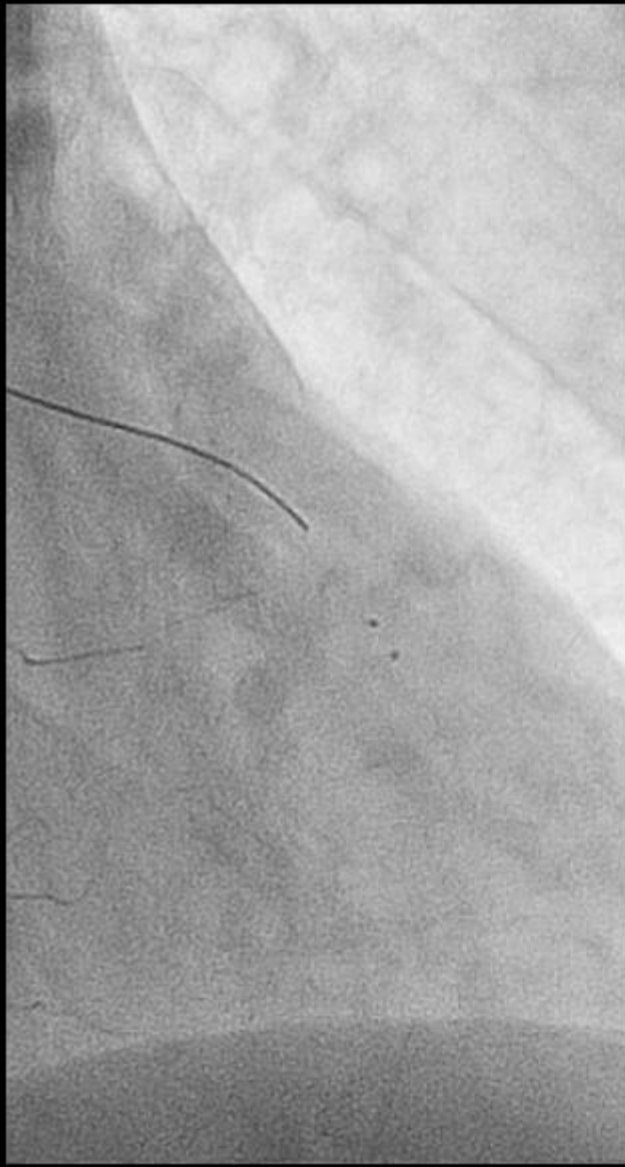




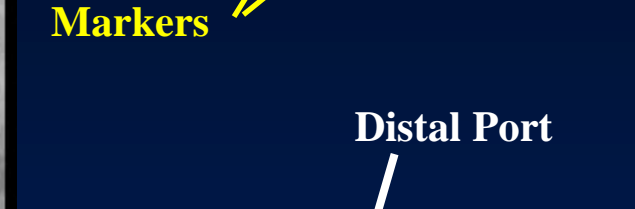Failed parallel wiring



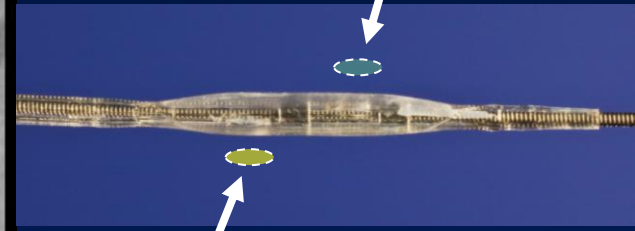
Antegrade Corsair



Markers

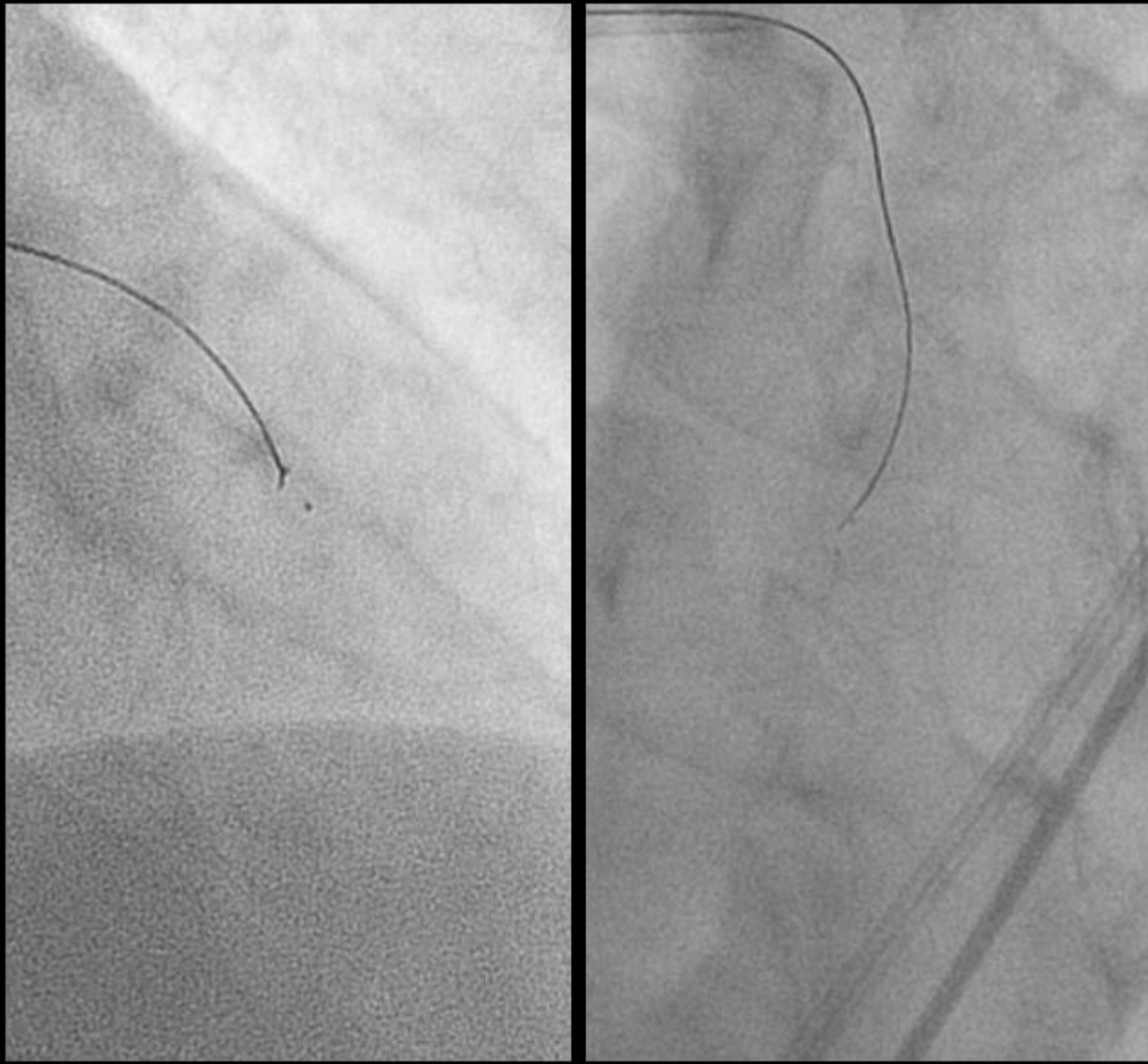


Distal Port




Proximal Port

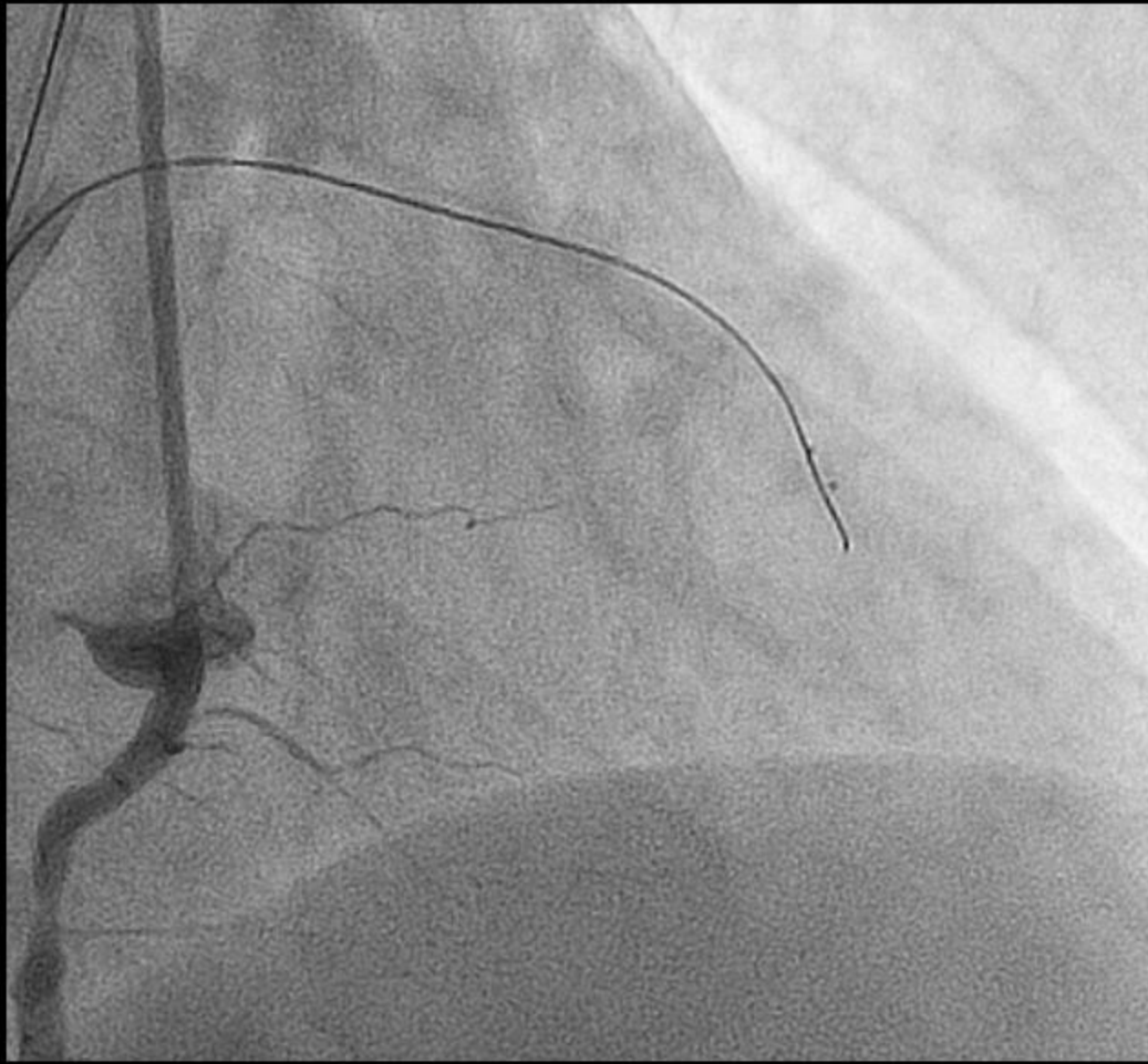
Stingray balloon



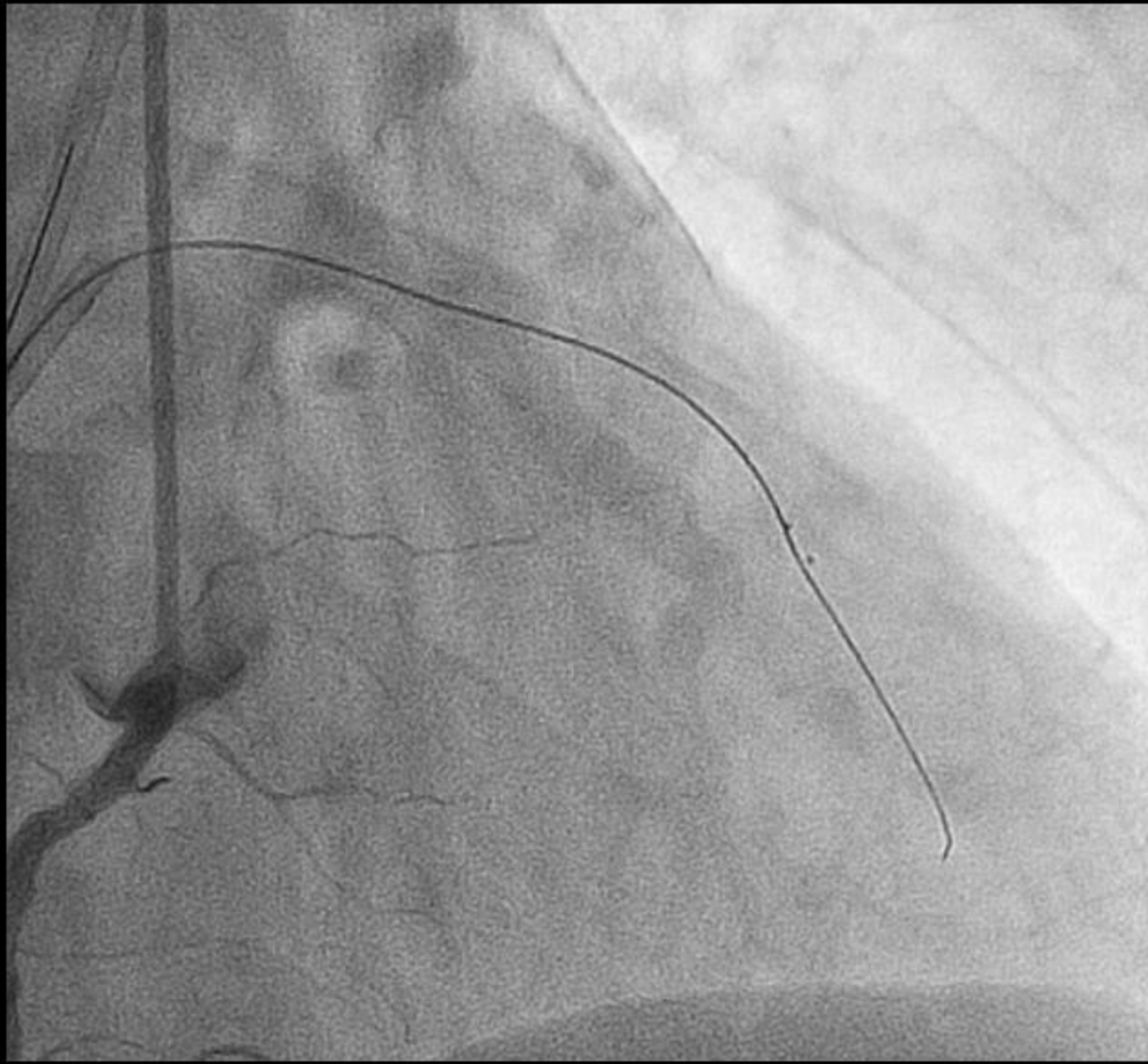
Re-entry wire



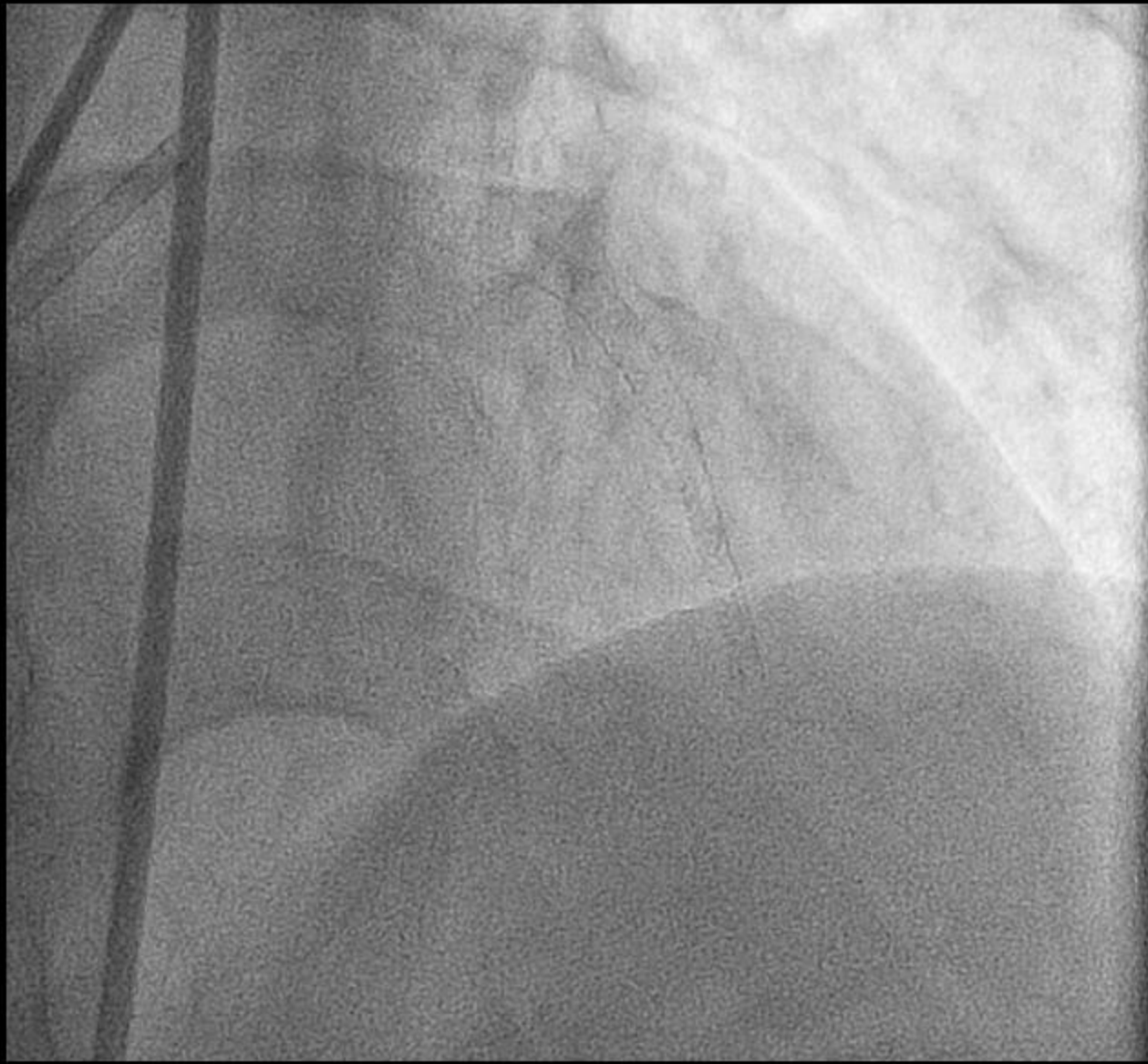
Proximal Port



Successful puncture, however the wire could not be advanced.



Successful crossing with Fielder XT

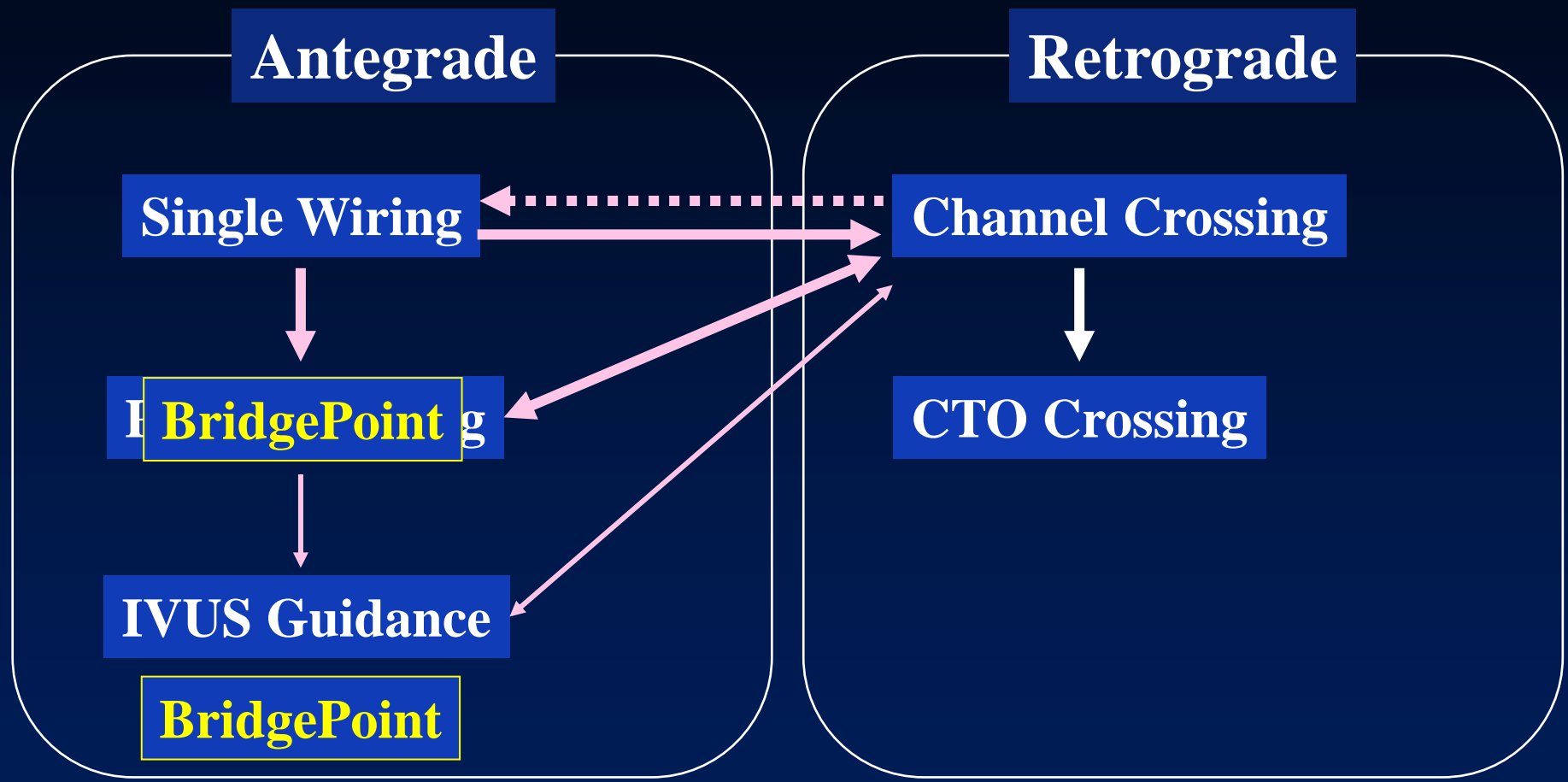


Final Angiogram

Tips and Tricks of Bridge Point System

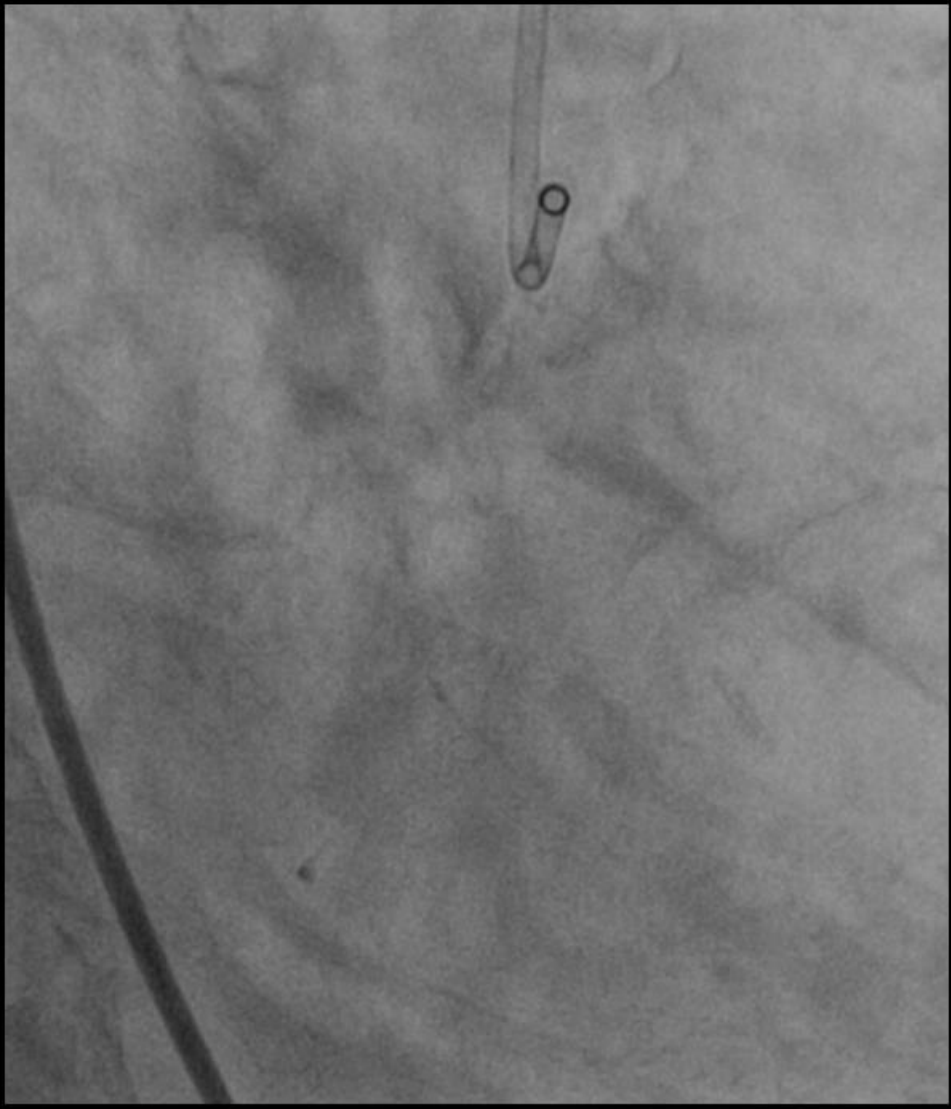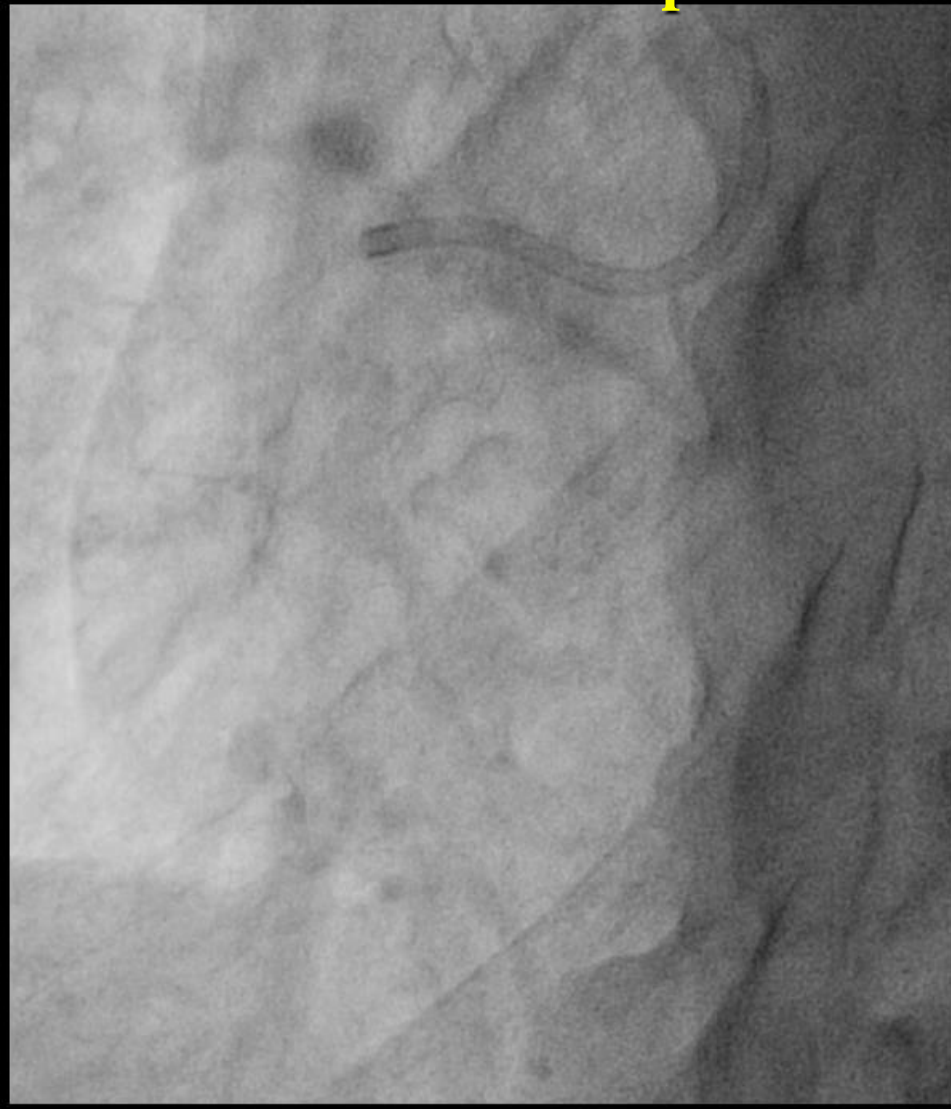- ◆ Wire change after puncturing

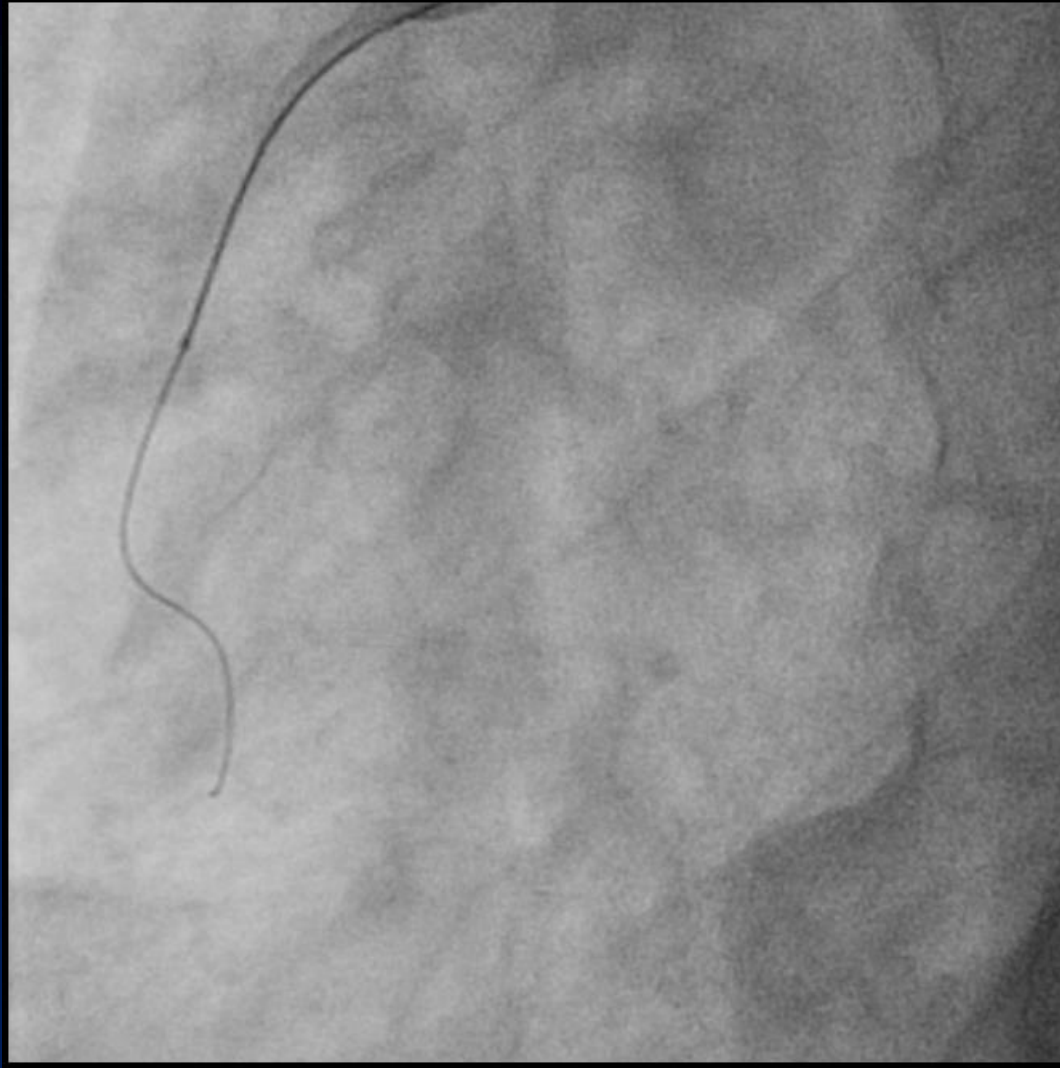
BridgePoint: When and Where?



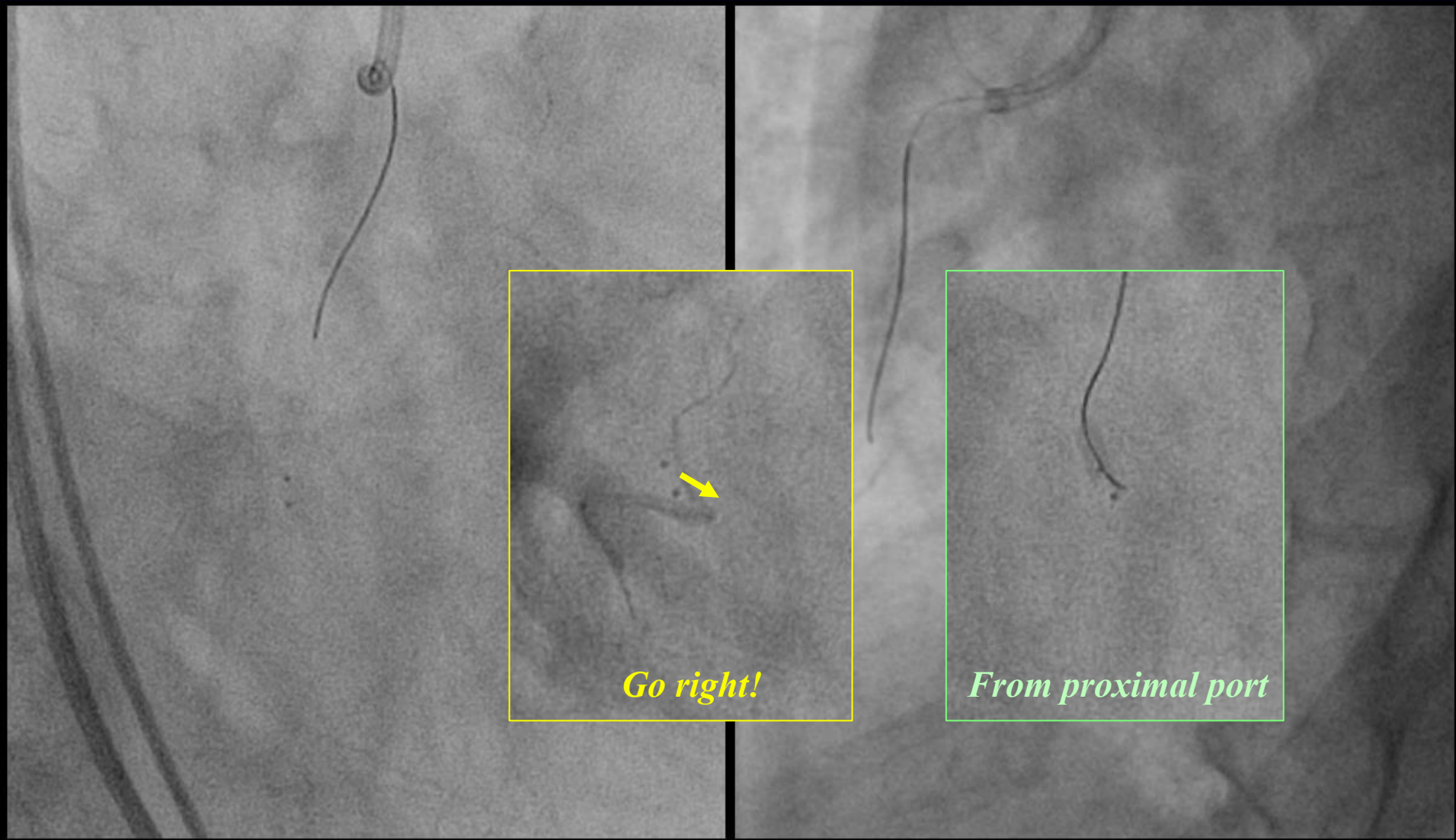
  **unsuccessful**

1st Attempt for RCA-CTO: Bail-out Use

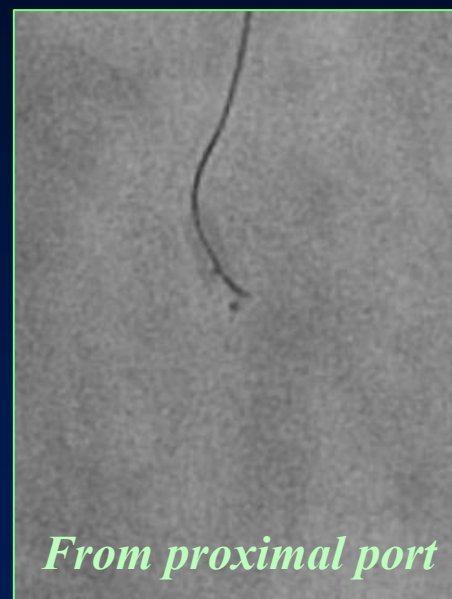
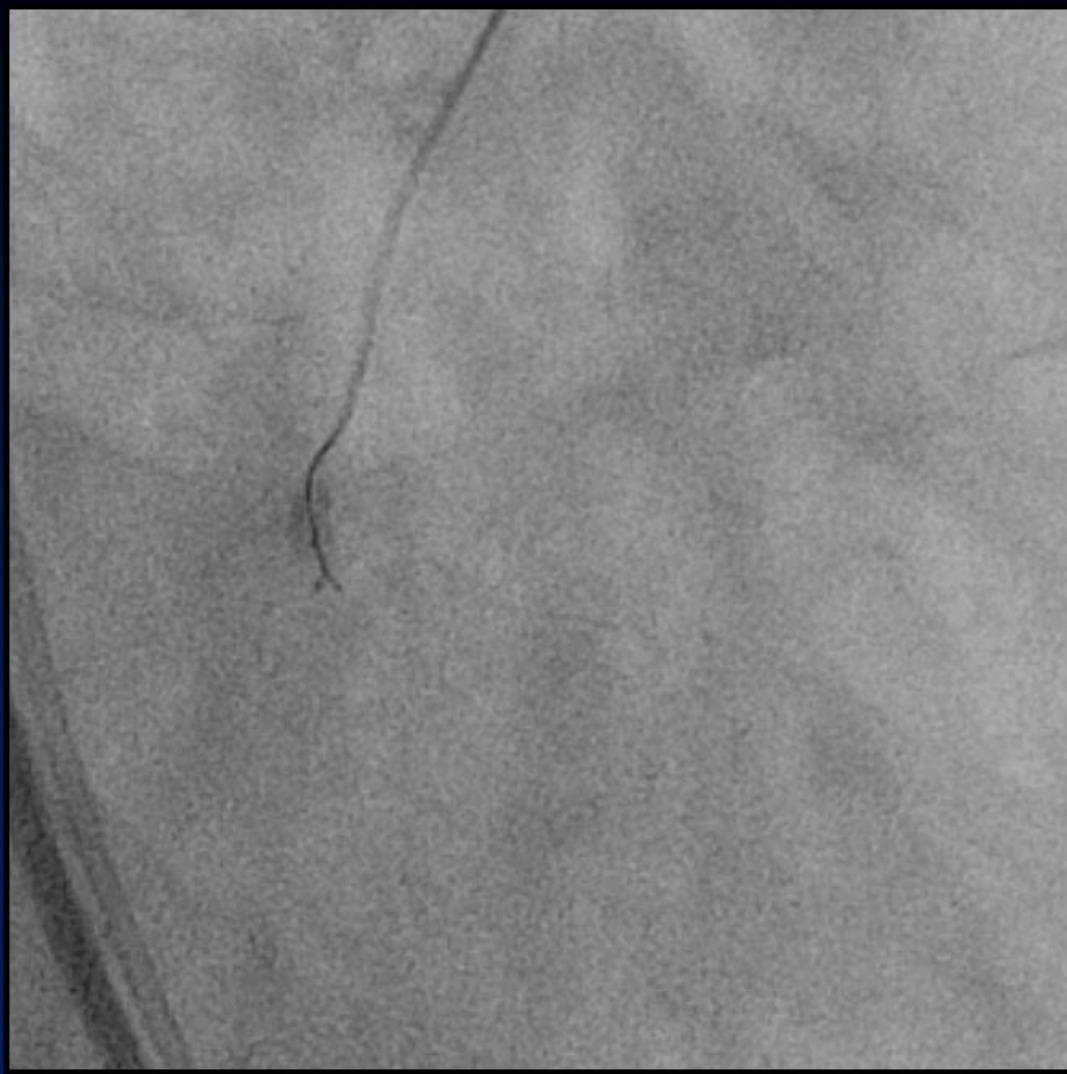


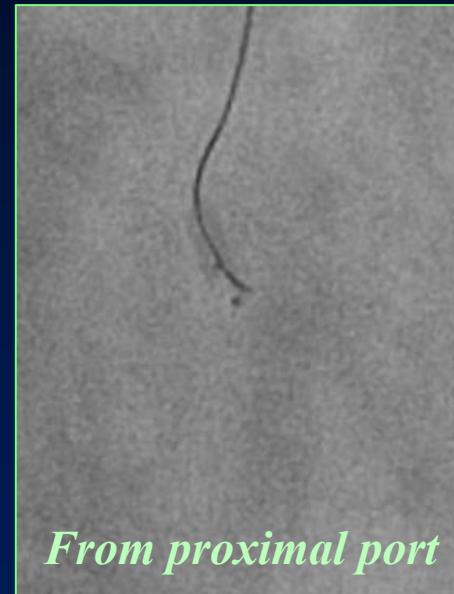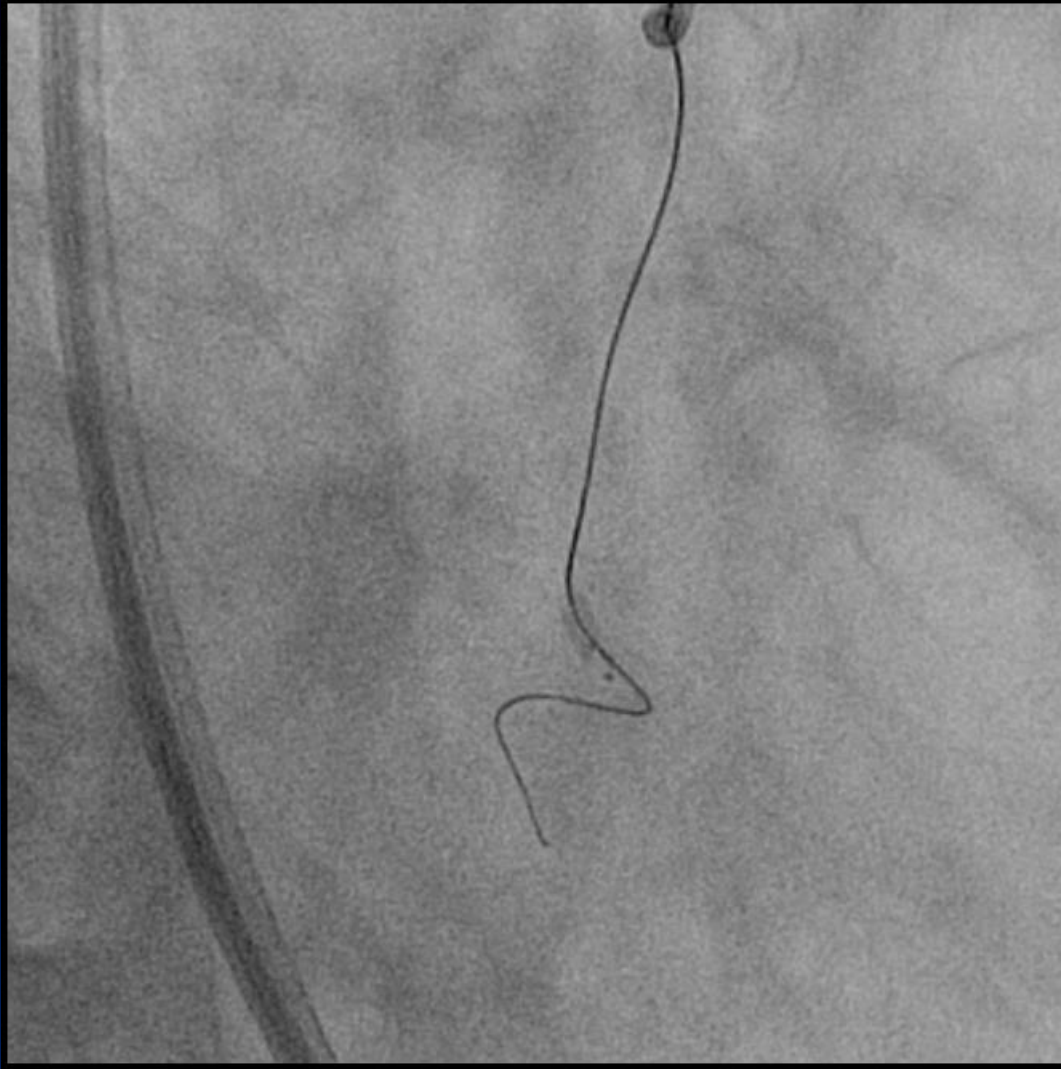
Failed single wiring with Fielder XT



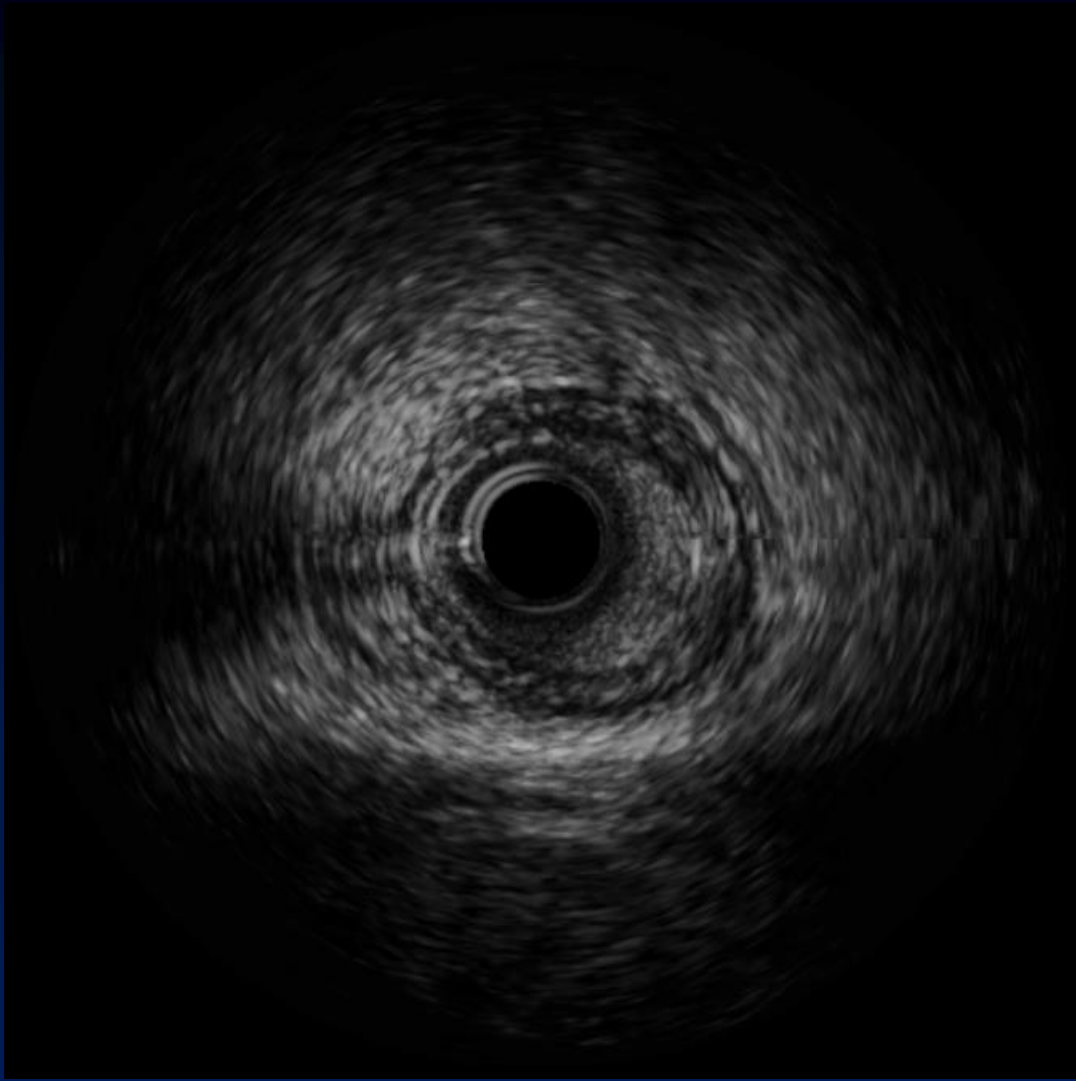
Stingray balloon accessed

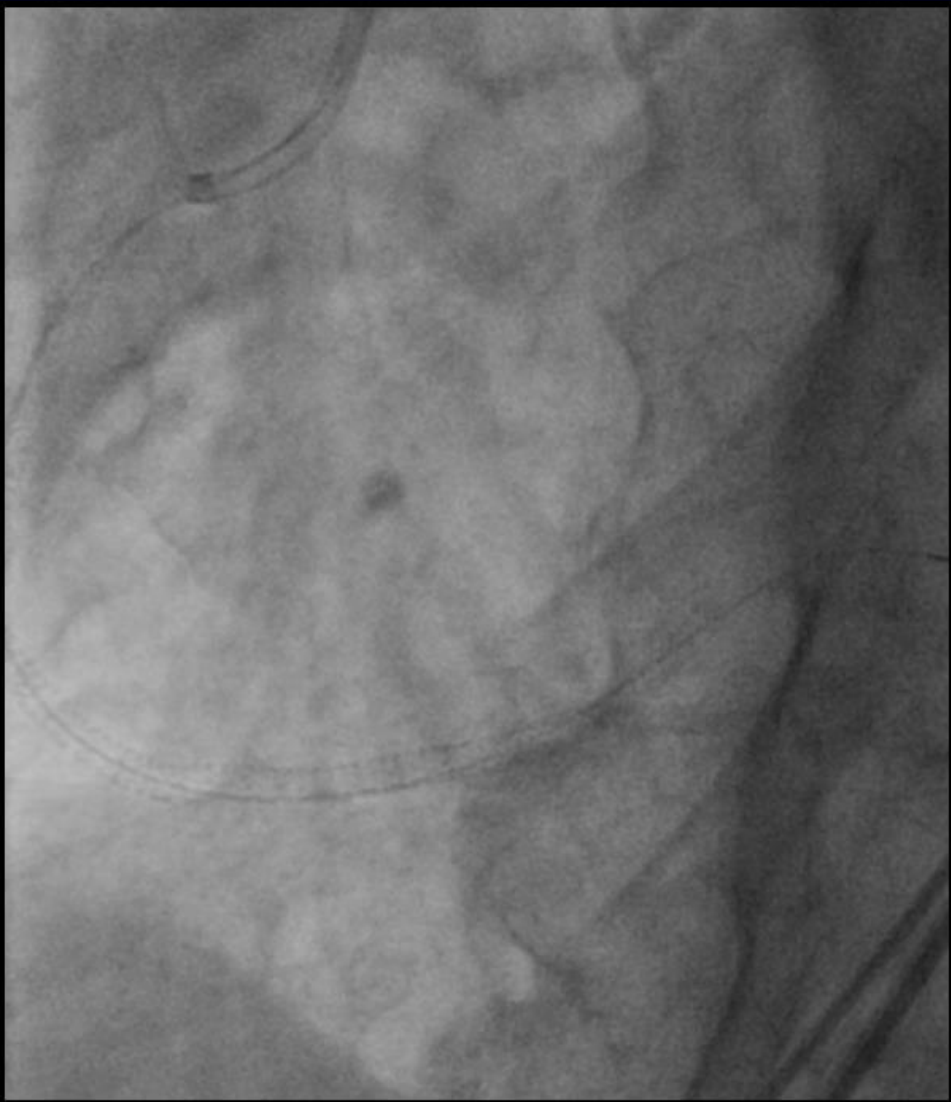
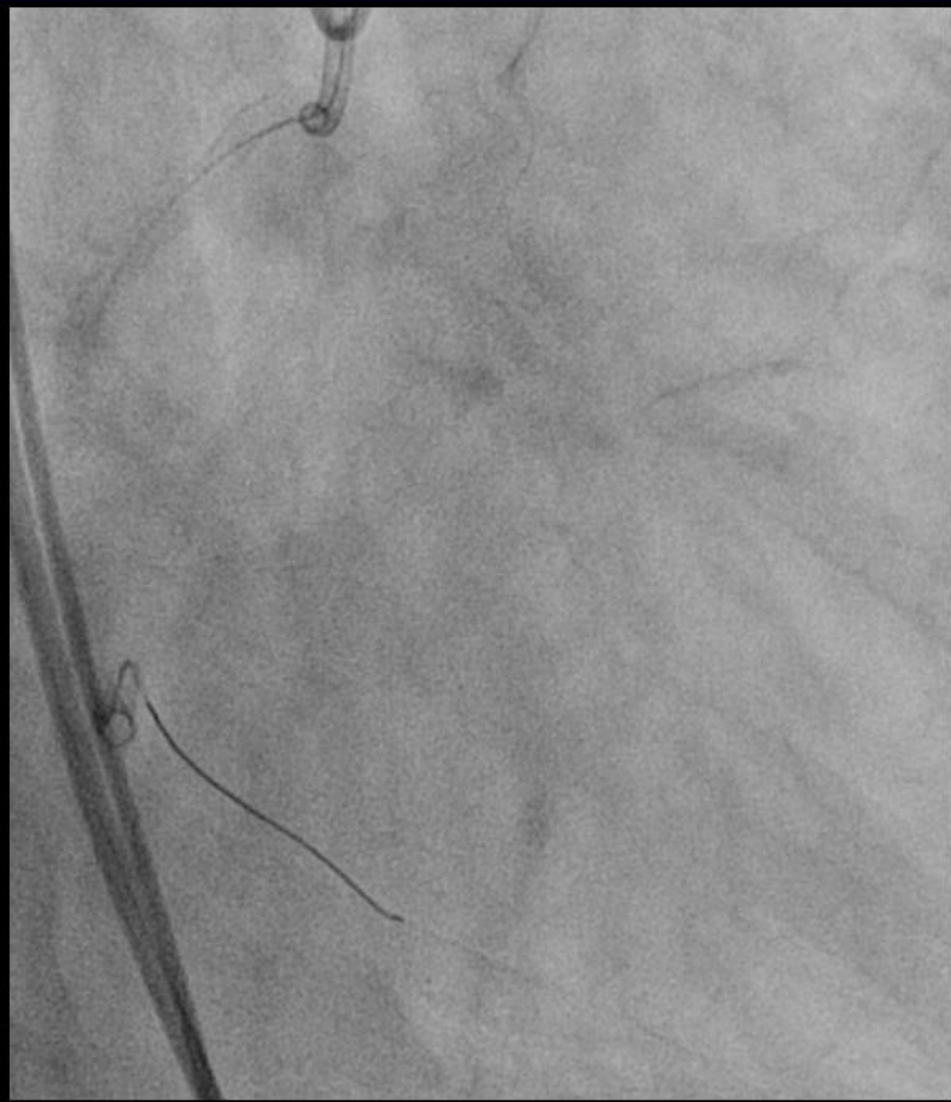
Deep puncture like Seldinger method



Successful crossing with Fielder XTR



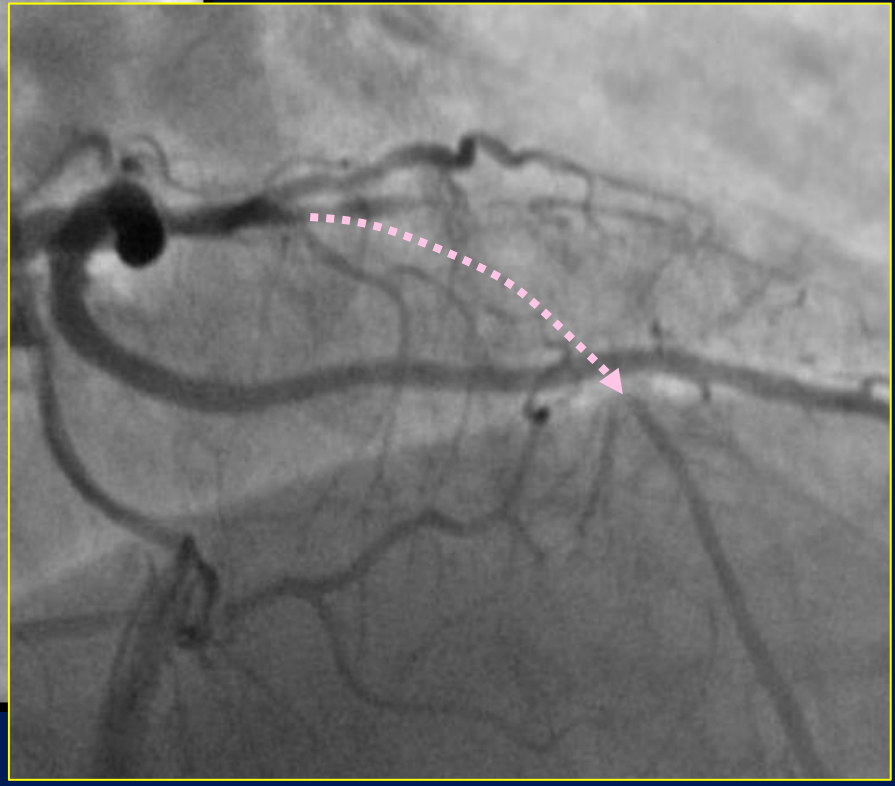
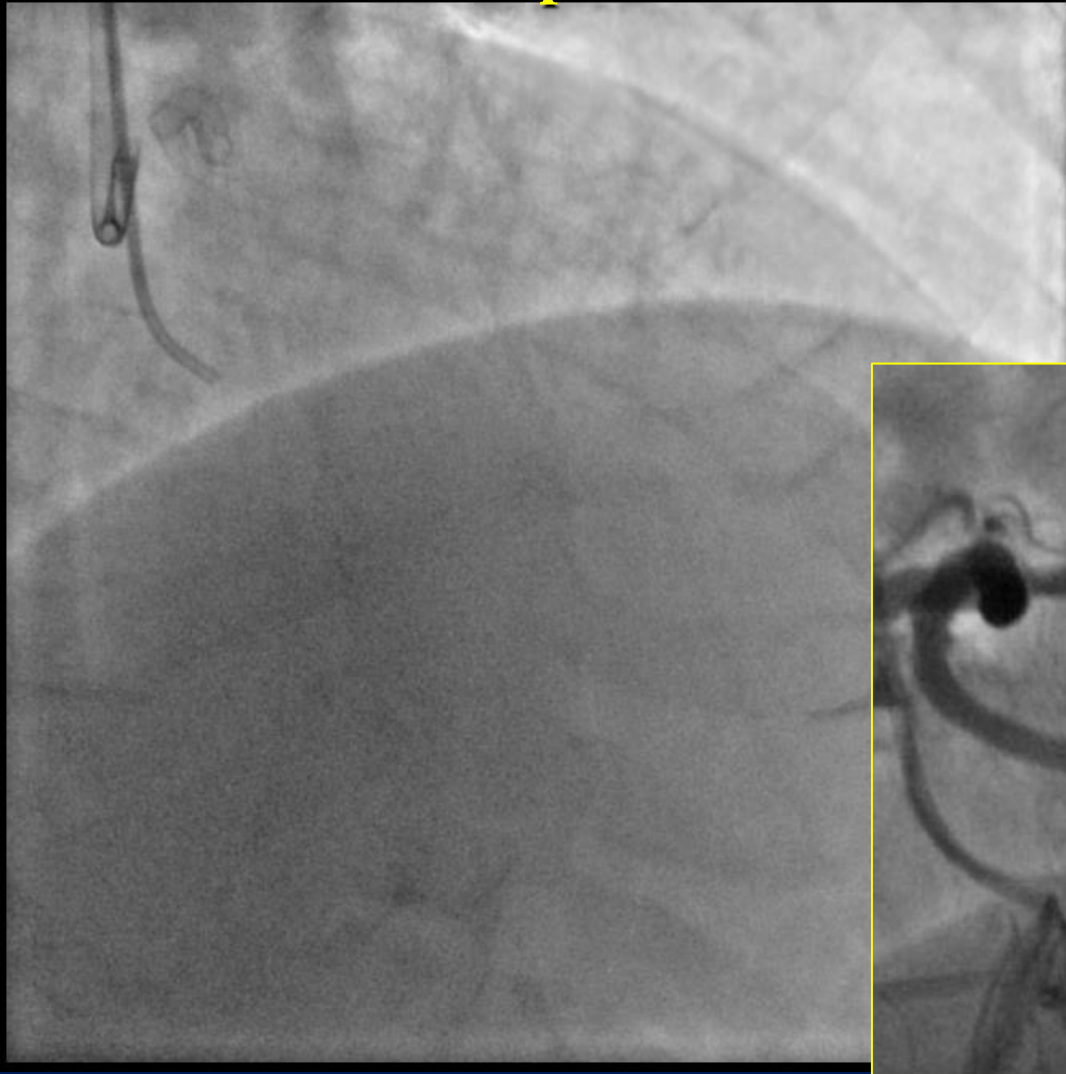

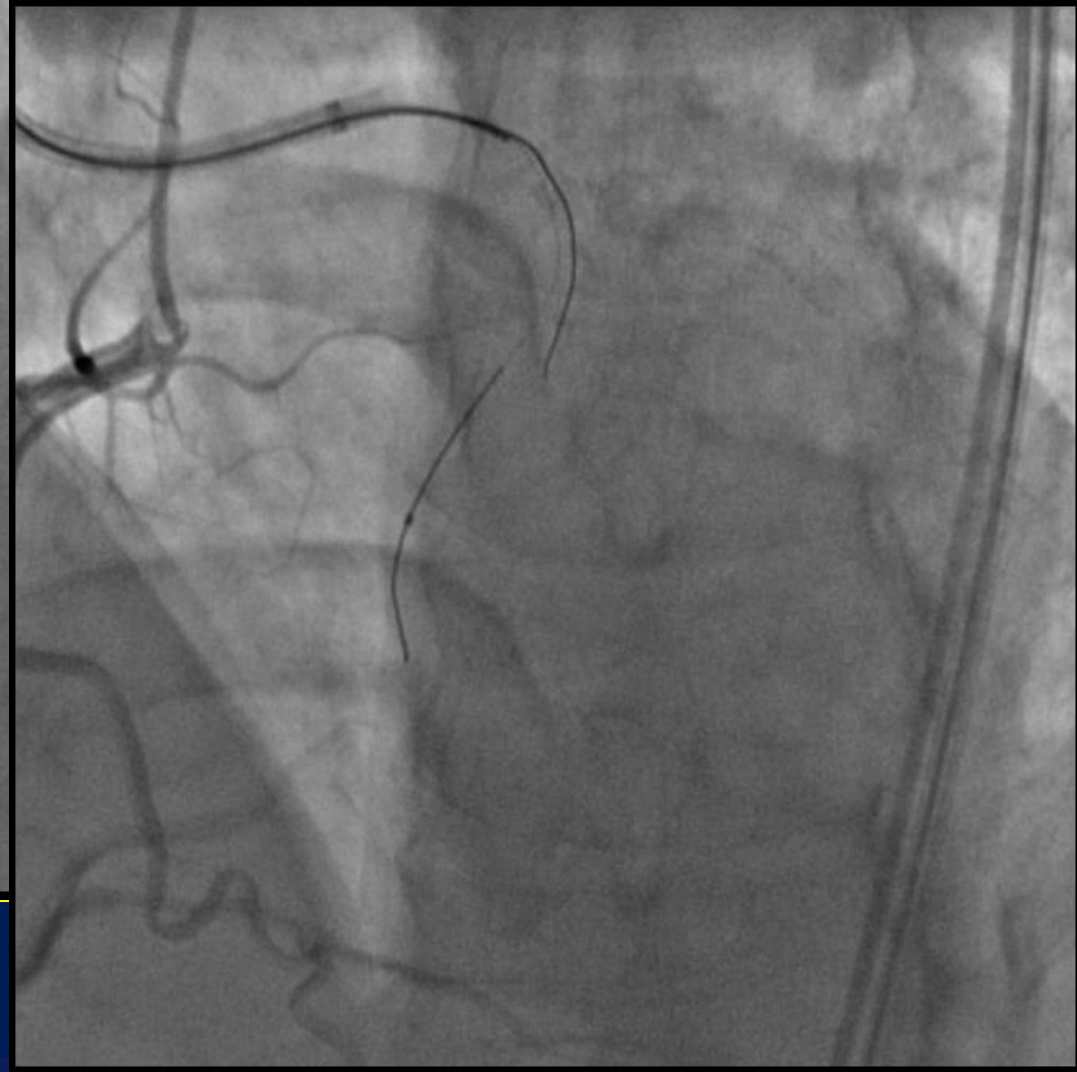
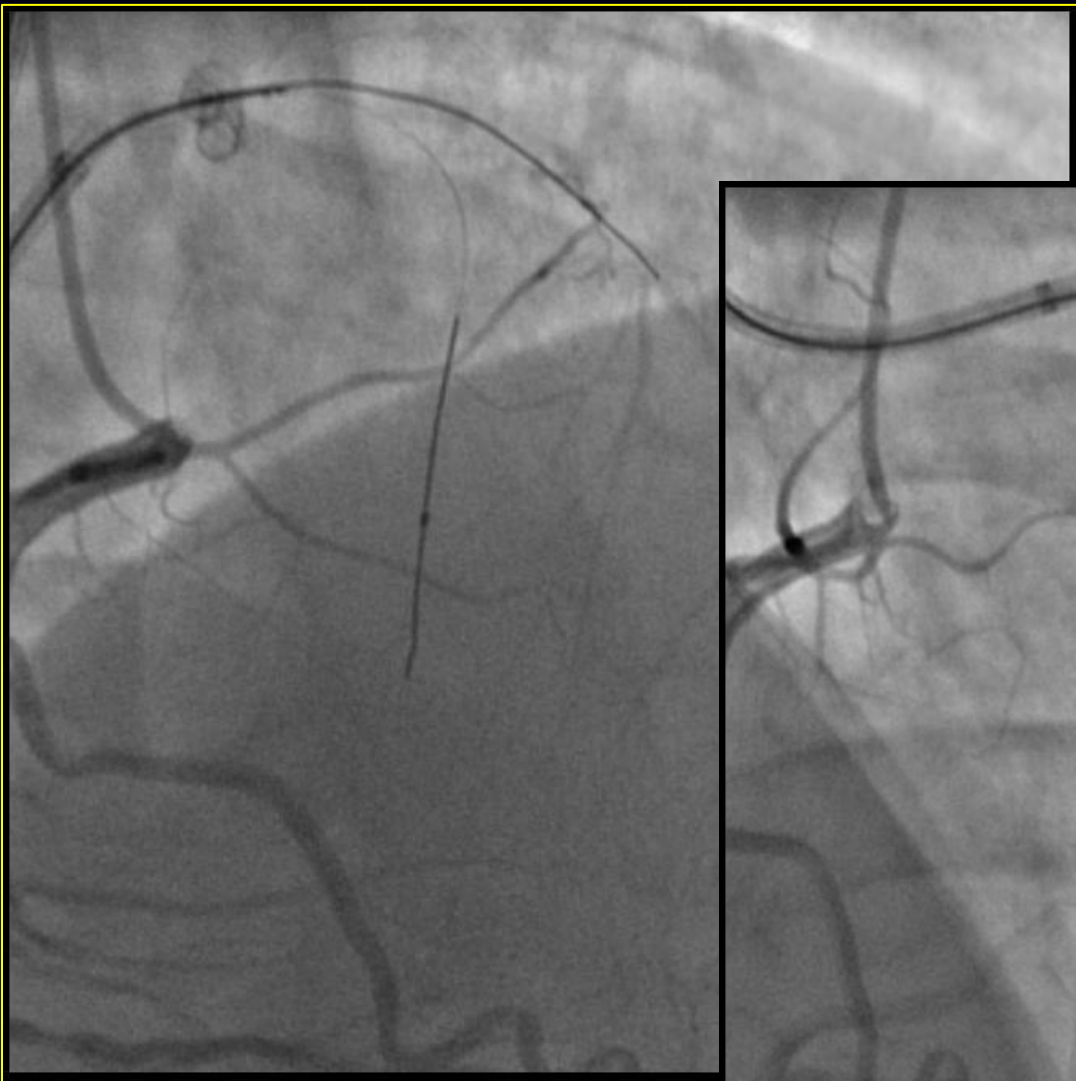
Final angiogram

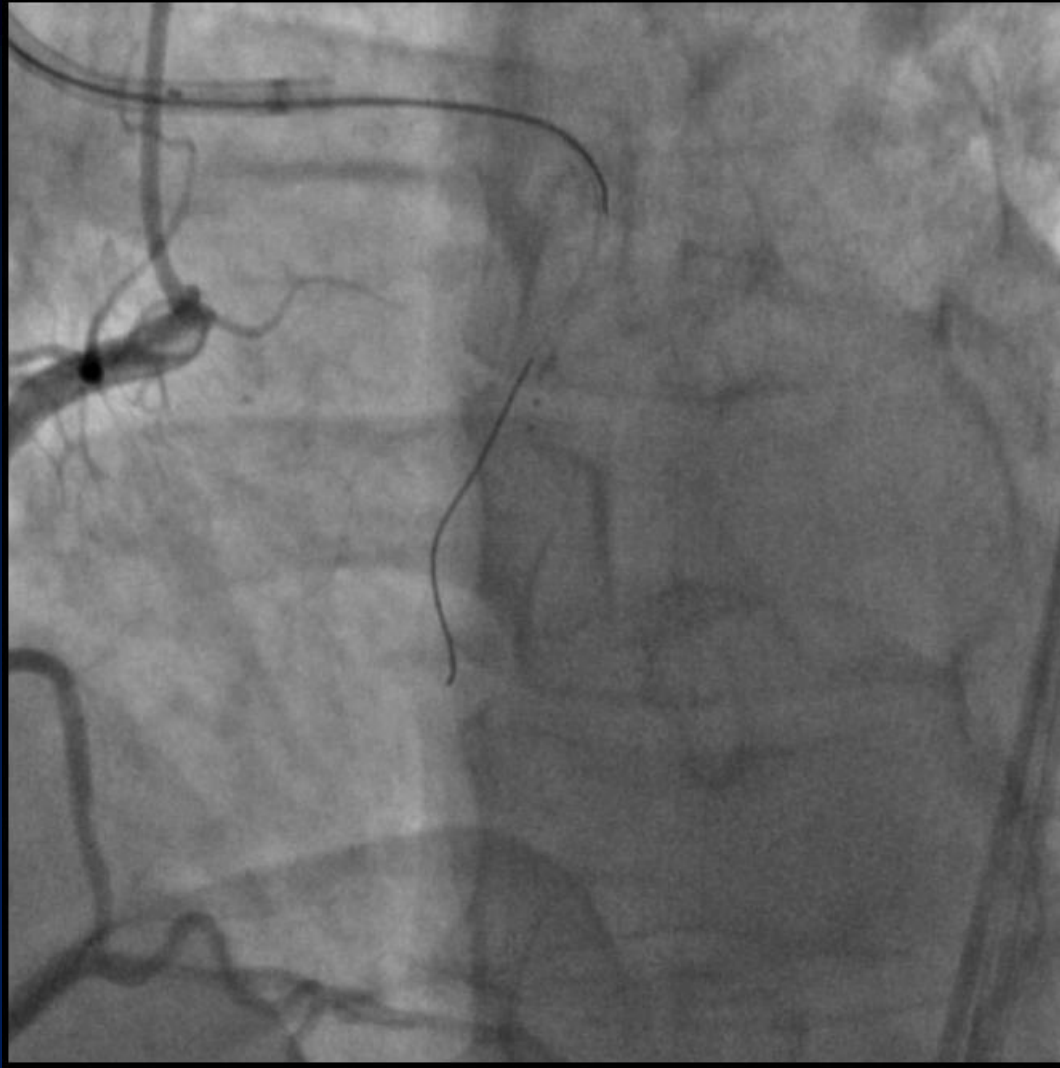
Tips and Tricks of Bridge Point System

- ◆ Wire change after puncturing
- ◆ Deep puncturing

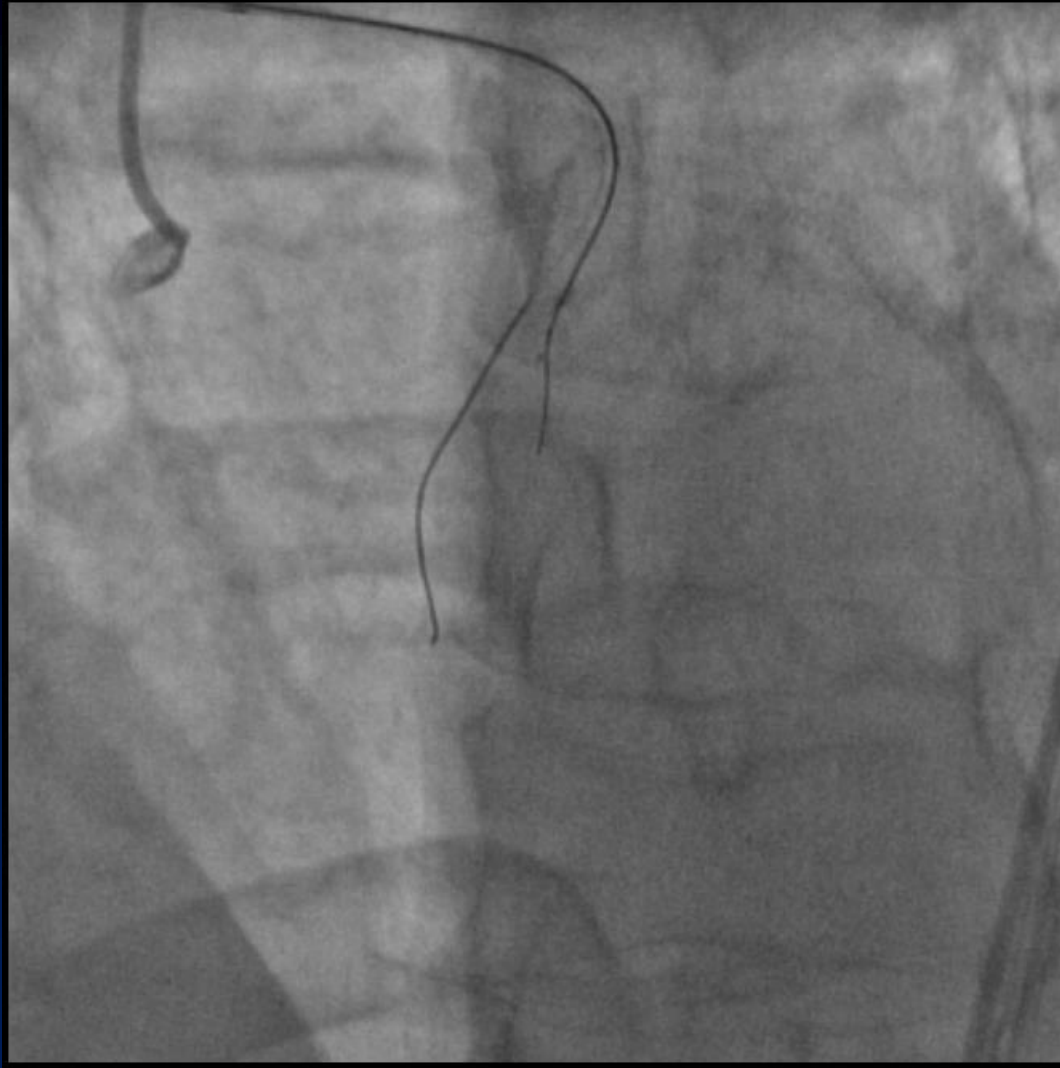
1st Attempt for LAD-CTO: Bail-out Use



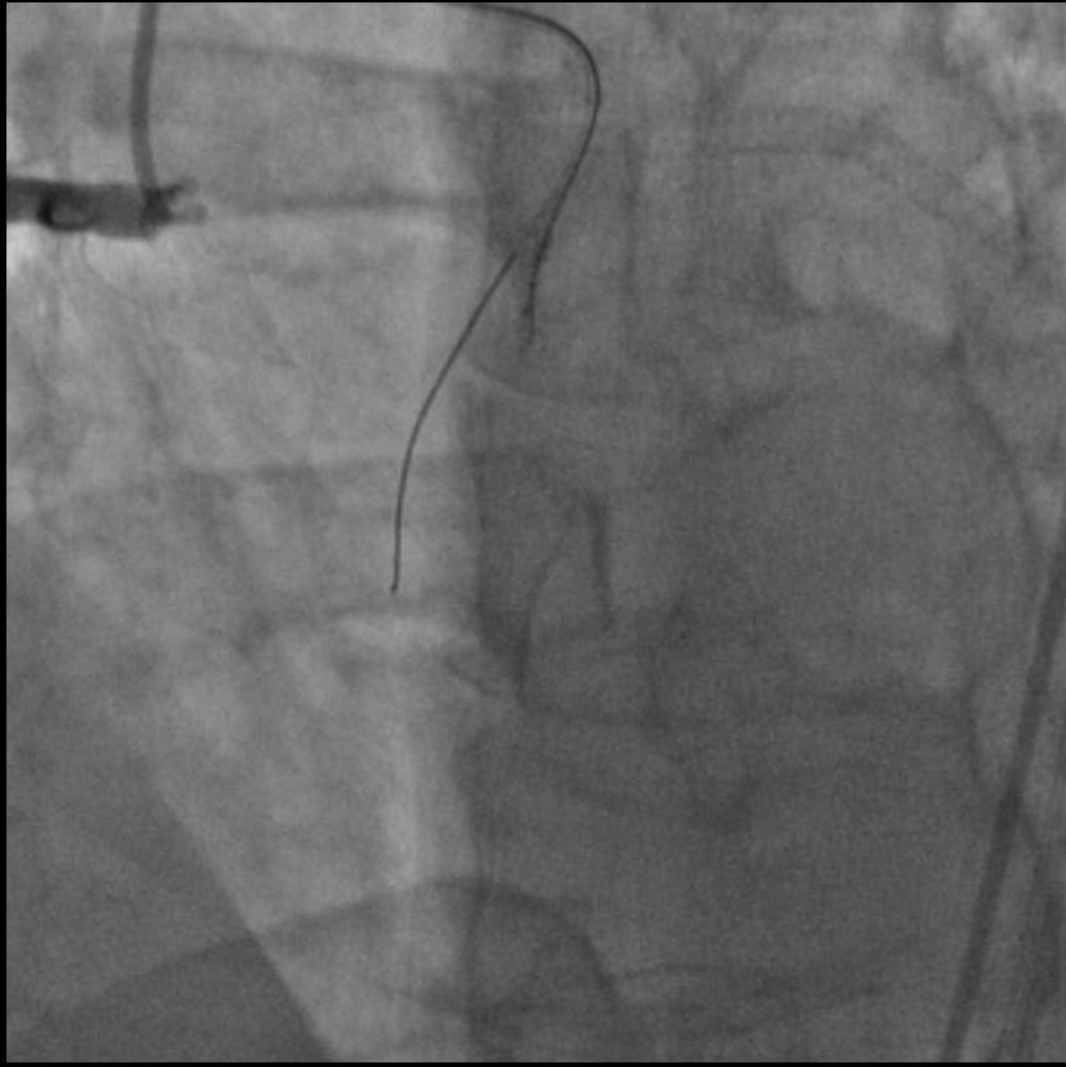




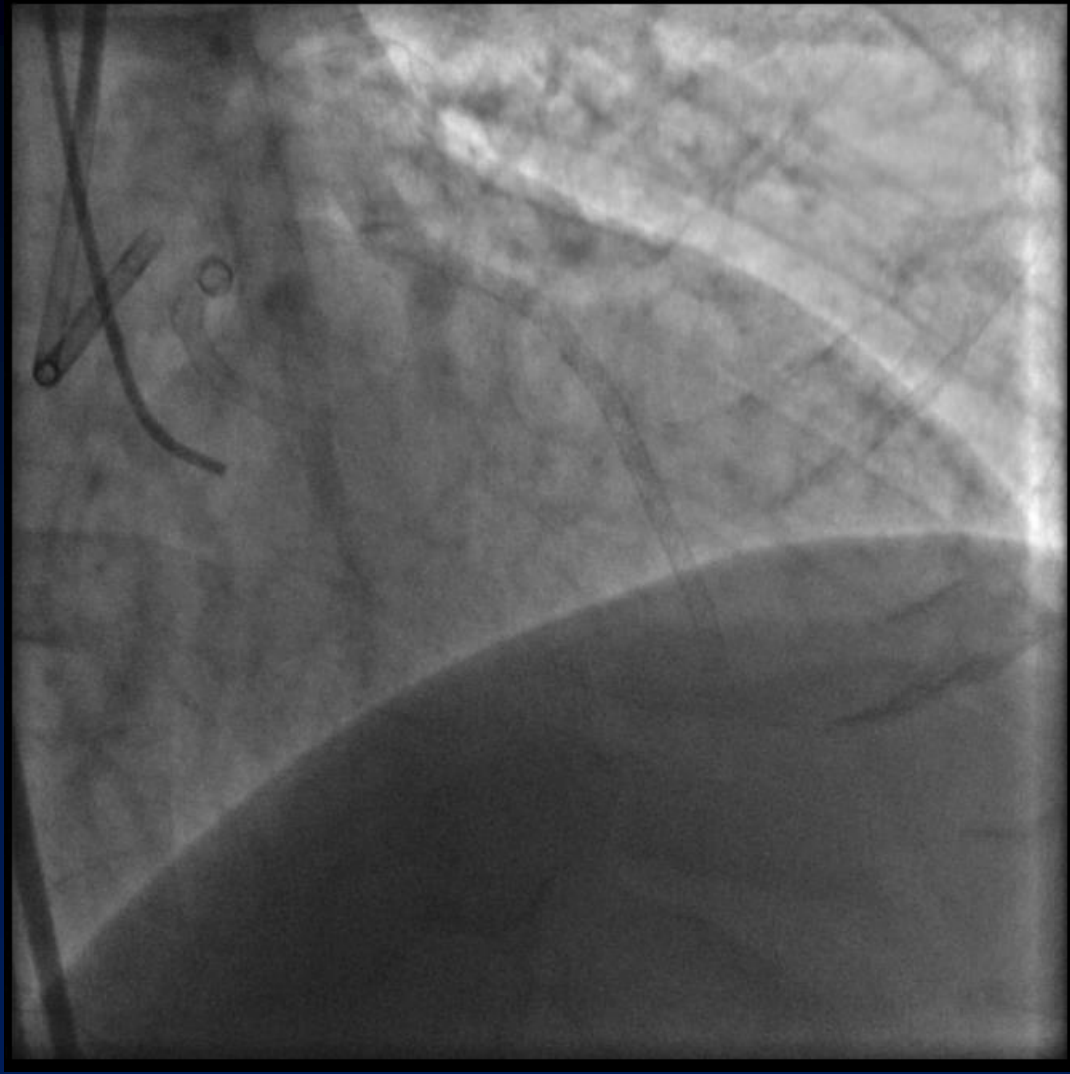Stingray balloon accessed



Deep puncture!

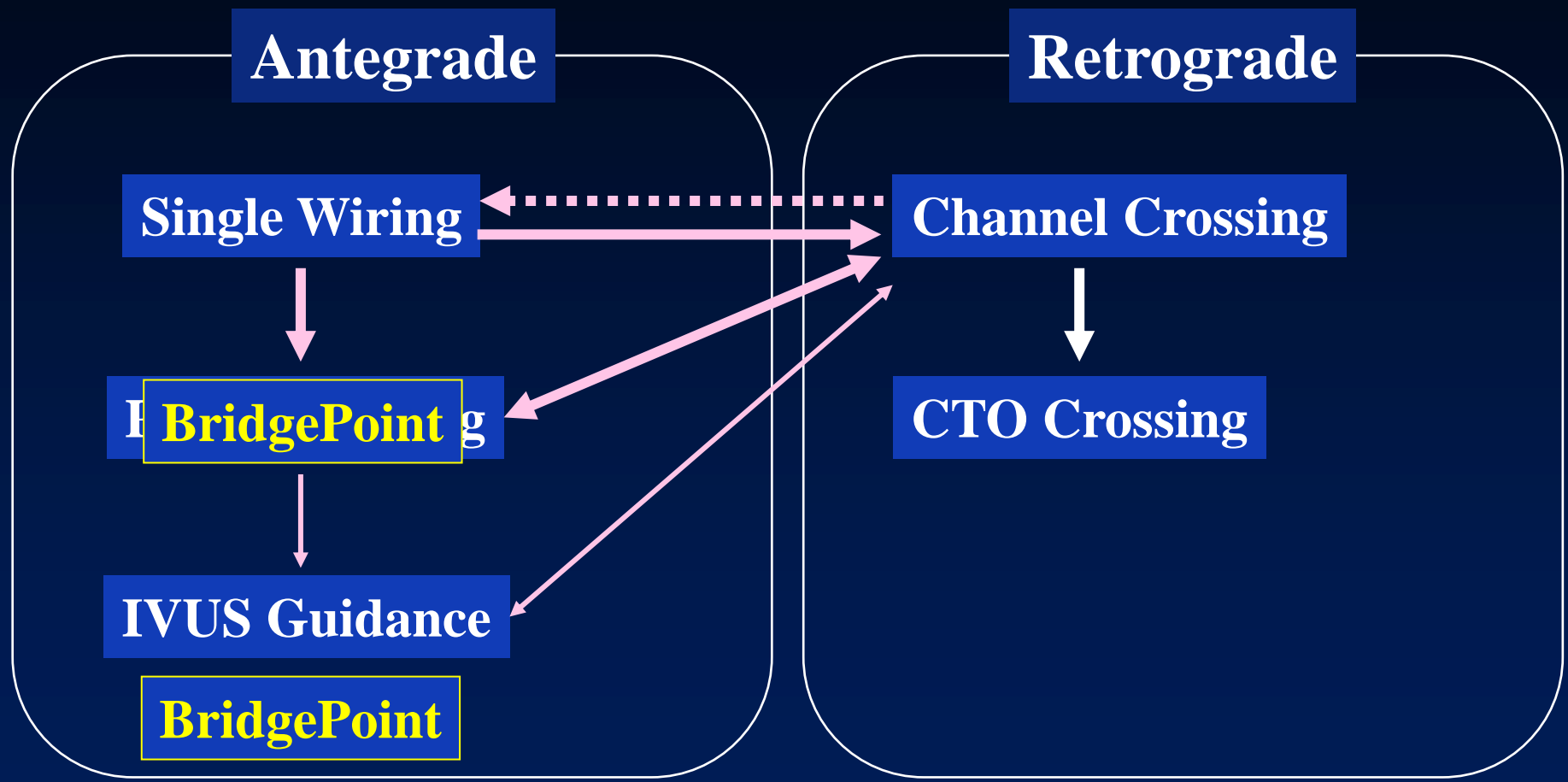


Successful crossing with Fielder XTR



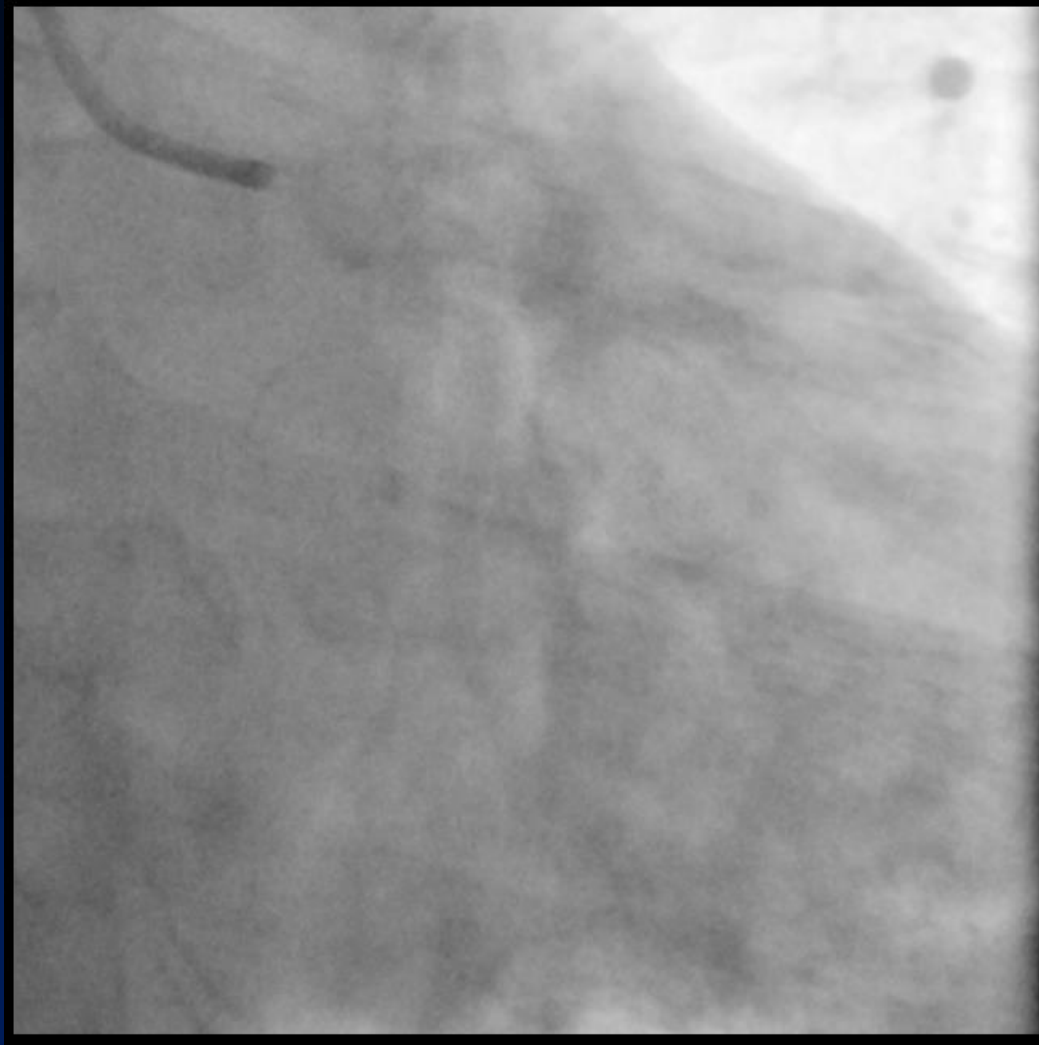
Final angiogram

BridgePoint: When and Where?

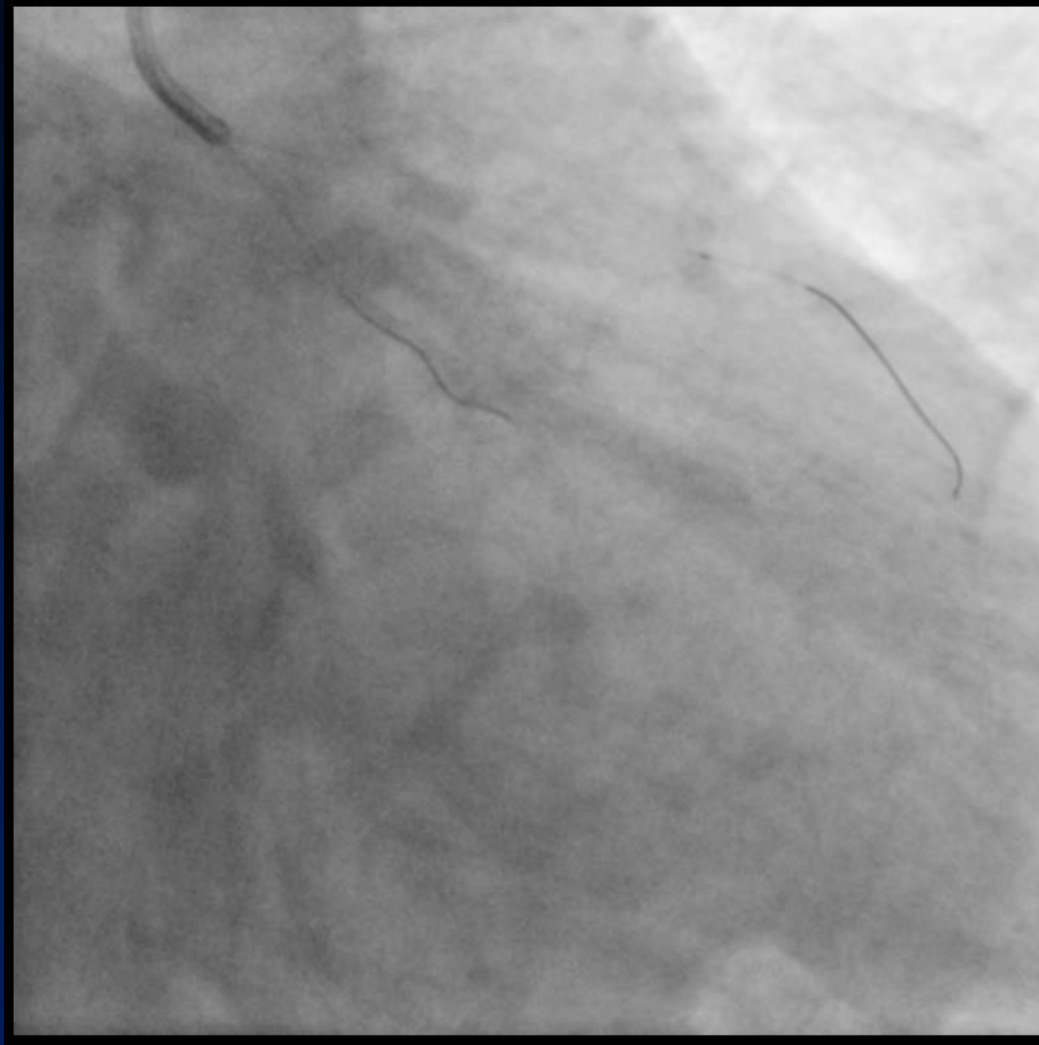

  **unsuccessful**

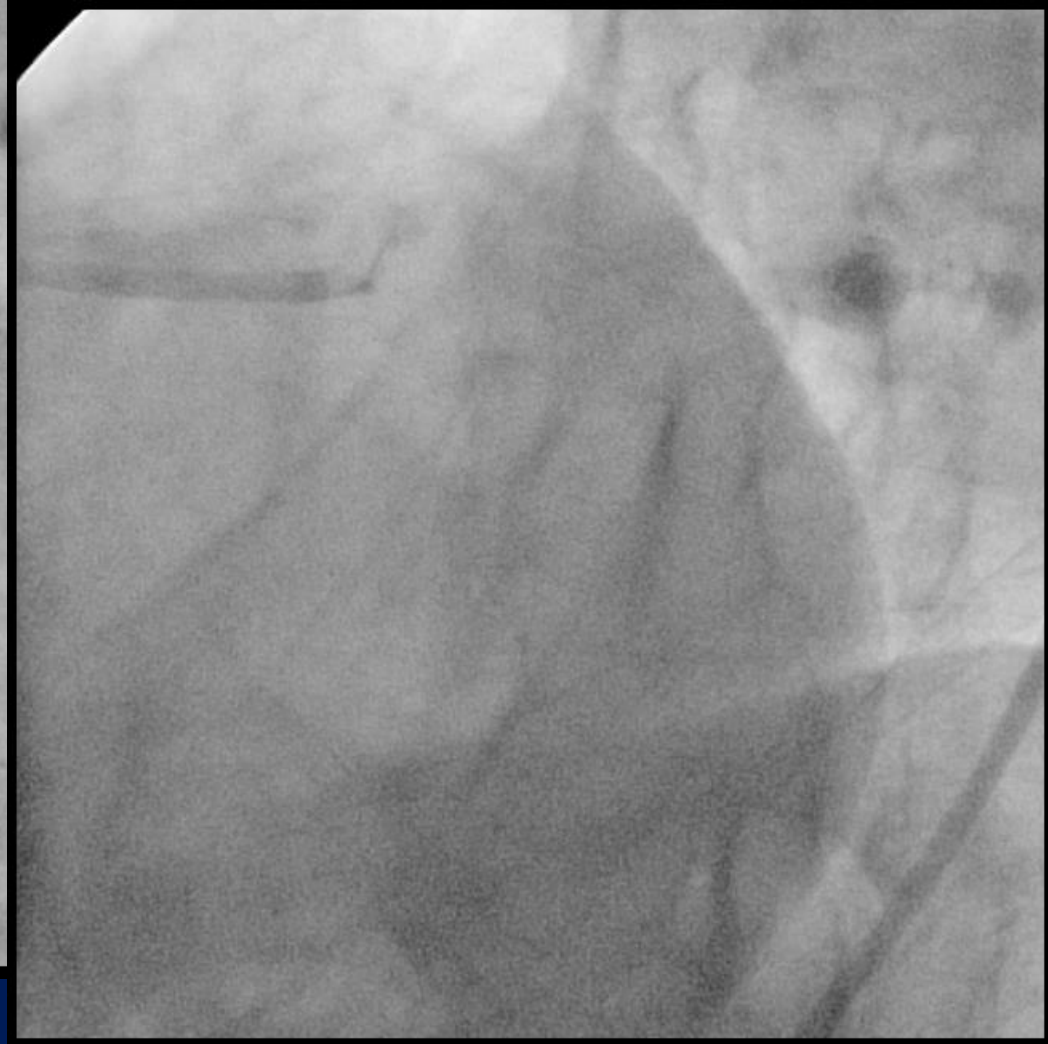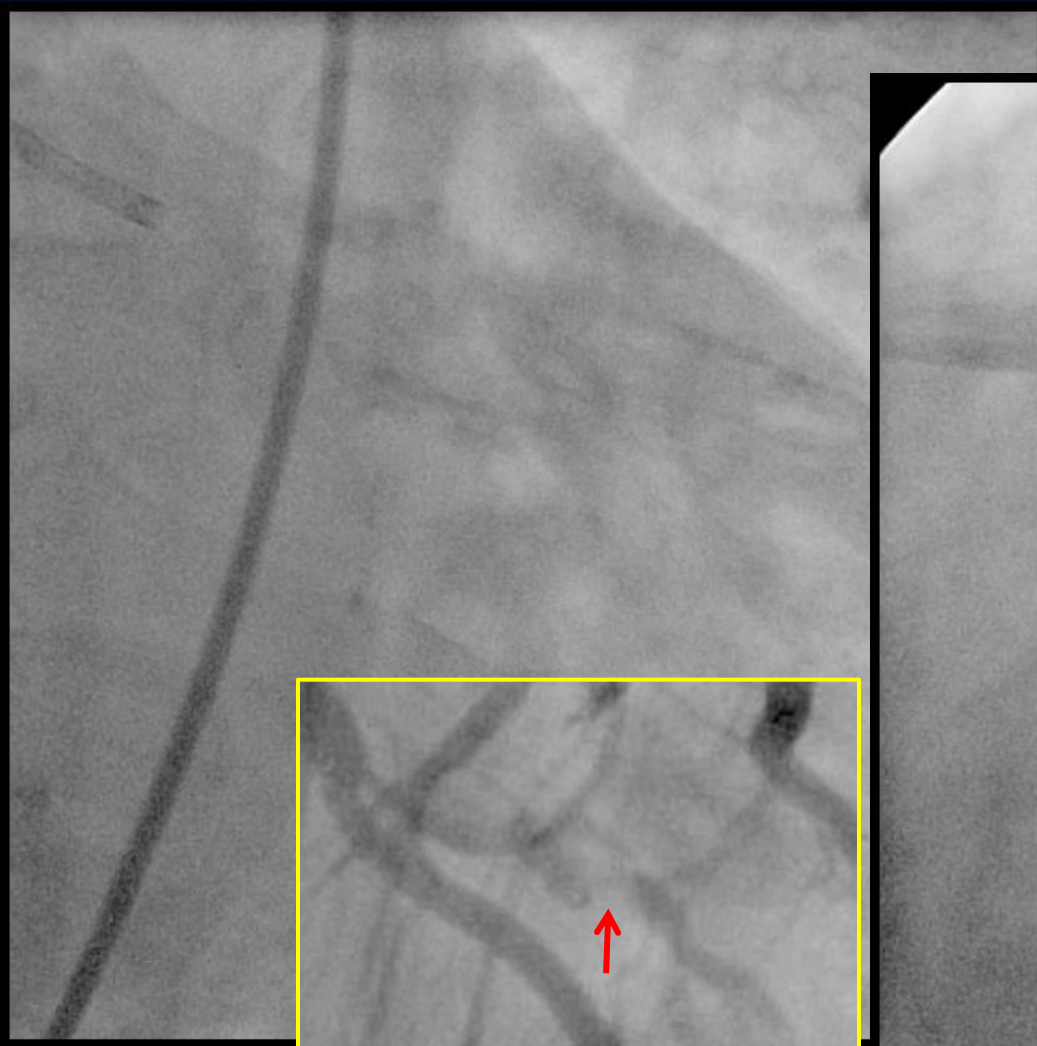
LCx CTO Equivalent Lesion



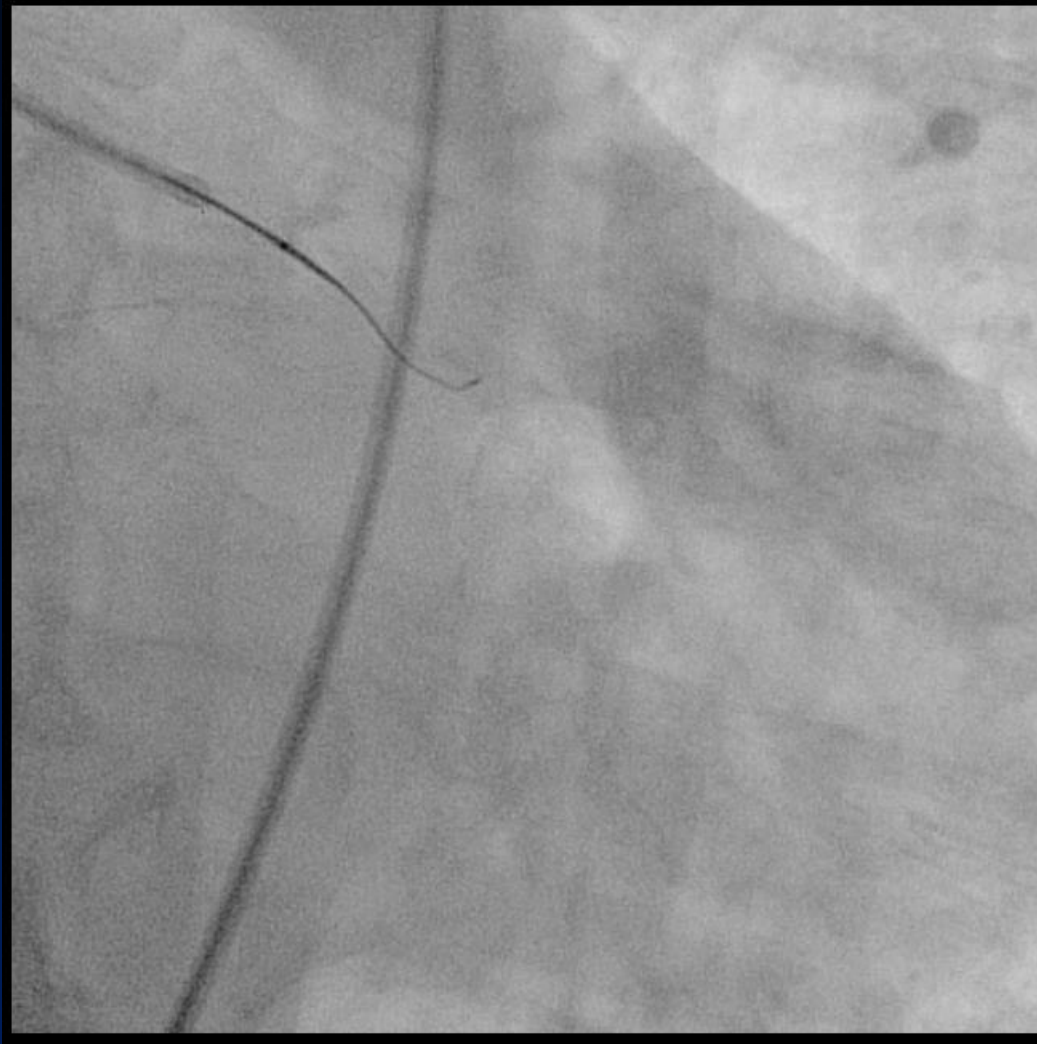
Unsuccessful wiring 3 times



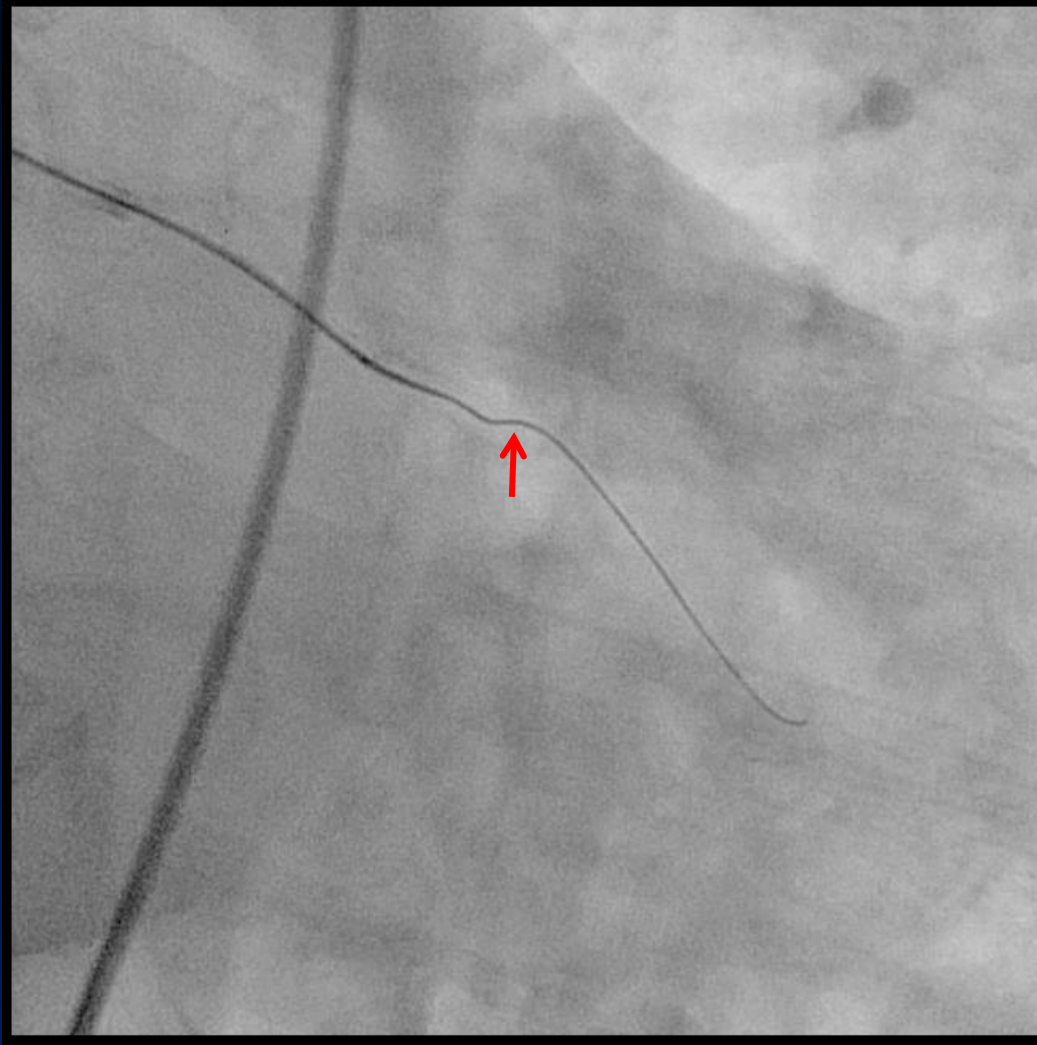
The 4th attempt



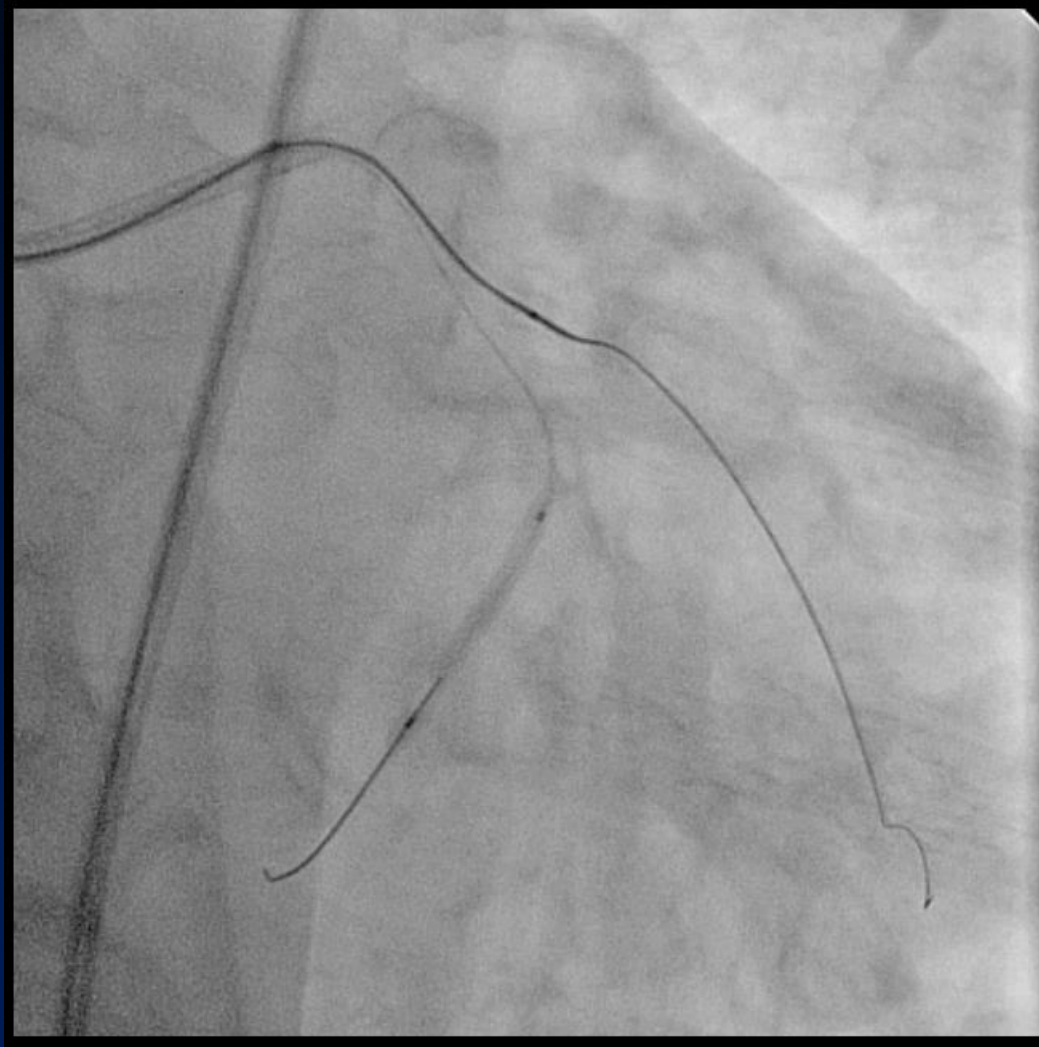
Fielder XT with Corsair



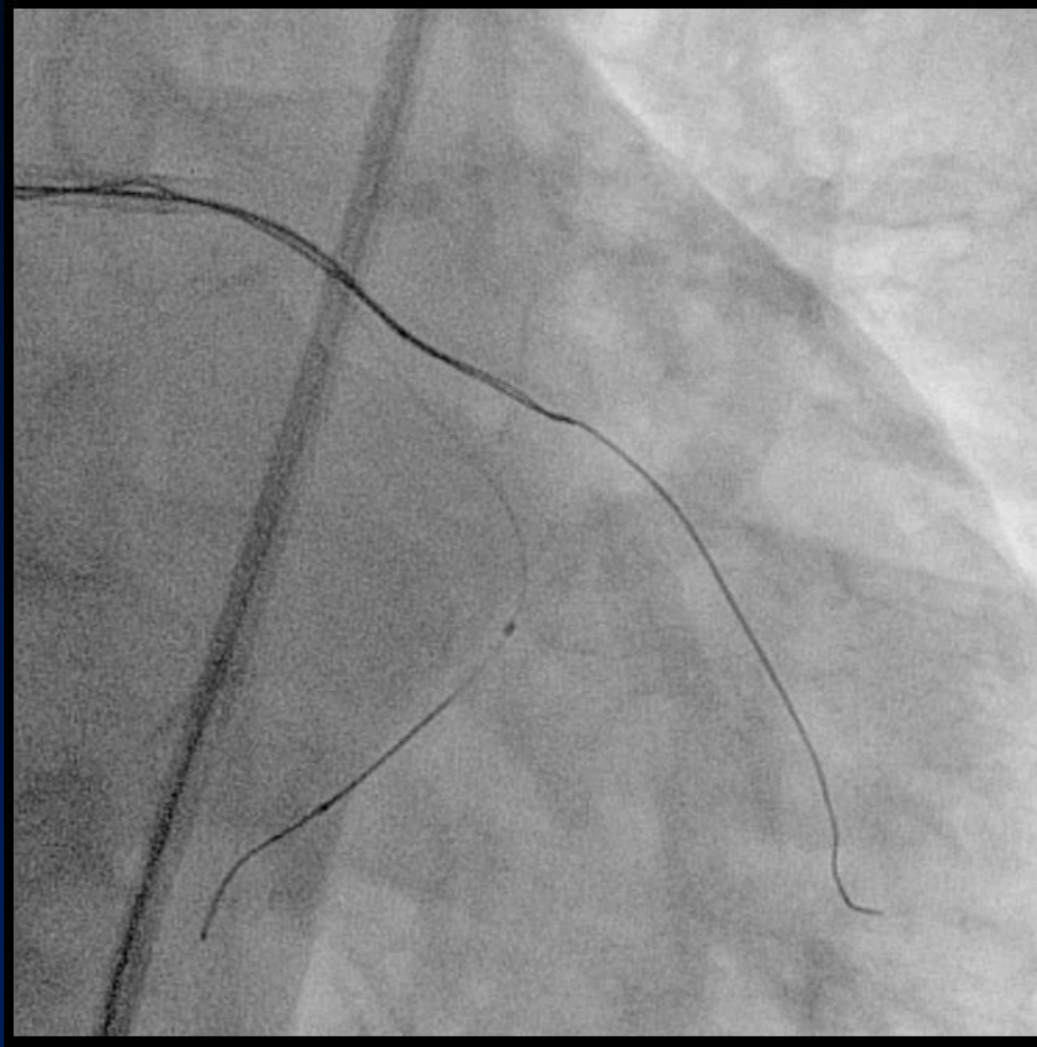Successful wiring, however...



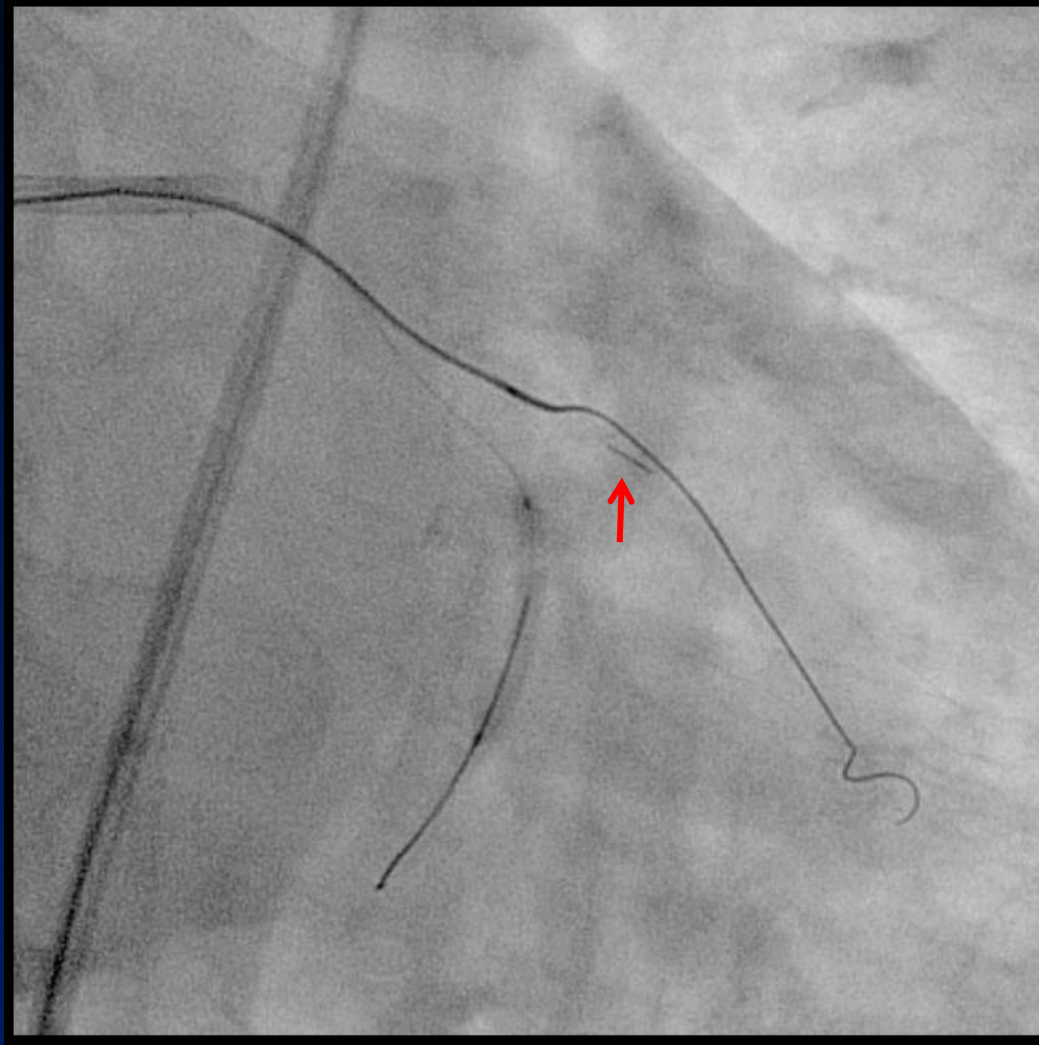
No balloon nor microcatheter crossed.



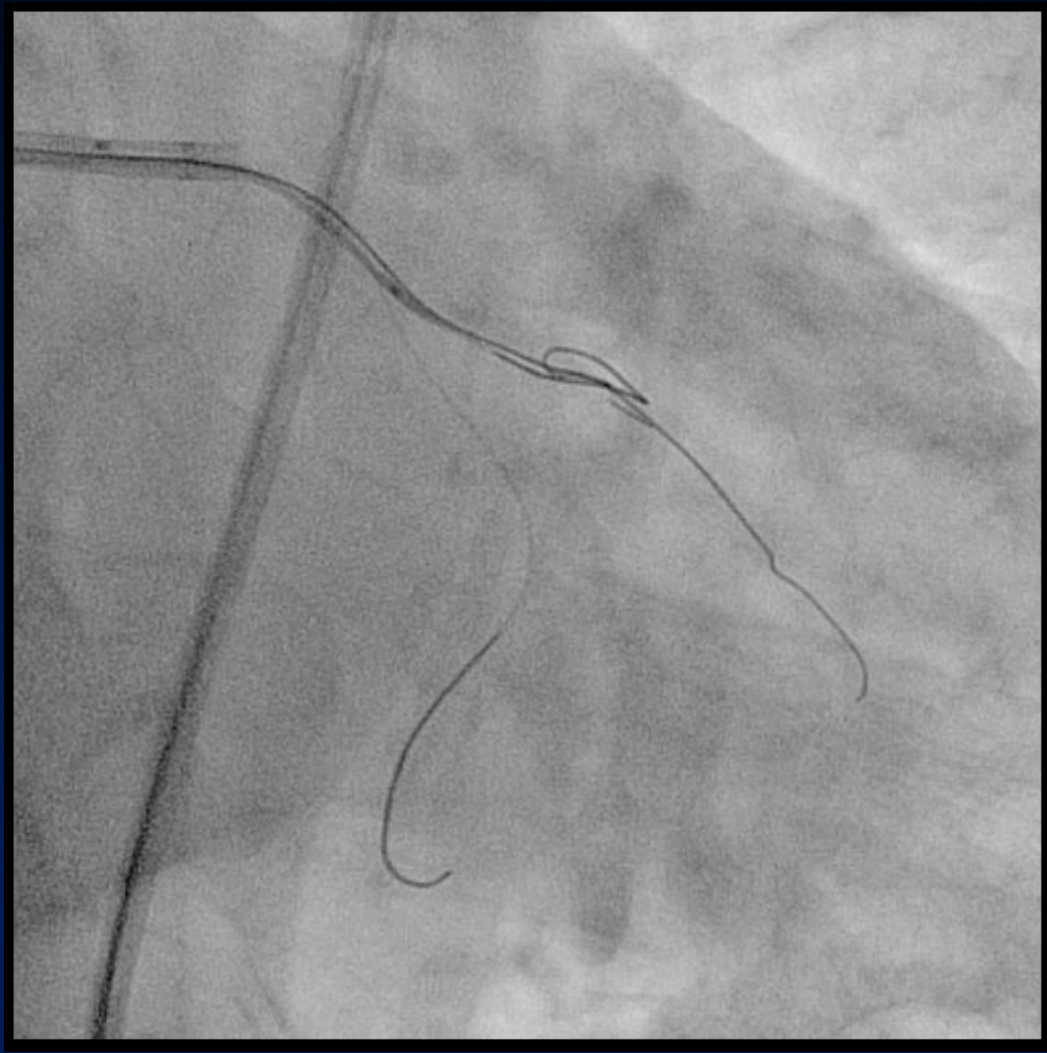
Crushing technique with another stiff wire



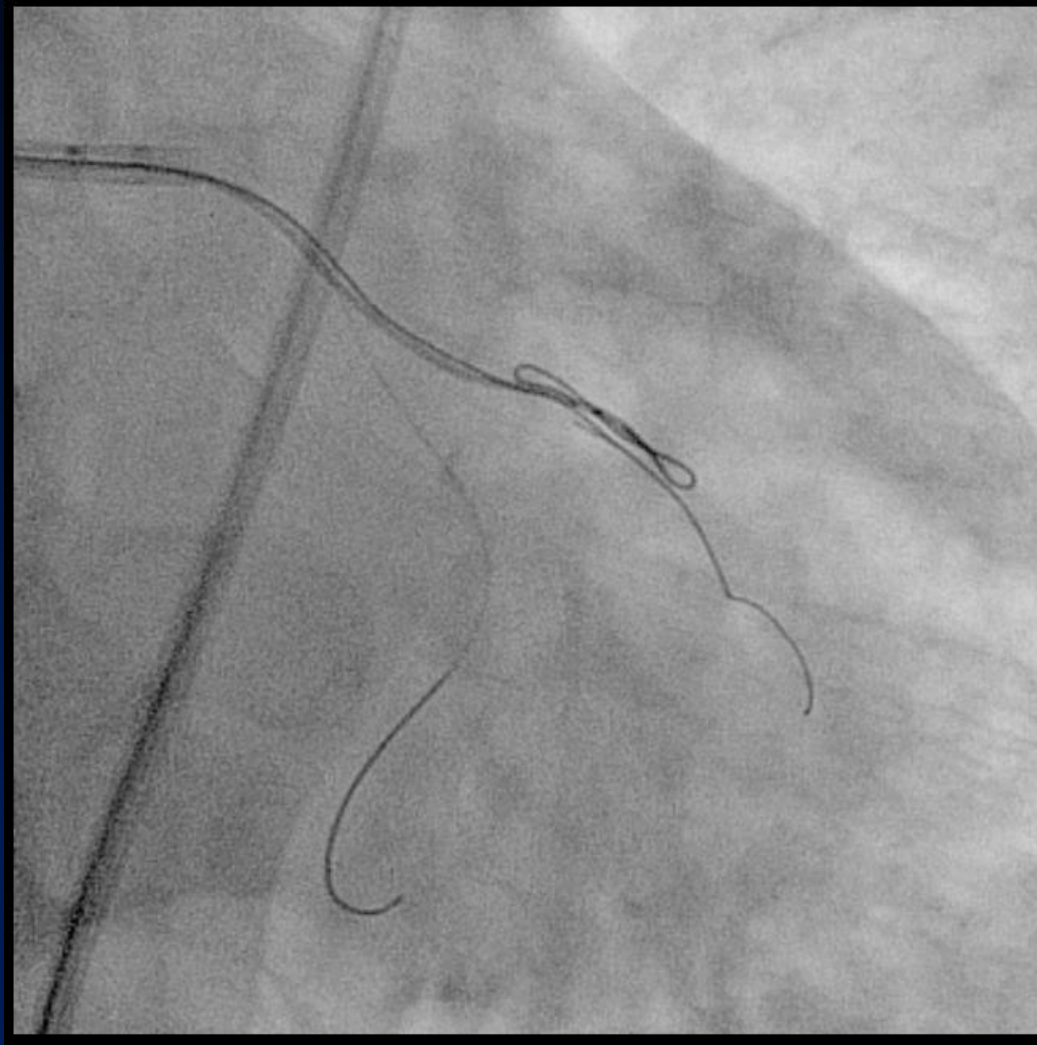
Wire fractured.



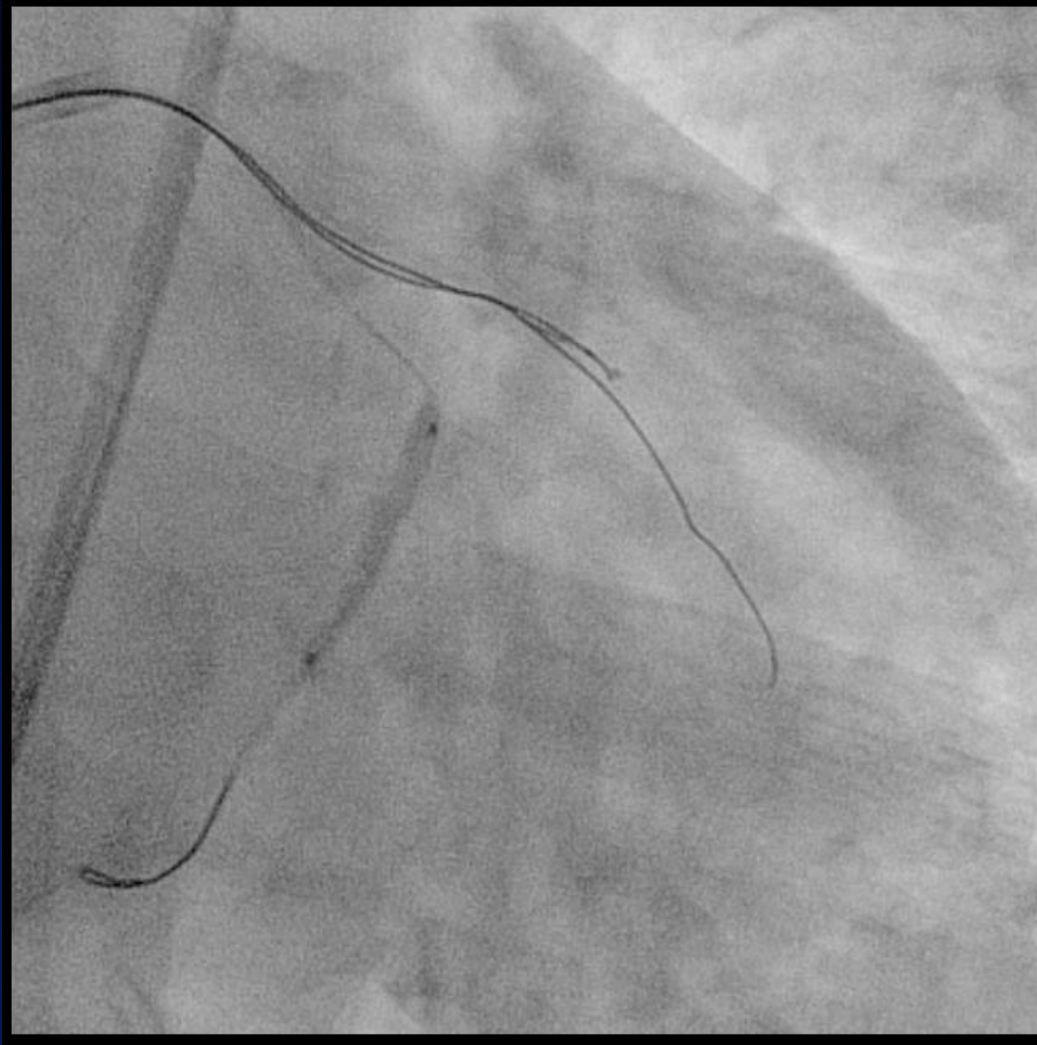
Knuckle wire with Fielder FC



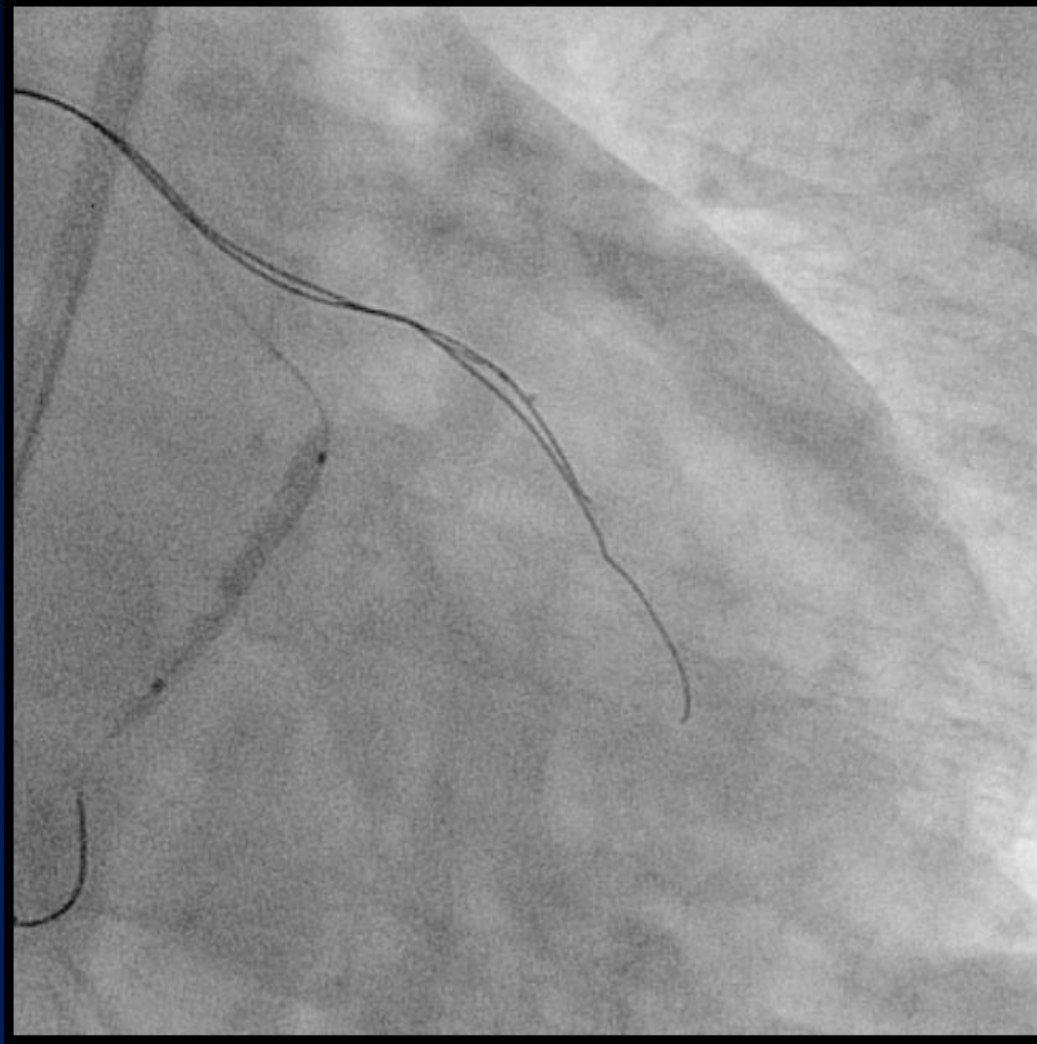
Dilatation of subintimal space with Corsair



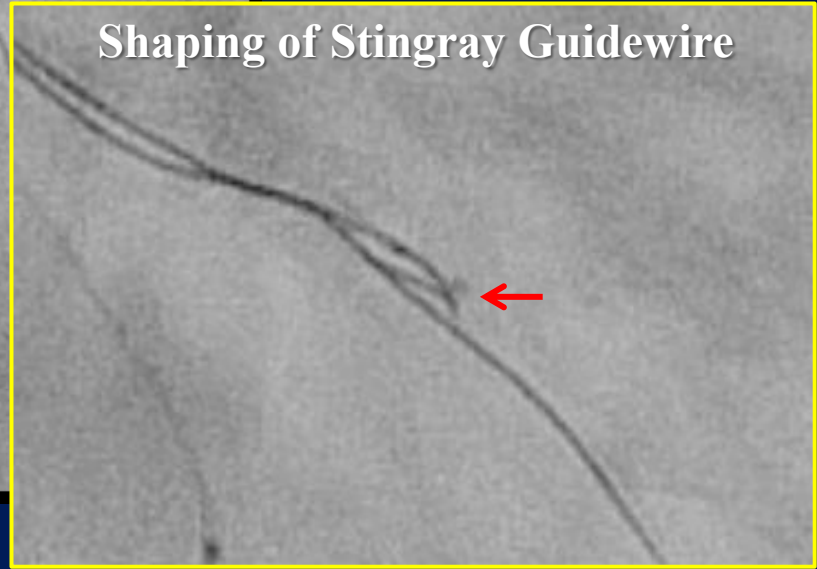
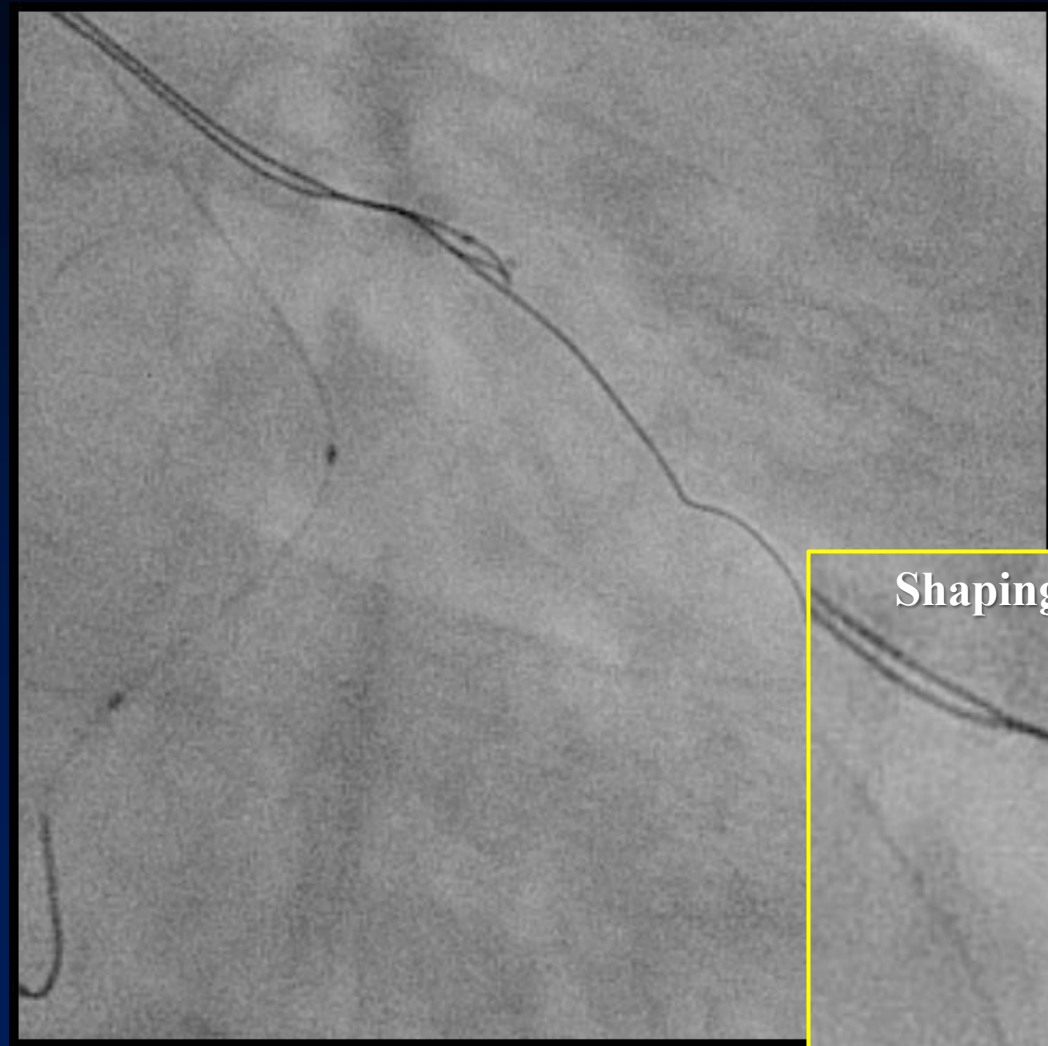
Stingray balloon delivery



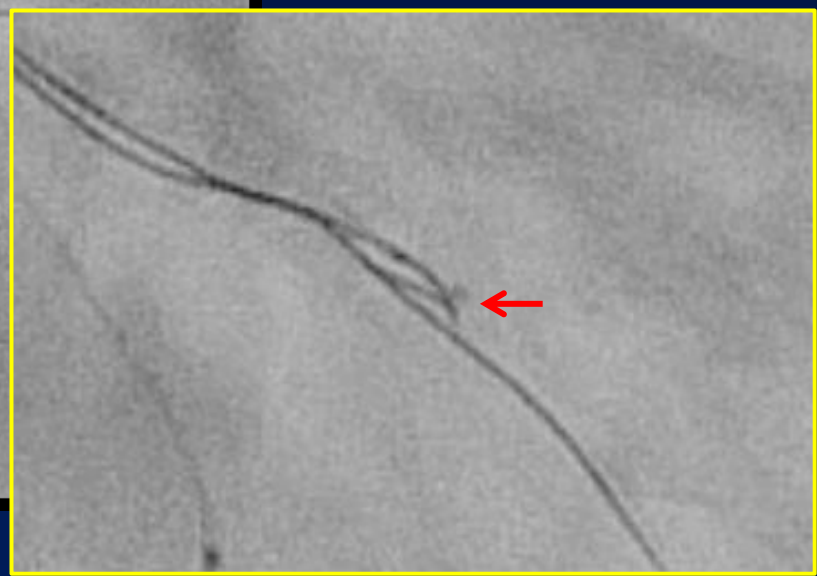
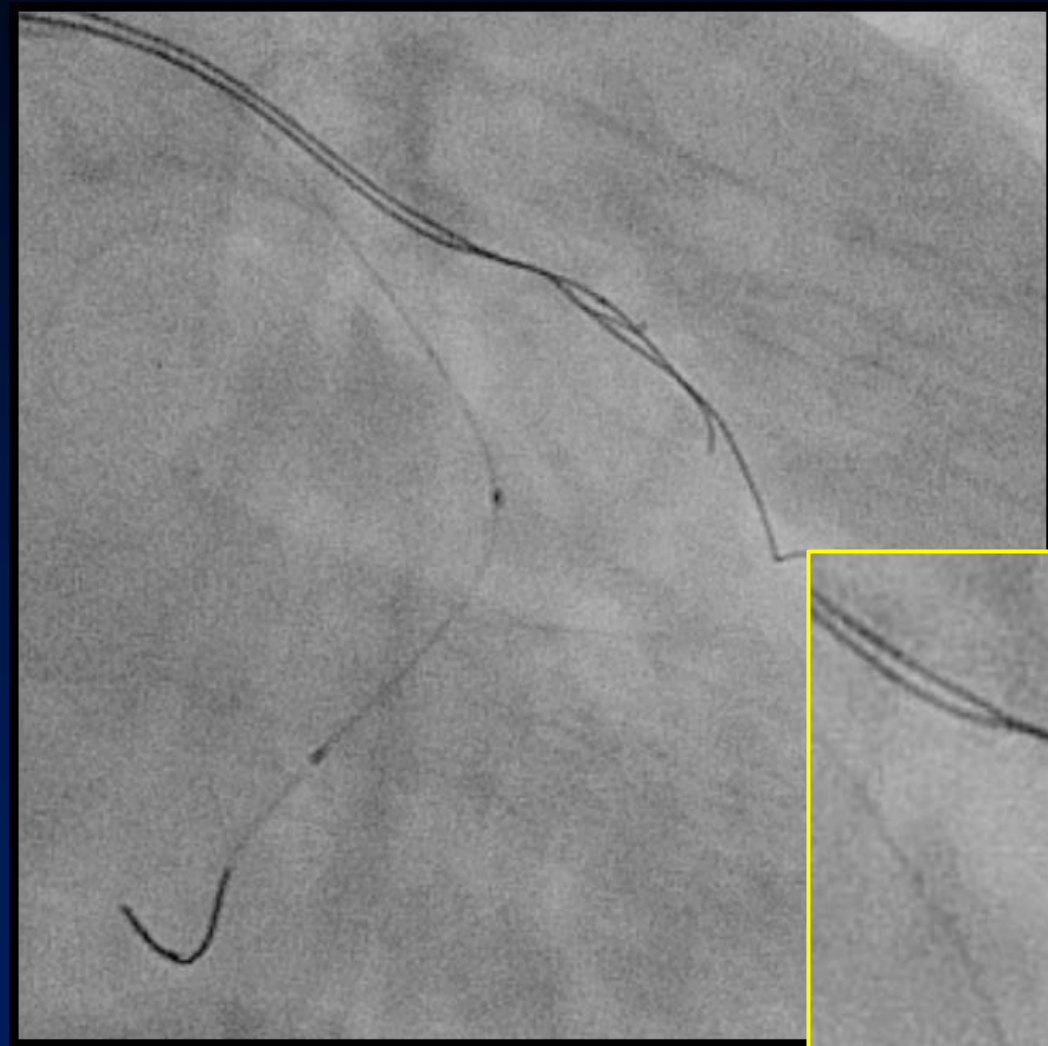
Unsuccessful 1st puncture



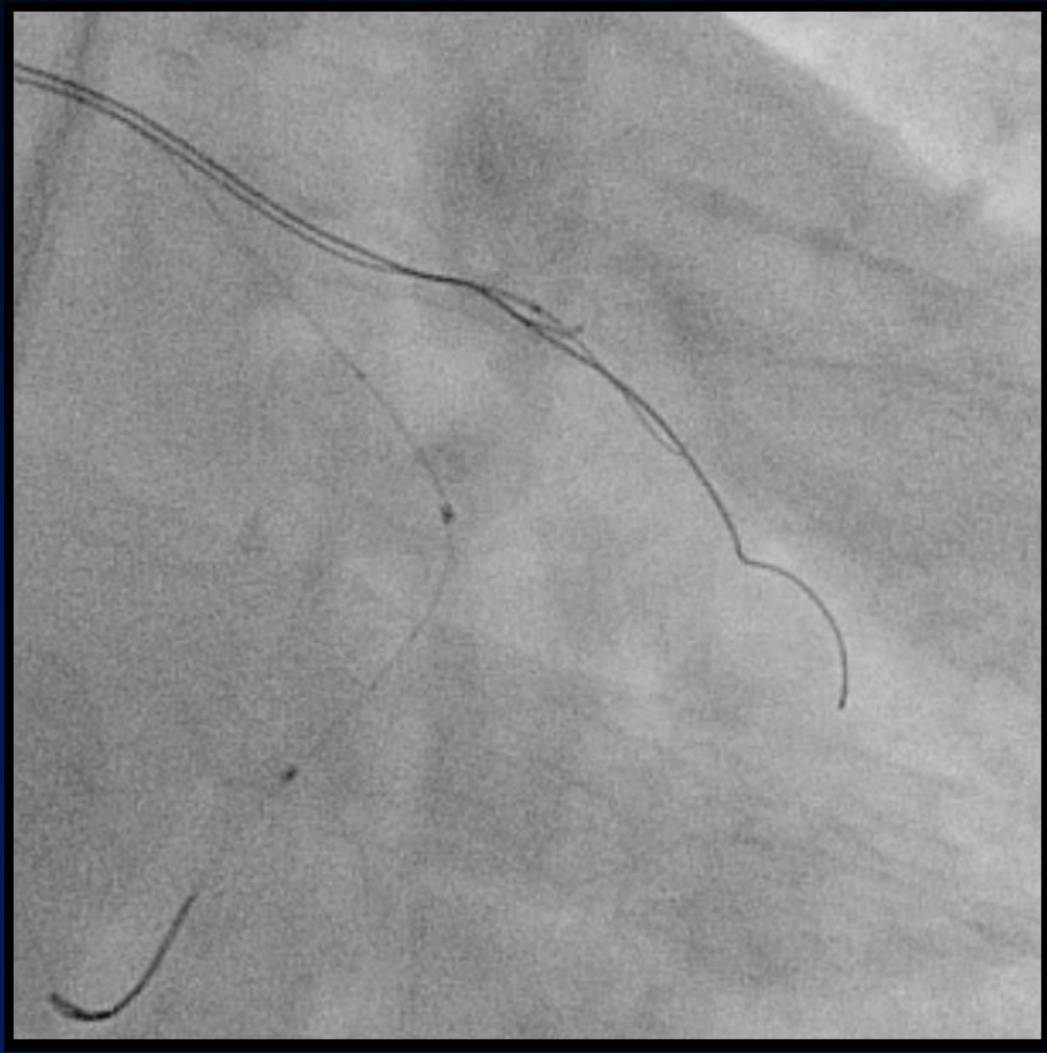
Reposition of Stingray balloon and...



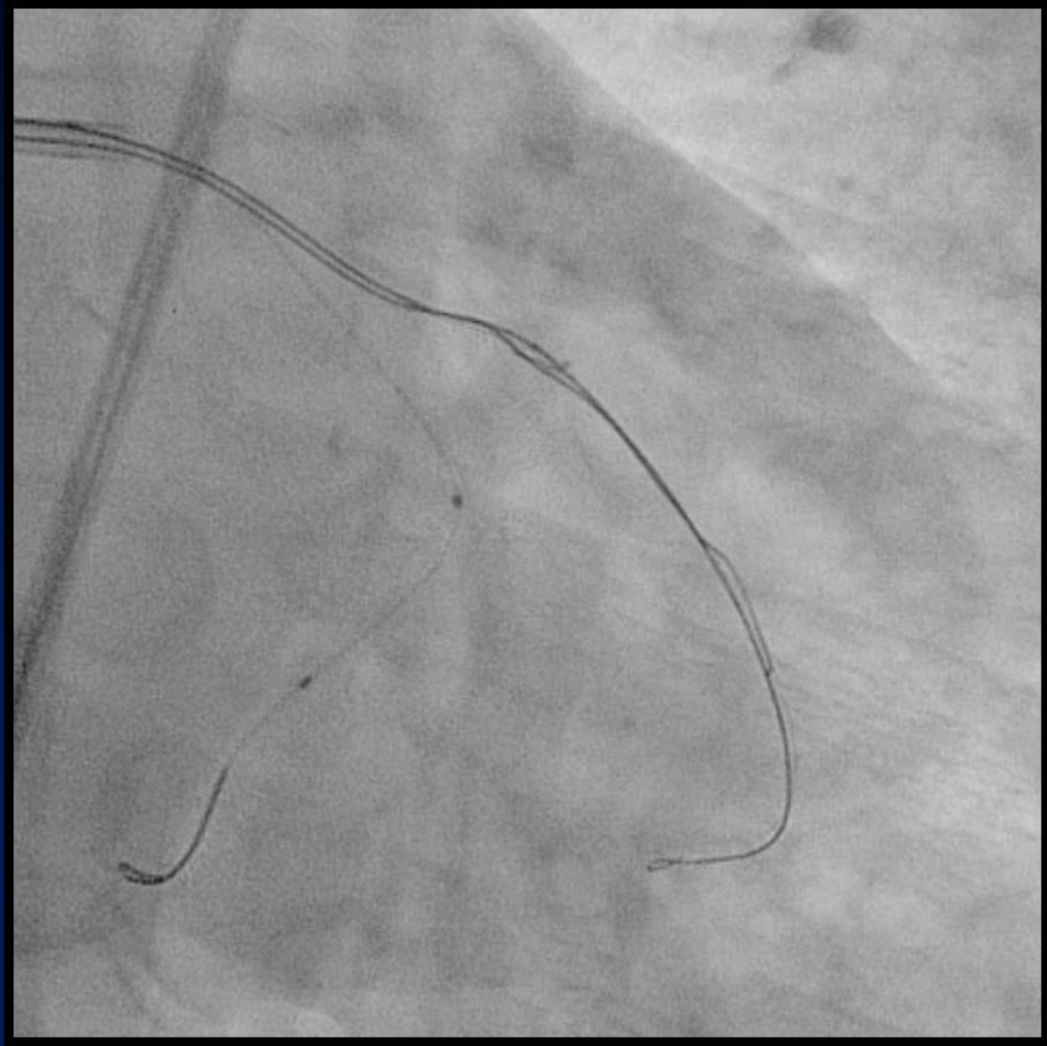
Deep puncture with reshaped Stingray GW



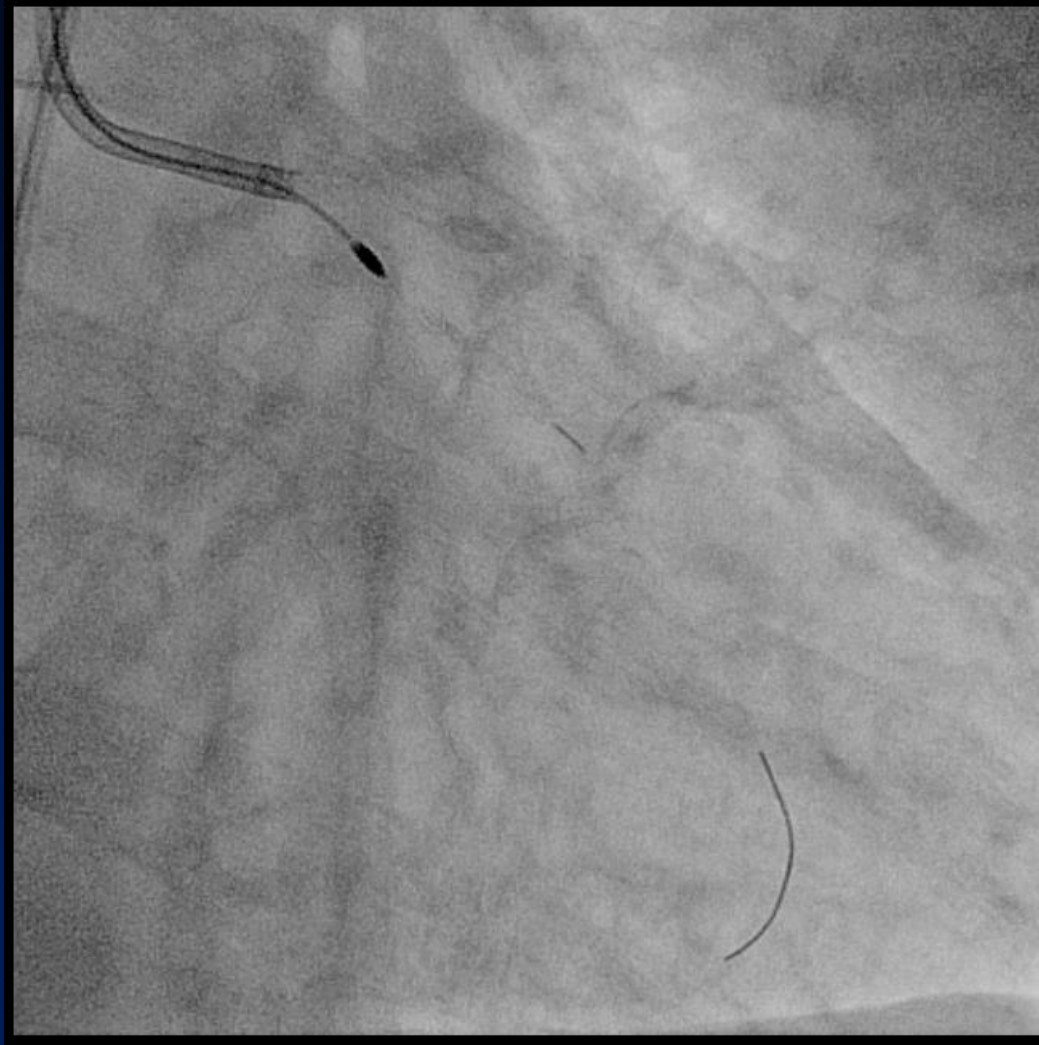
Changing GW to Fielder XT



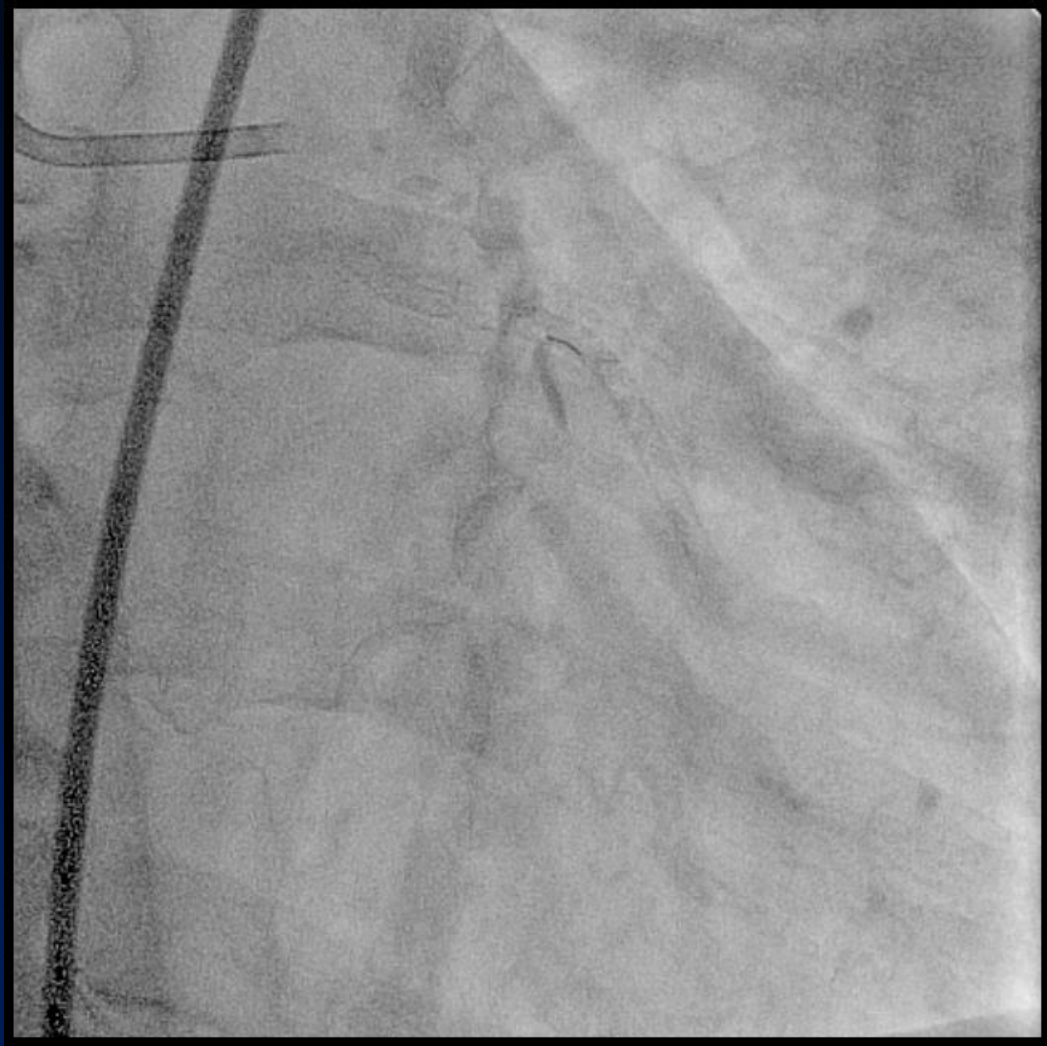
Successful re-entry procedure



1.25 mm Rotablator



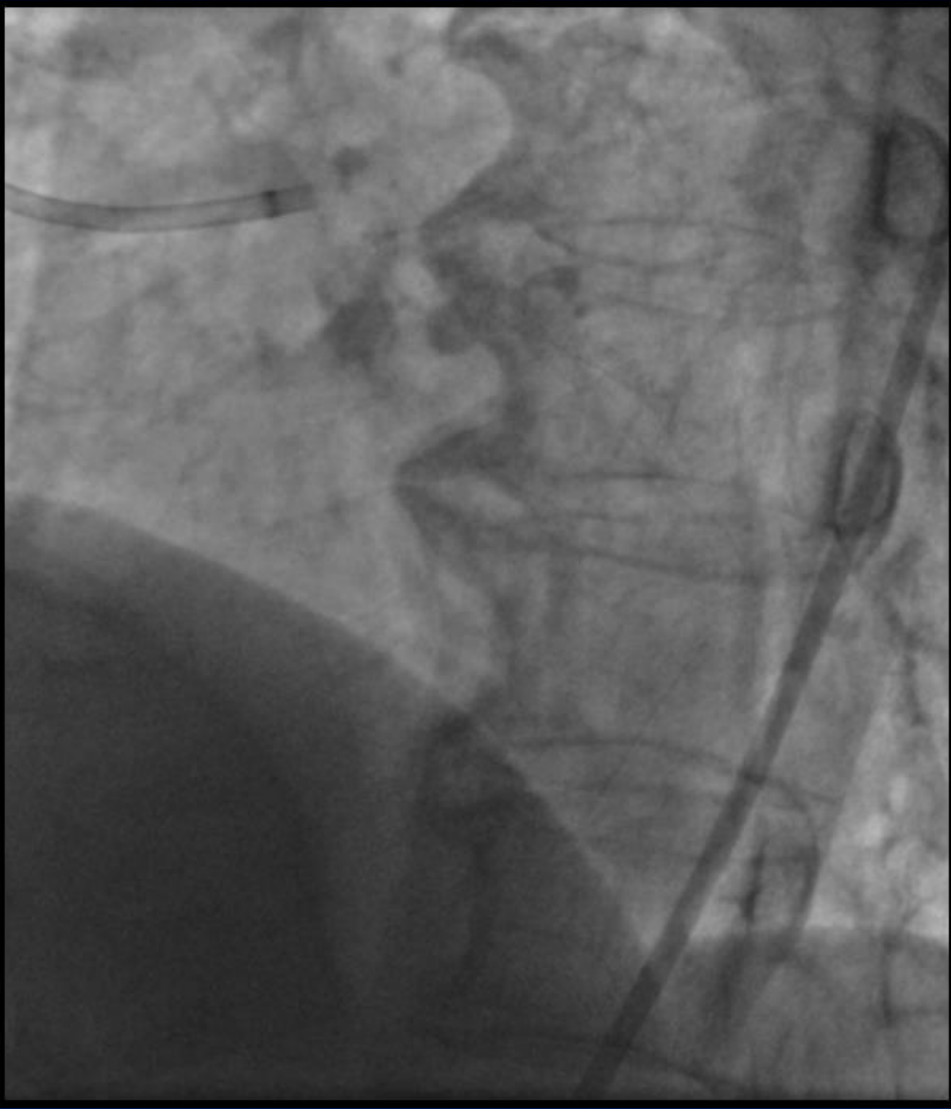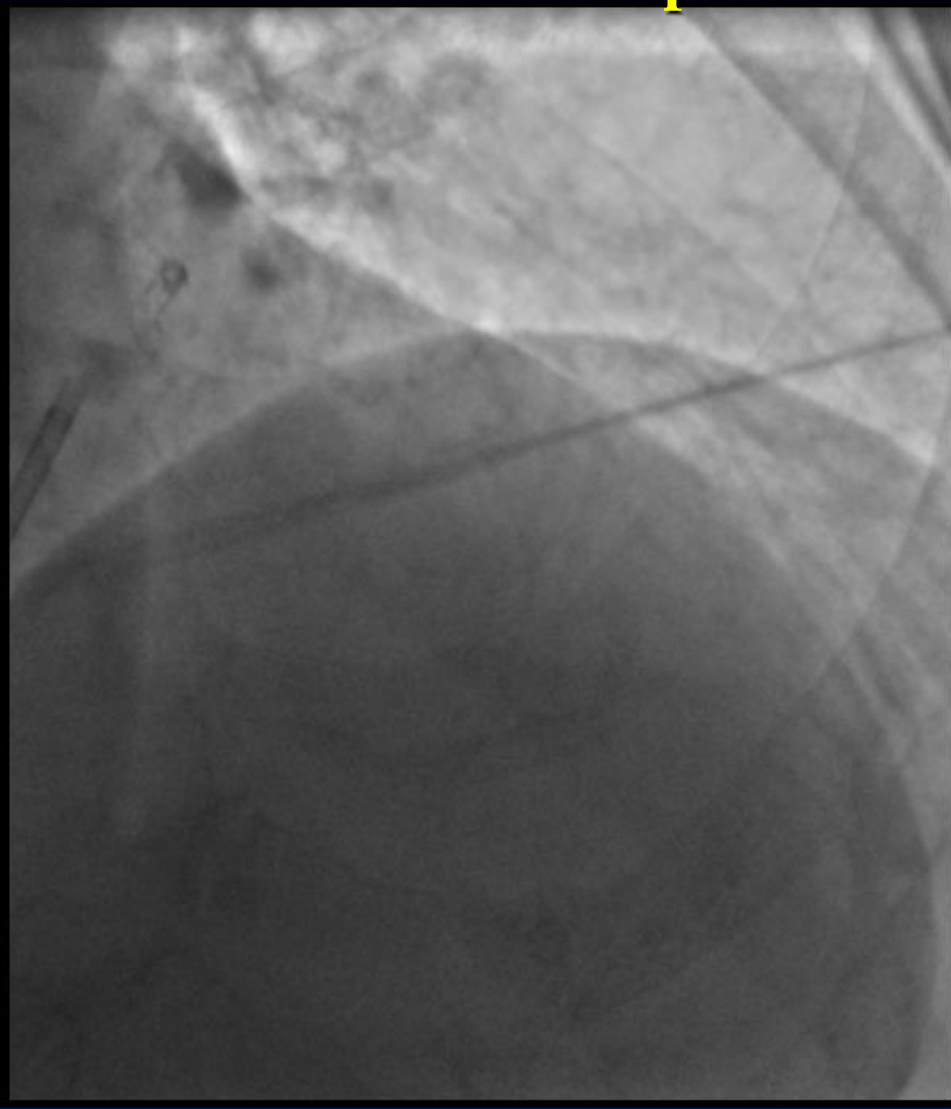
Final angiogram

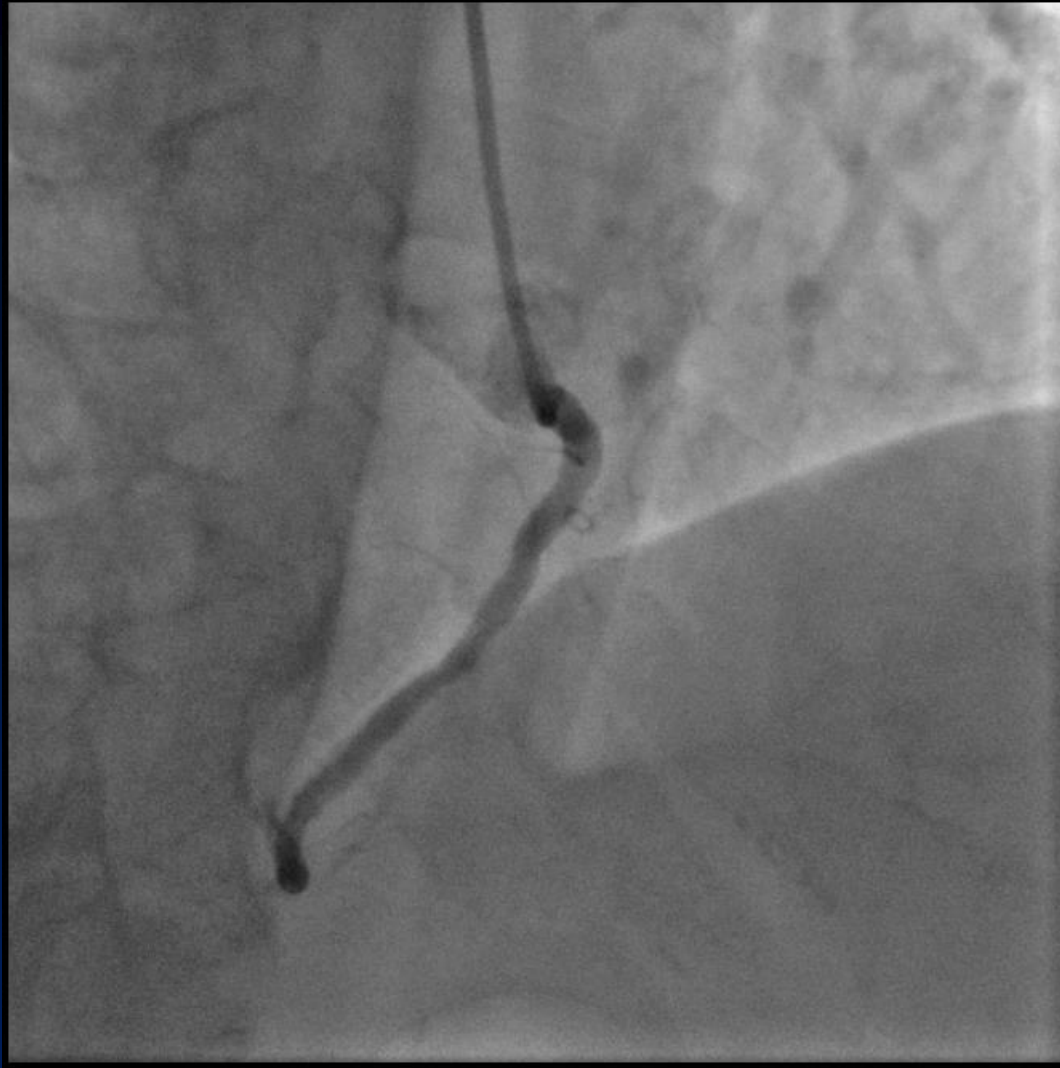

Tips and Tricks of Bridge Point System

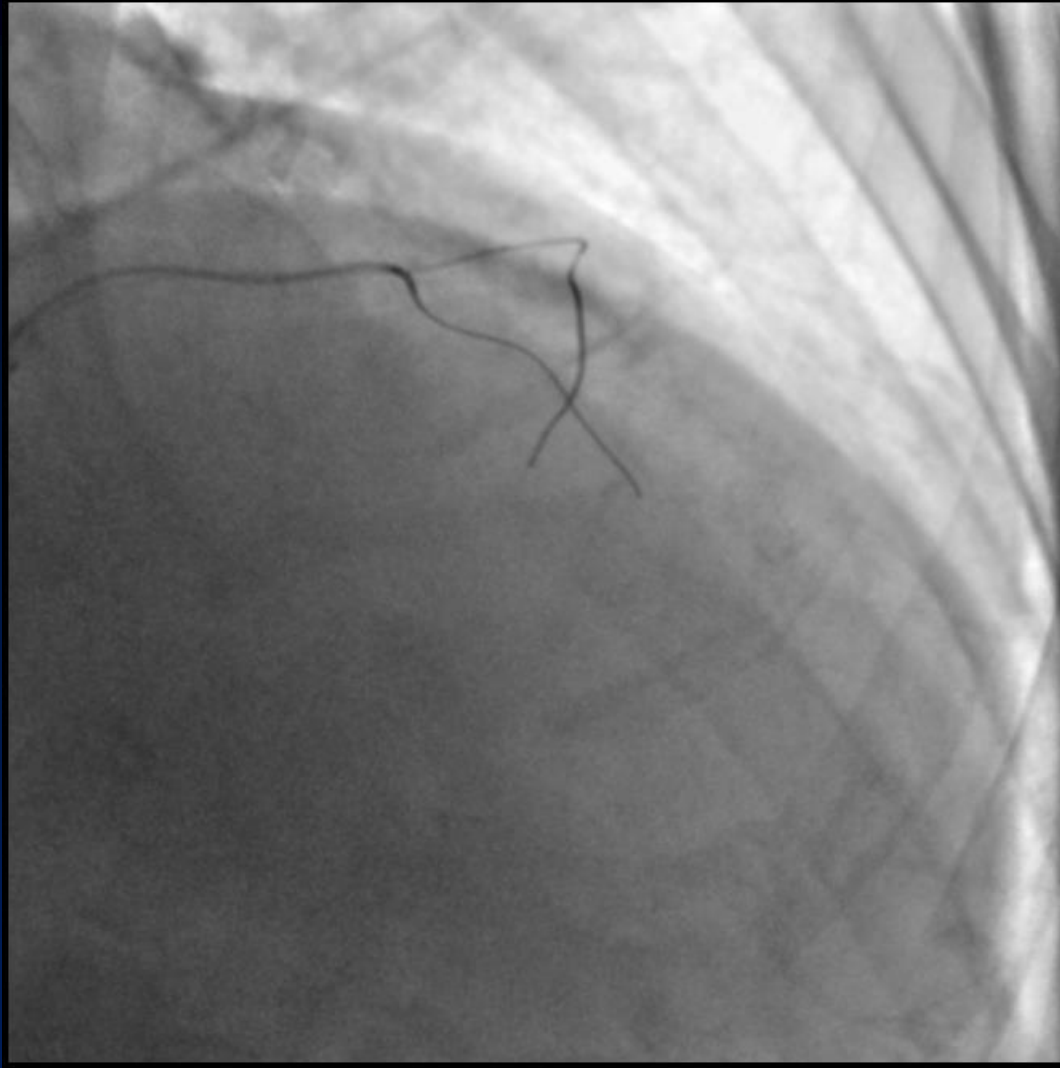
- ◆ Wire change after puncturing
- ◆ Deep puncturing
- ◆ Stingray wire reshaping

1st Attempt for LAD-CTO: Bail-out Use

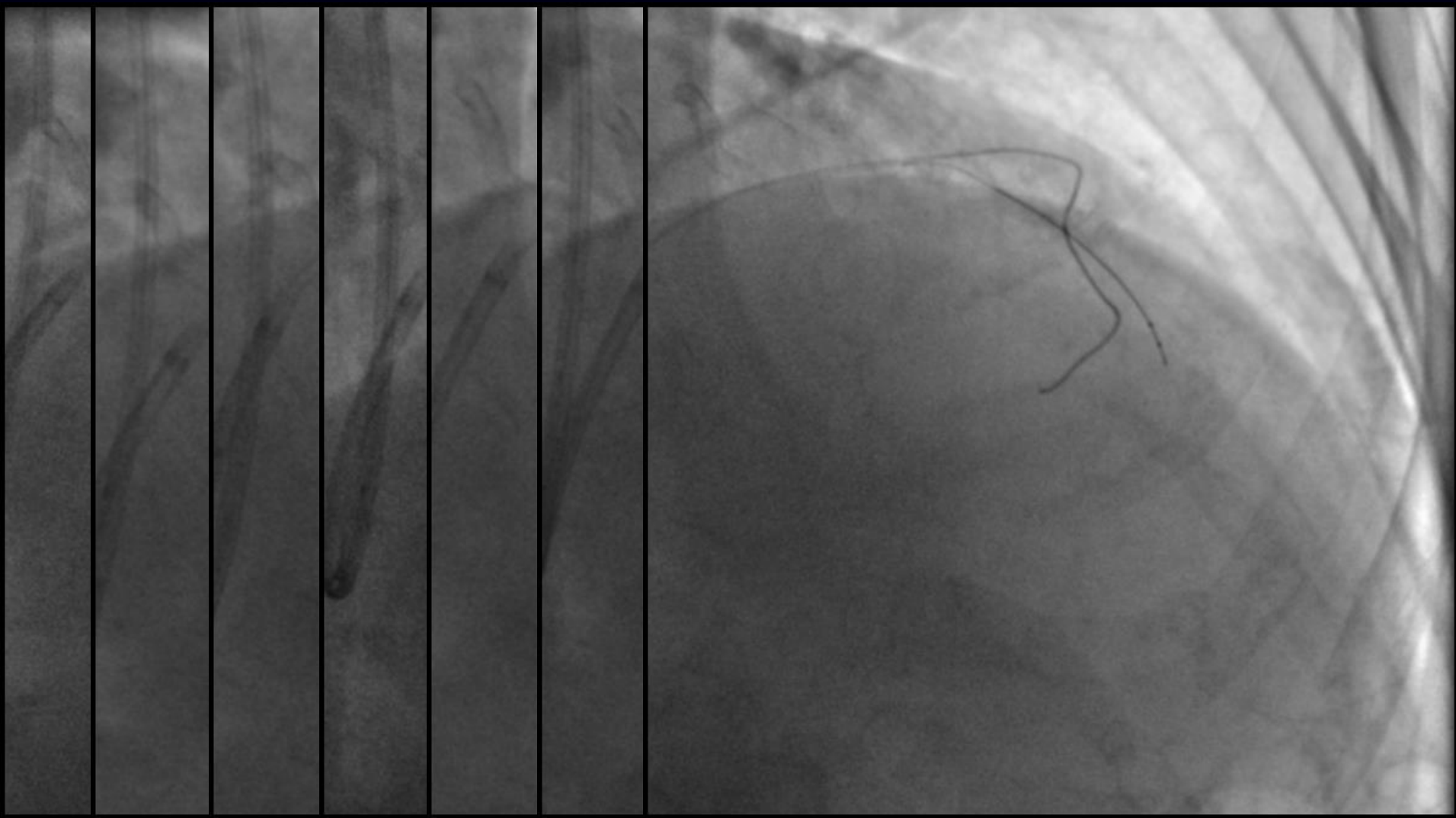




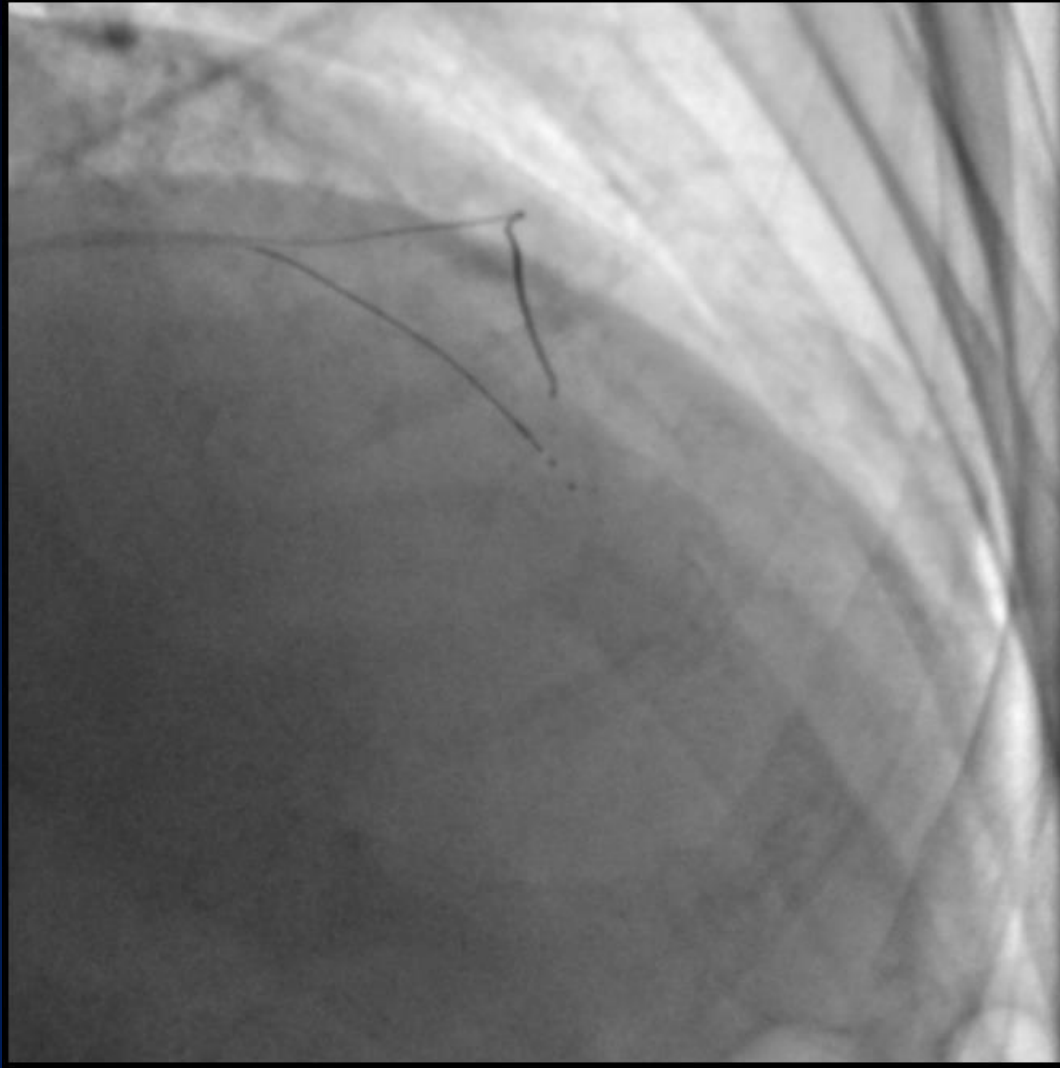No promising retrograde channel...



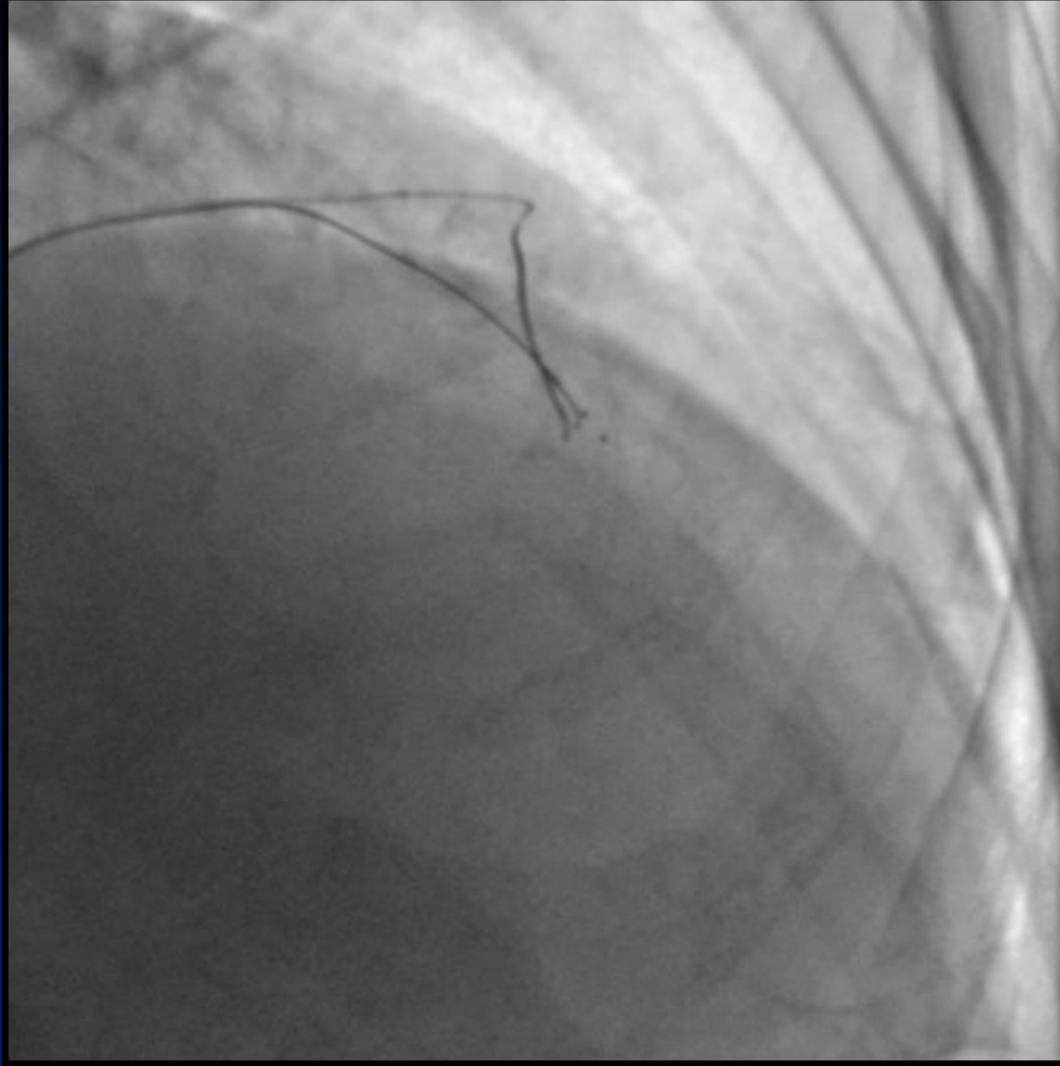
*Antegrade subintimal tracking...
Corsair, Crossboss could not be advanced...*



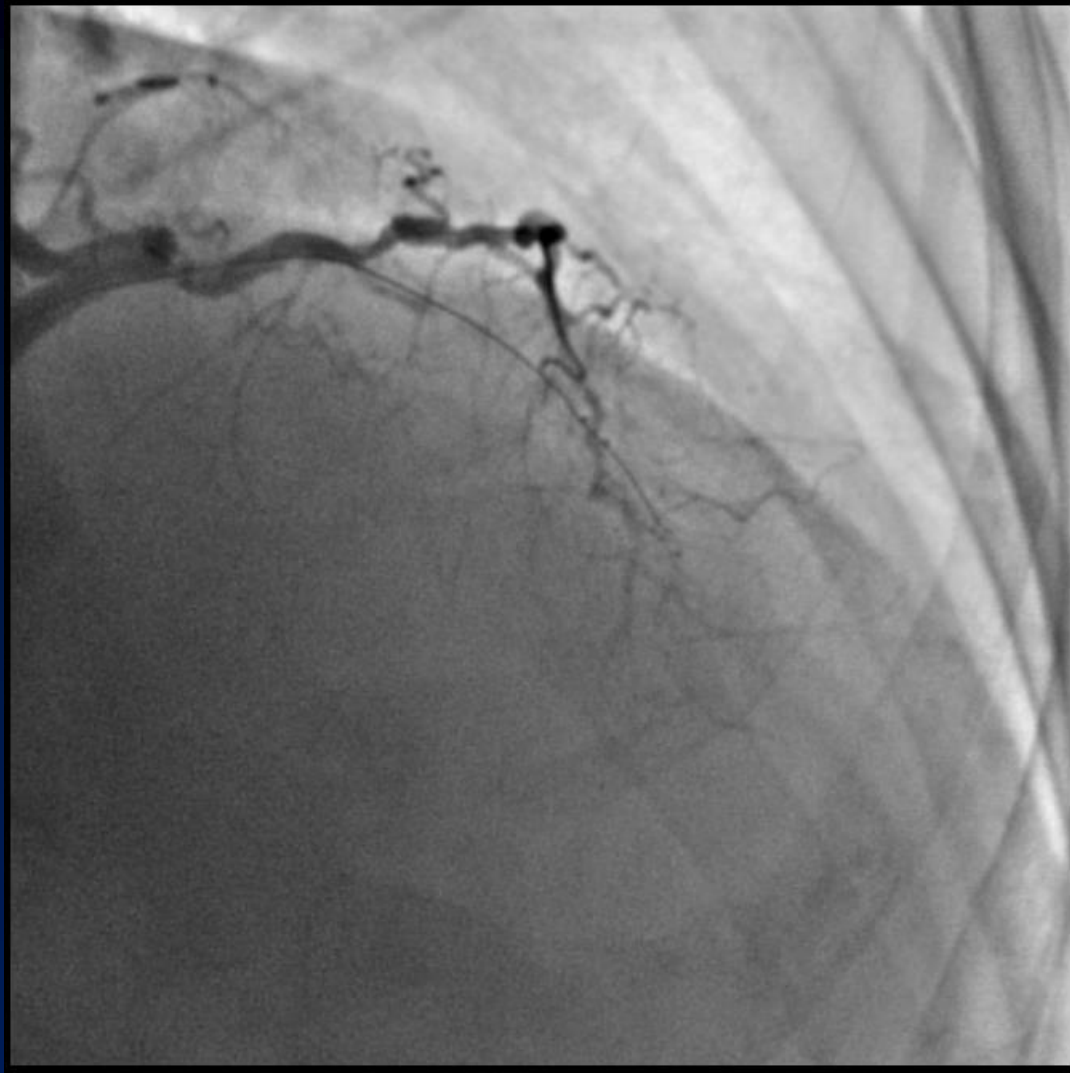1.25mm ballooning 2.0mm Still coronary balloon could be advanced.



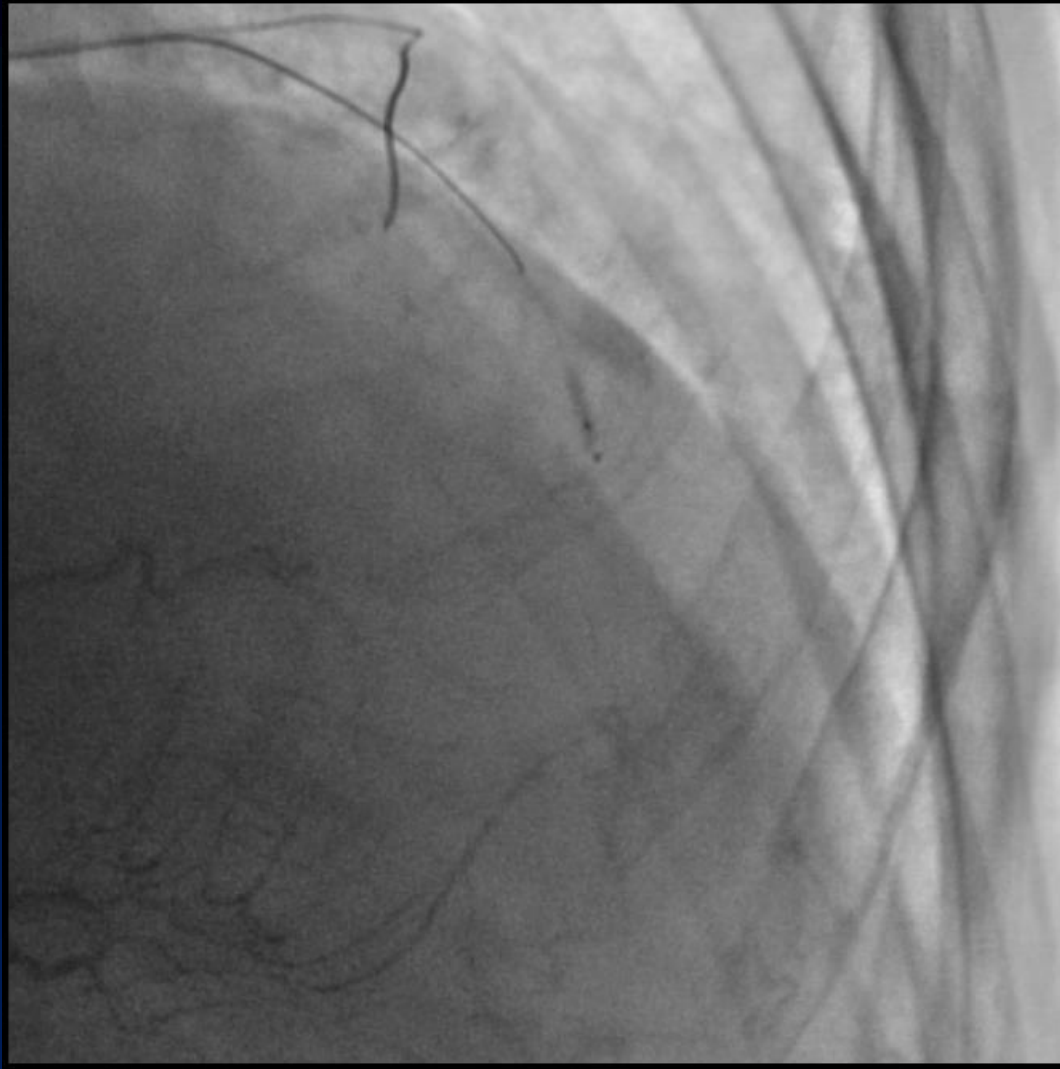Maybe we should go down...



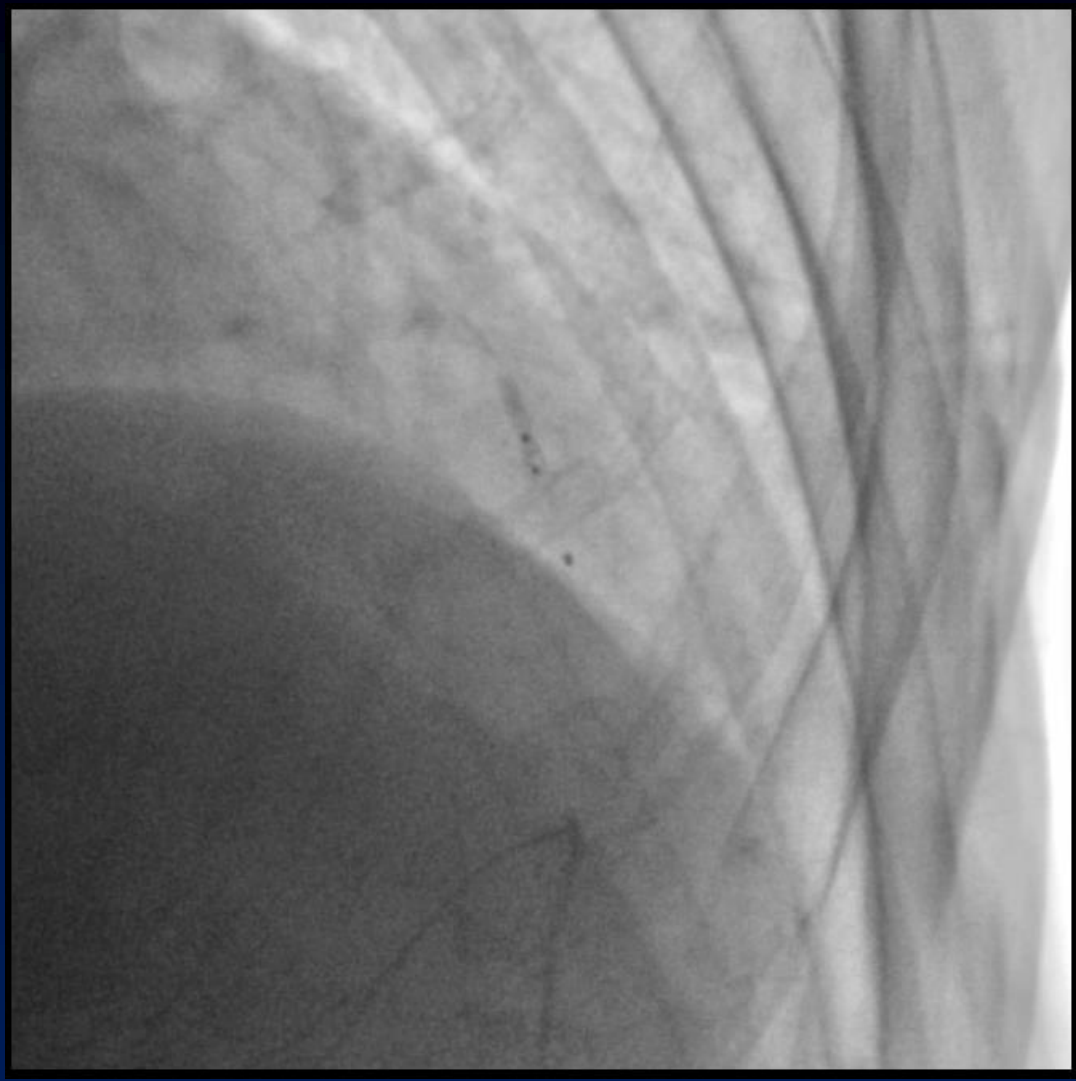
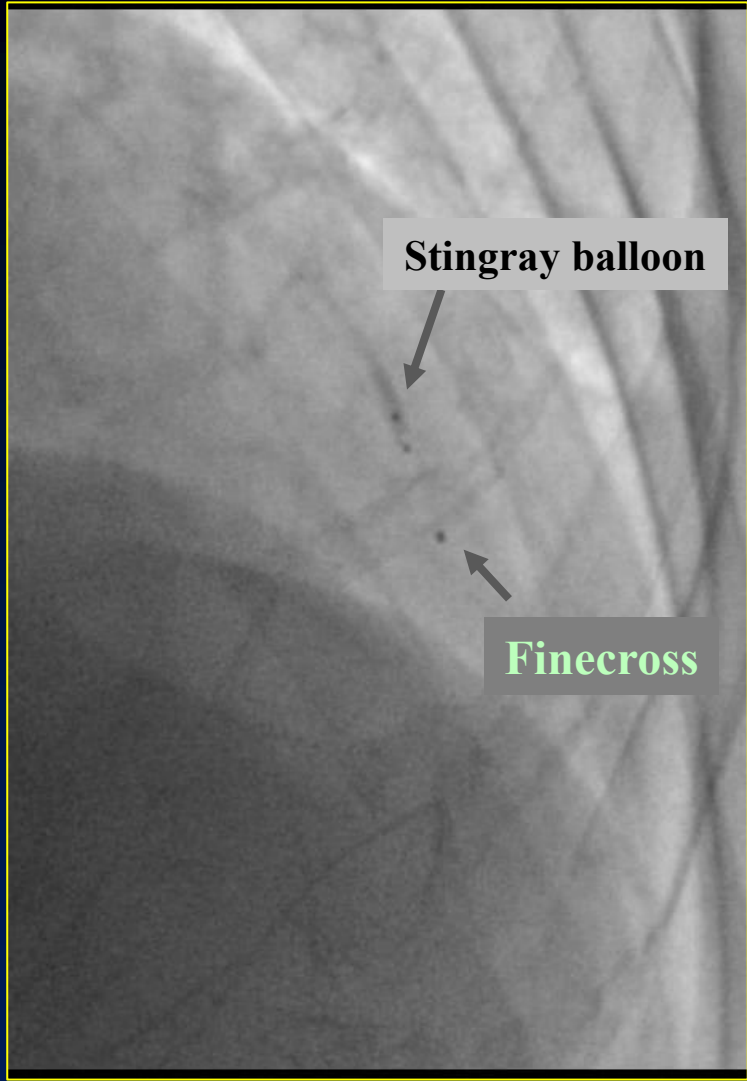
Punctured...



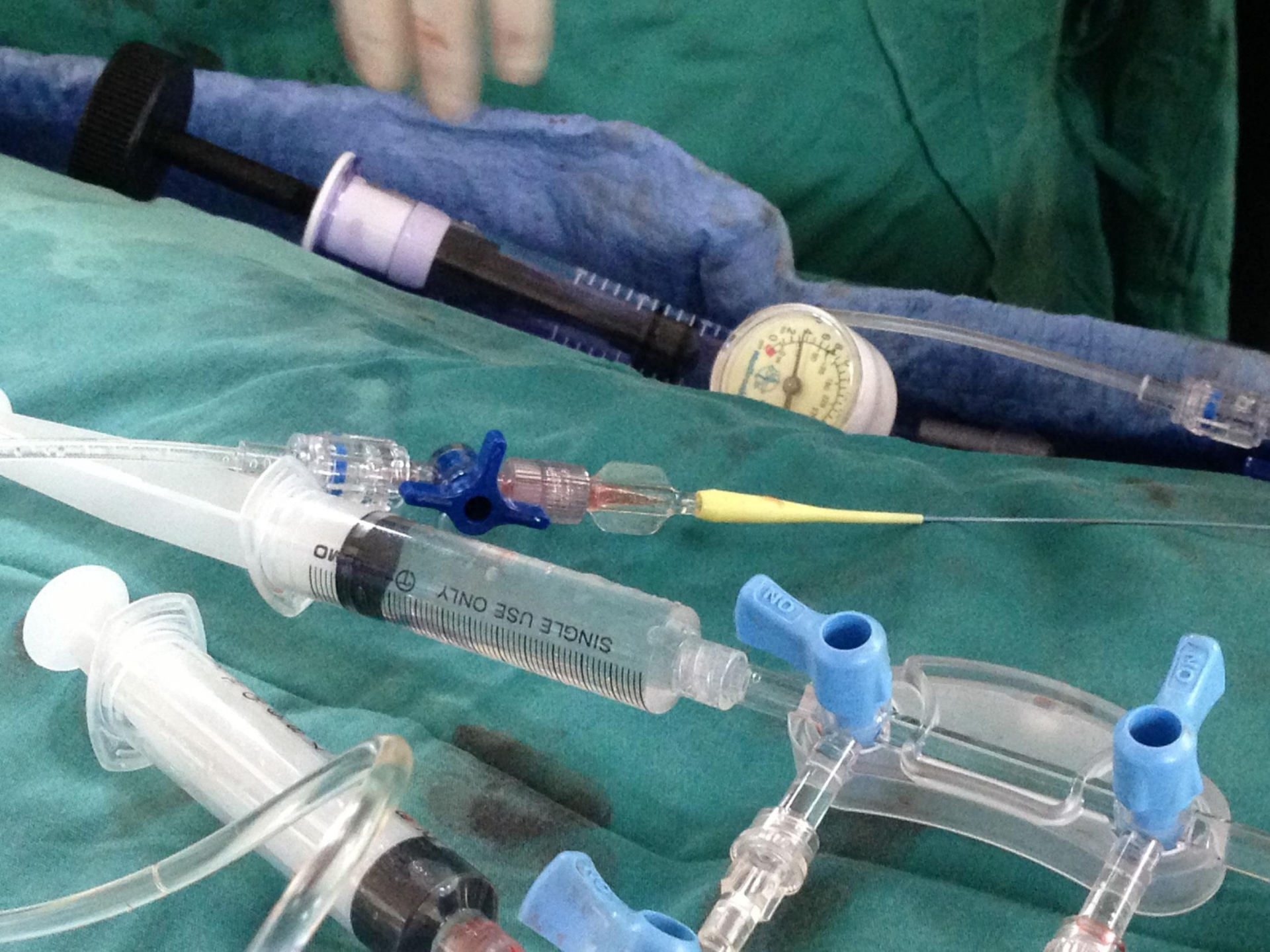*Unsuccessful XTR crossing...
Subsequent several puncturing failed...*

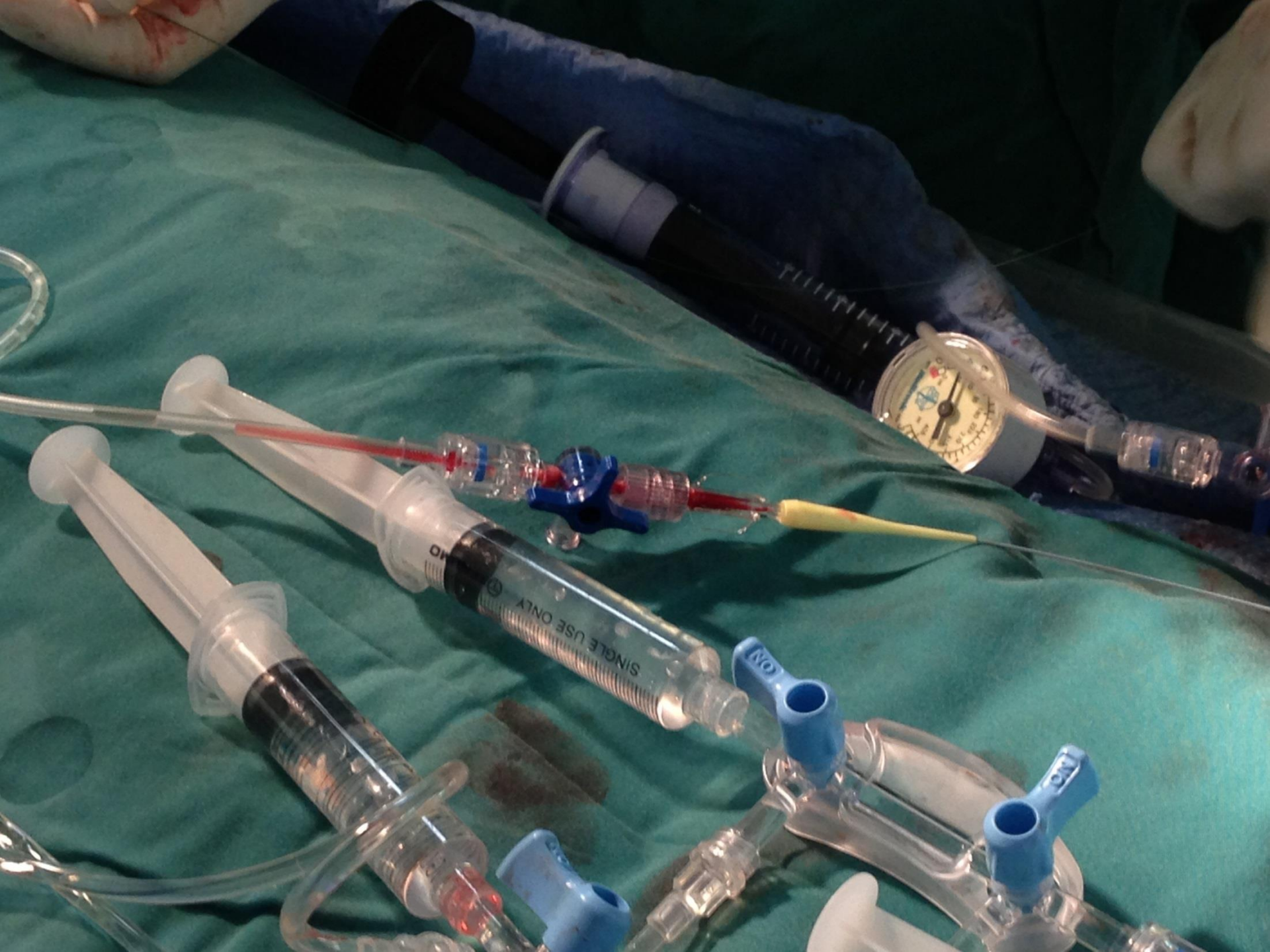

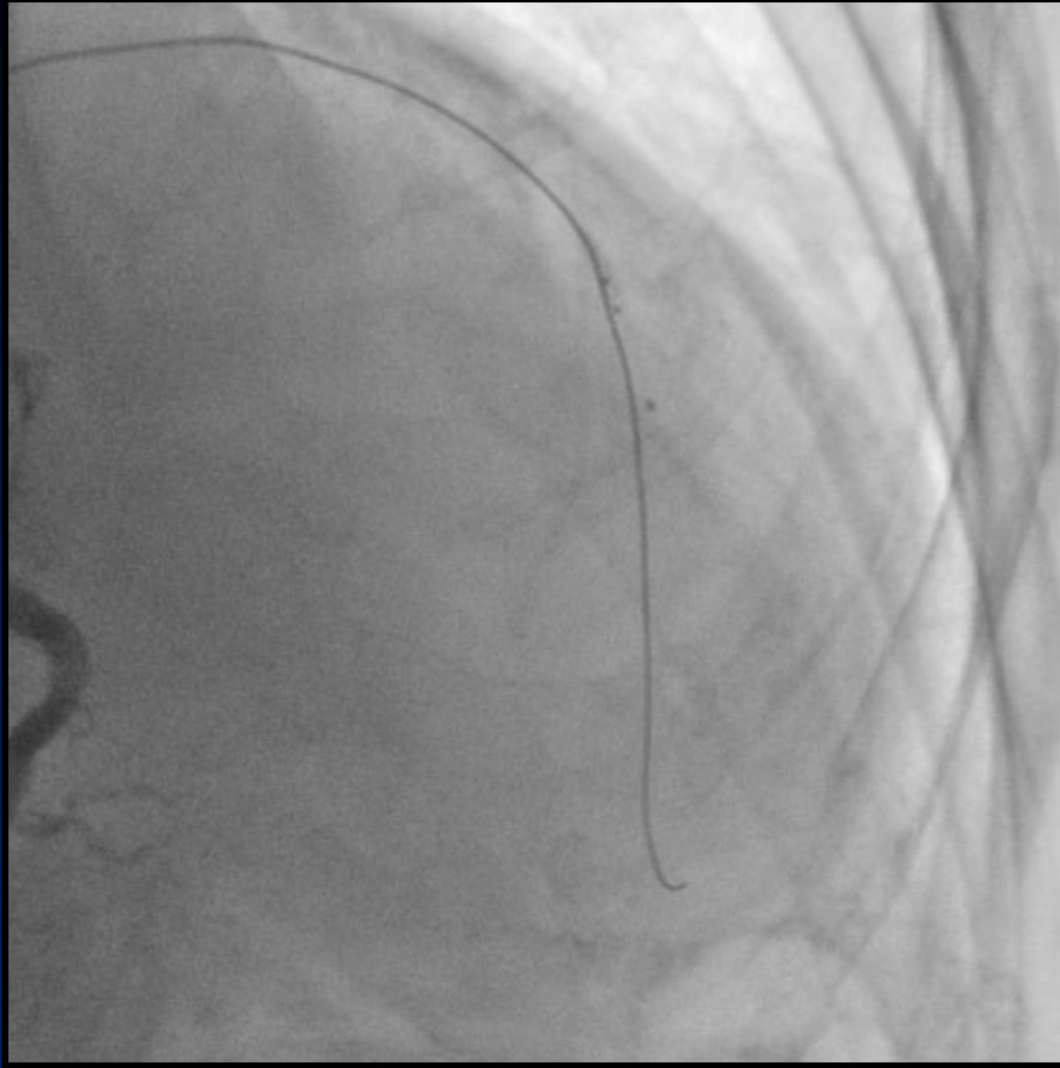
Collapsed distal lumen due to hematoma



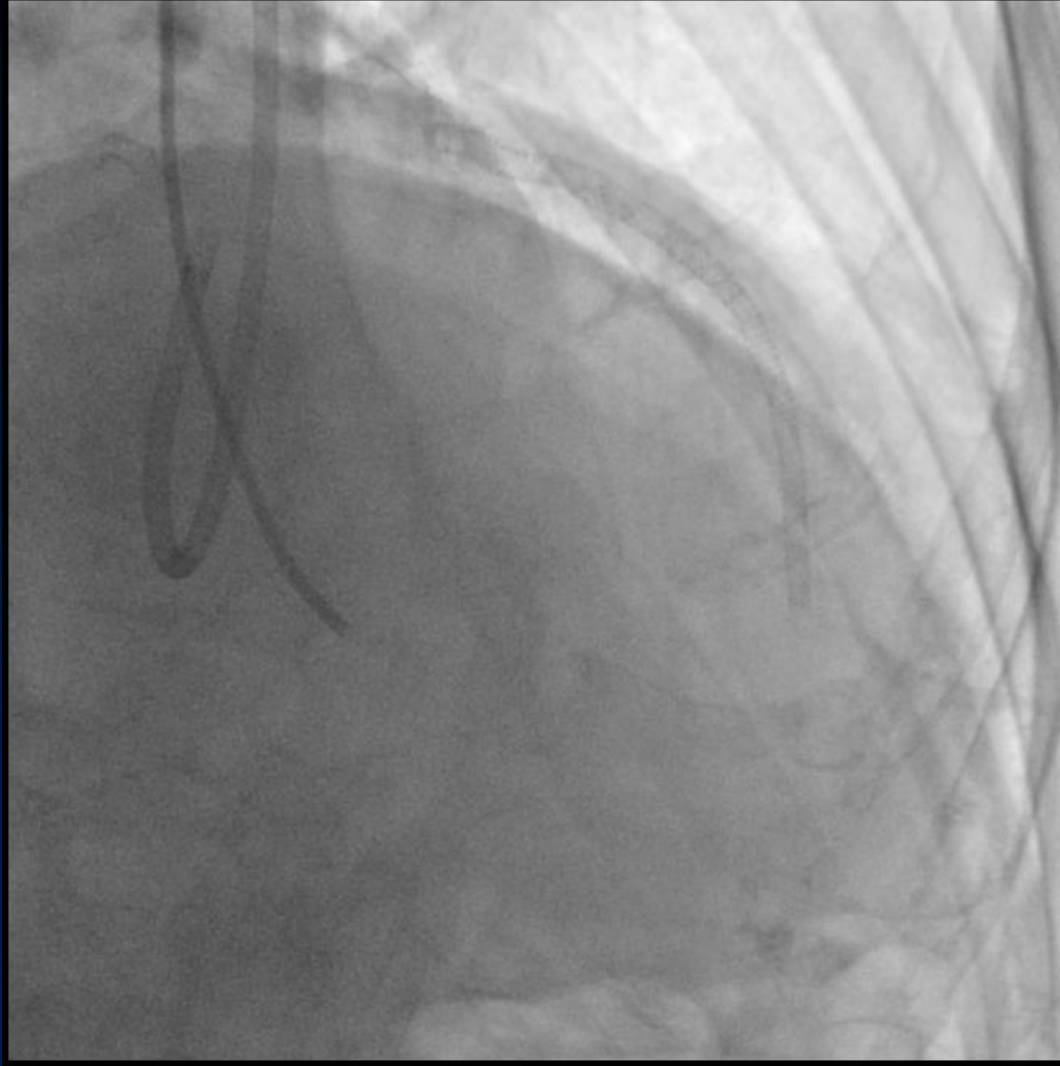
***Straw technique
to reduce hematoma***







Successful crossing with Fielder XTR



Final angiogram

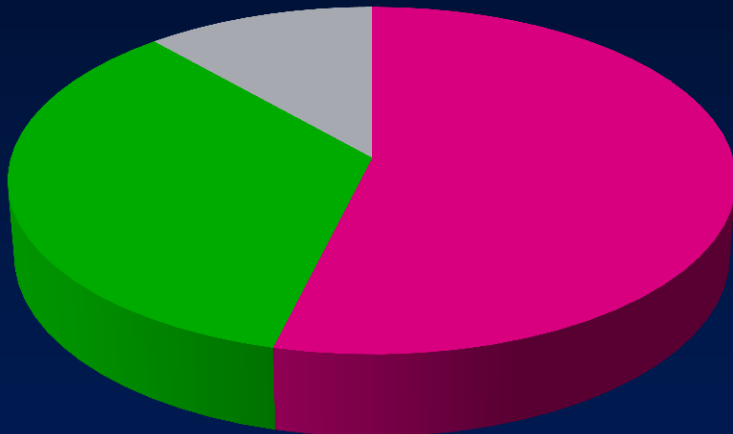
Tips and Tricks of Bridge Point System

- ◆ Wire change after puncturing
- ◆ Deep puncturing
- ◆ Stingray wire reshaping
- ◆ Straw technique

Baseline Lesion Characteristics

(N = 26)

Target vessel



■ RCA ■ LAD ■ LCx

Reattempt 15 (57%)

Calcification 15 (57%)

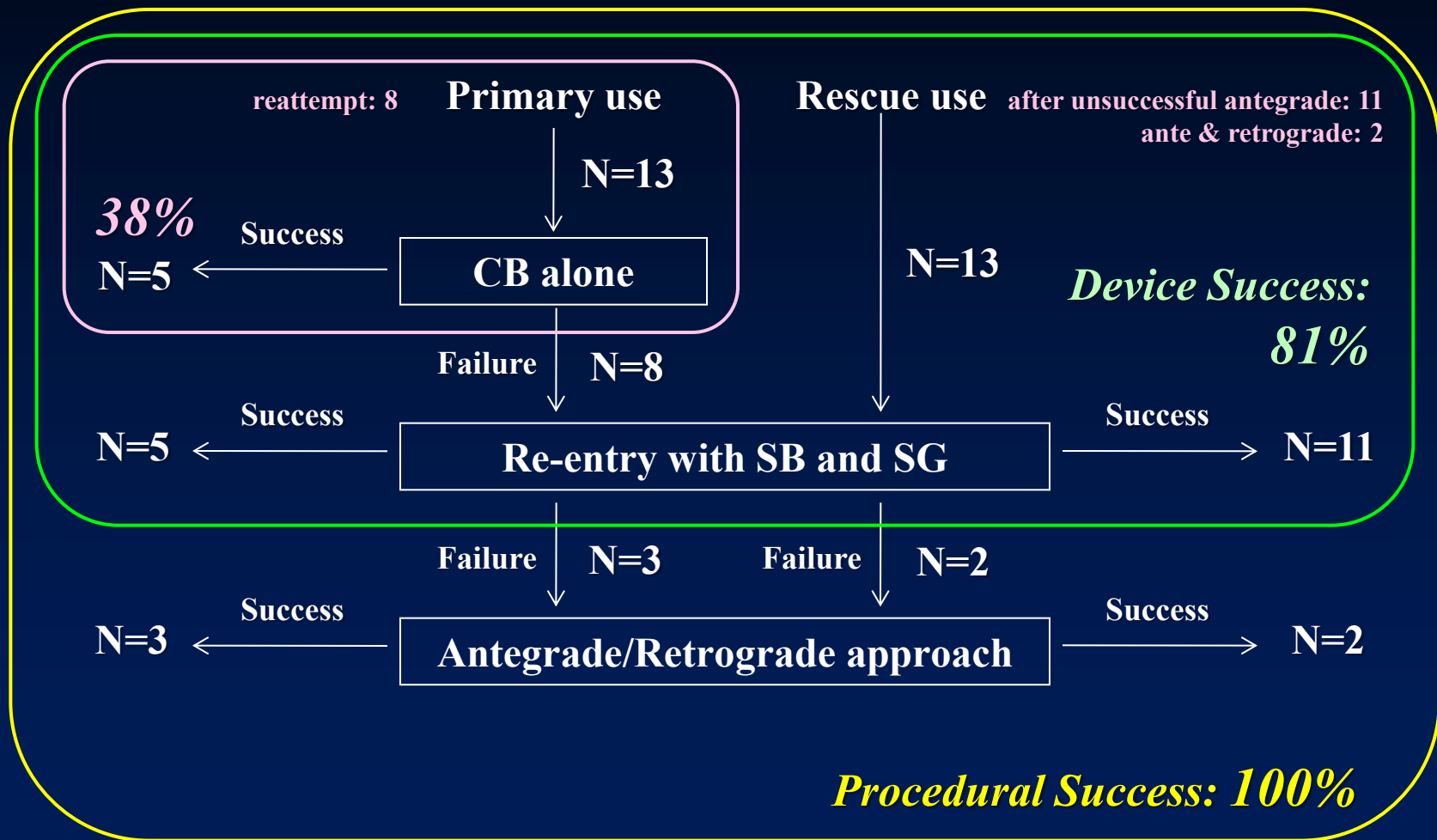
Occlusion length >20 mm 17 (65%)

Reference diameter < 3 mm 14 (54%)

No stump or abrupt occlusion 18 (69%)

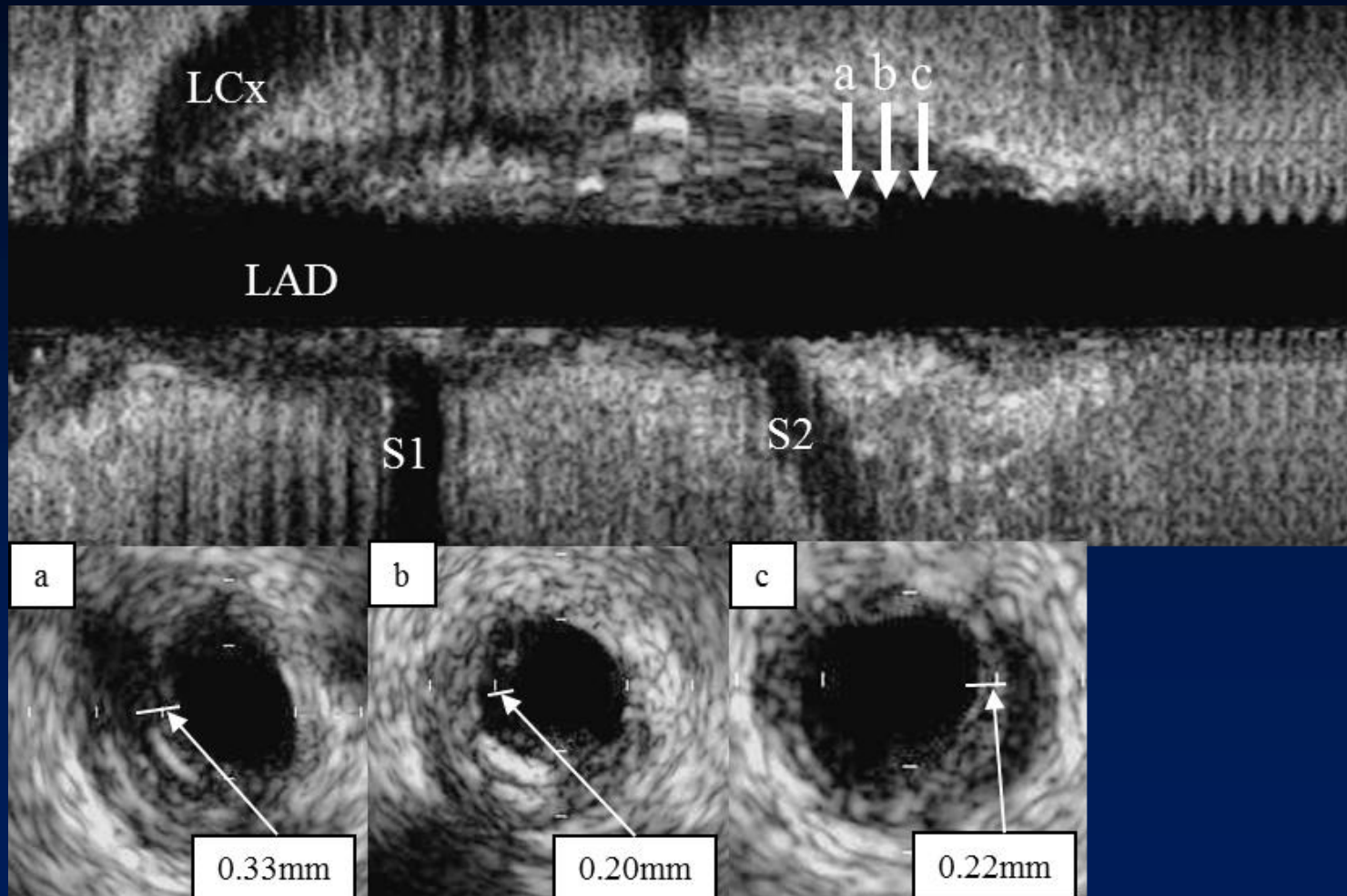
Procedural Sequence and Outcomes

(N = 26)



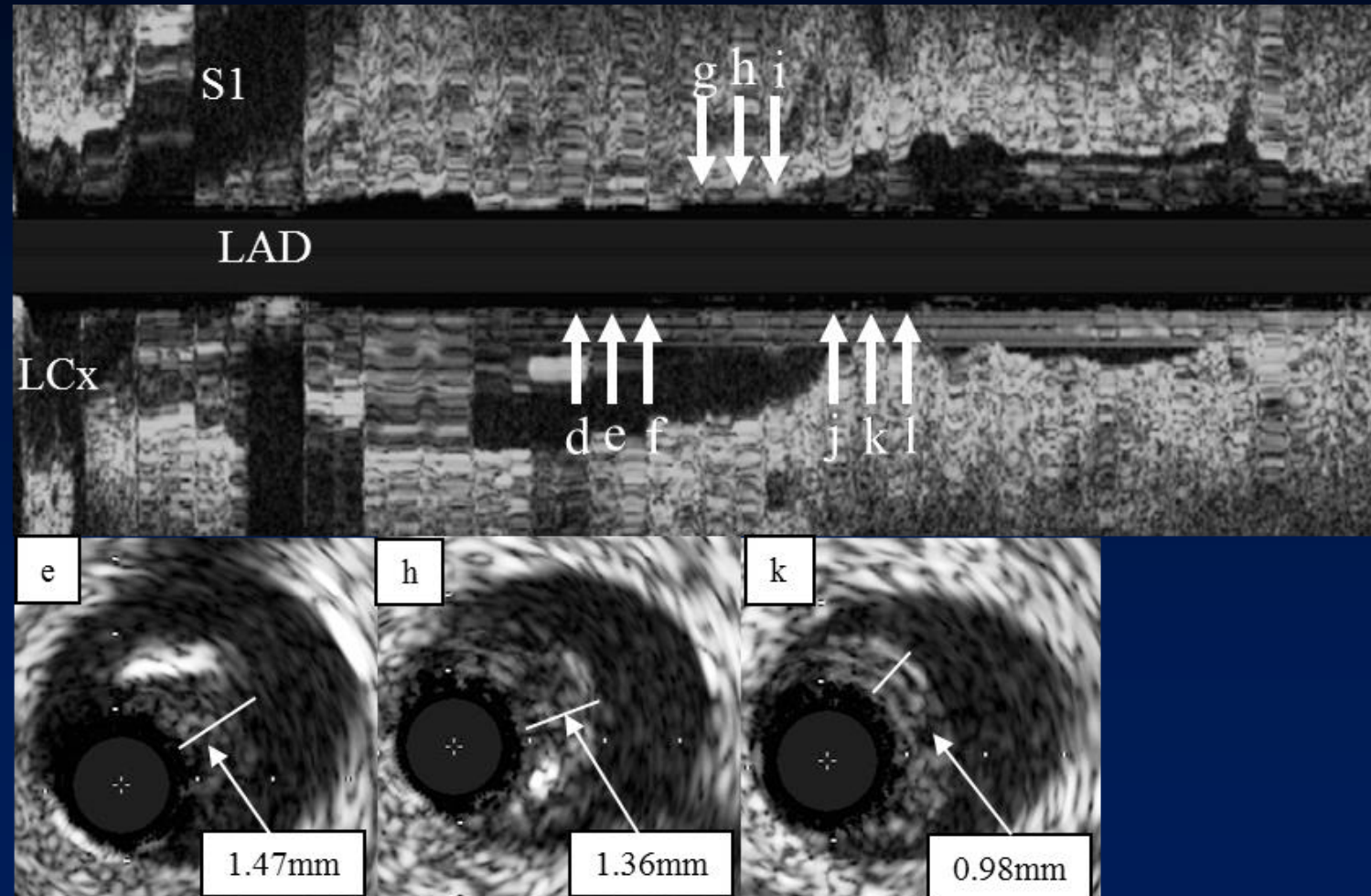
(JIC 2012;24:396-400)

IVUS Examination < Successful Re-entry >



IVUS Examination < Unsuccessful Re-entry >

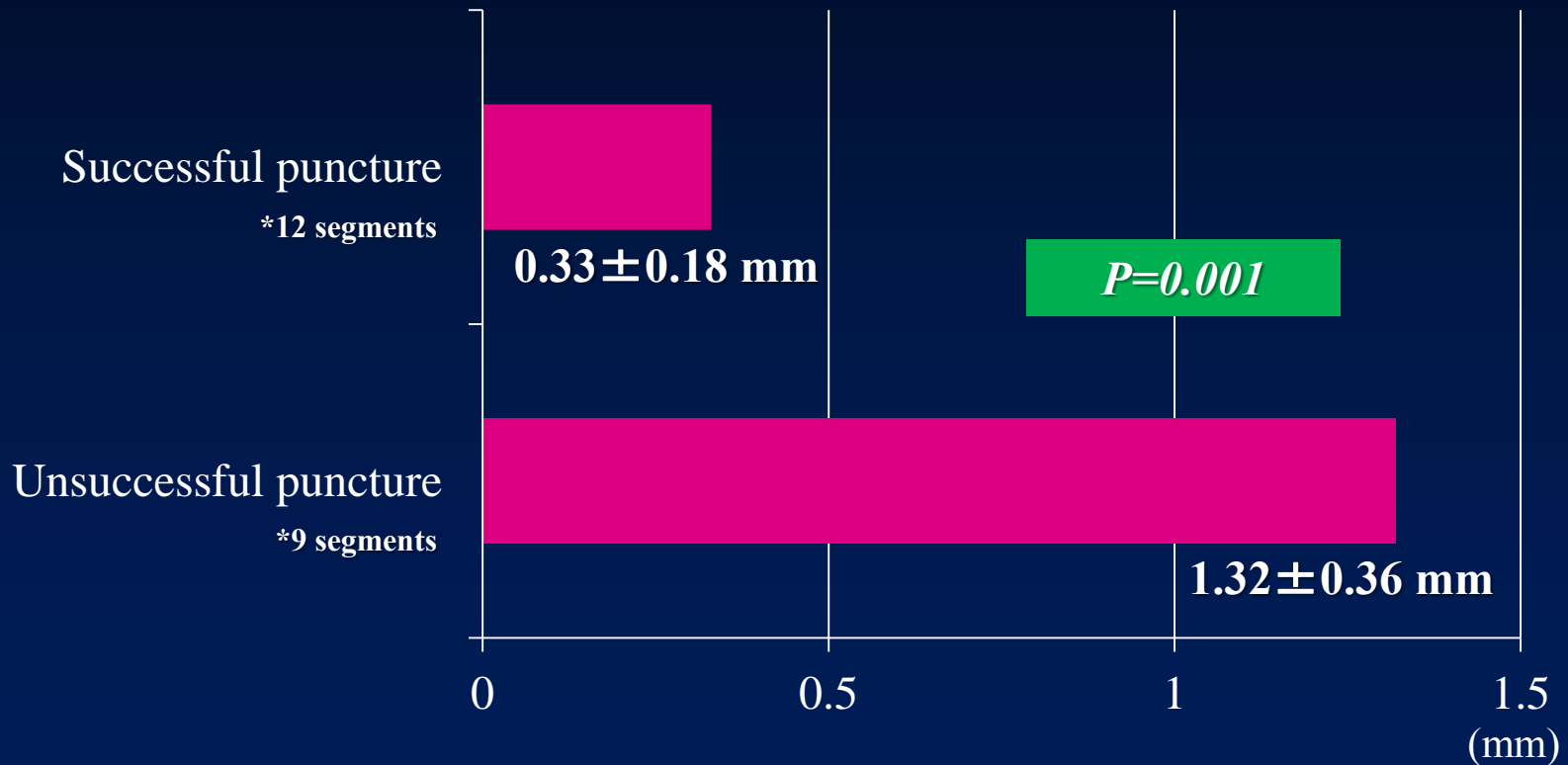
*after successful retrograde approach



IVUS Examination

< Successful vs. Unsuccessful Re-entry >

Intimal thickness

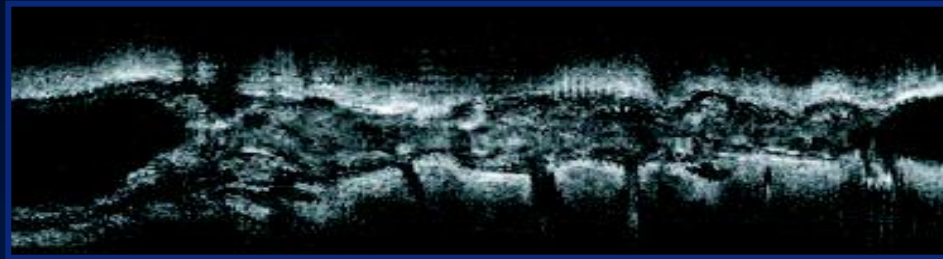


(JIC 2012;24:396-400)

Summary of Bridge Point System

- ◆ A promising option by the antegrade manner
- ◆ In the antegrade approach, it may replace parallel wiring or IVUS guided intimal tracking depending on the case or procedural situation.
- ◆ In the case without the chance of retrograde approach, it must be a last resort for successful recanalization.
- ◆ We have to wait for long-term results of cases treated by Stingray system.

15th CTO Club



June 20-21, 2014, Nagoya, Japan

www.cct.gr.jp/ctoclub