

Mitral Loop Cerclage

a catheter-based treatment of functional mitral regurgitation (CSTV)

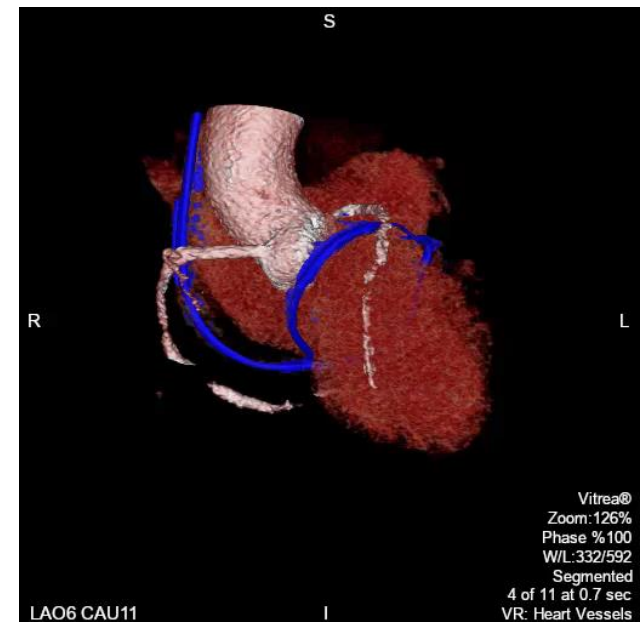
June-Hong Kim, MD, PhD

Professor, Director of Cardiology

Pusan National University Yangsan Hospital

Yangsan, South Korea

junehongk@gmail.com

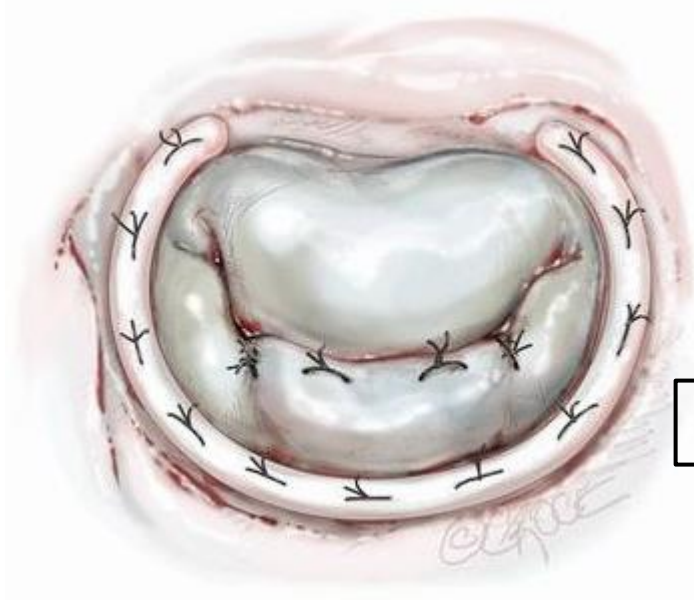

Disclosure of 'Conflict of Interest'

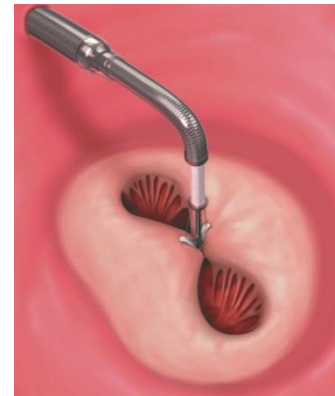- Equity: Tau-PNU Medical Co. of Pusan National University
- Intellectual Property of 'Mitral Cerclage ' and 'Mitral Loop Cerclage' that are assigned to NIH, or Tau-PNU or Pusan National University.
- Collaborator with NHLBI Division of Intramural Research (Z01-HL006040)

Transcatheter MV repair

Leaflet correction +
annuloplasty

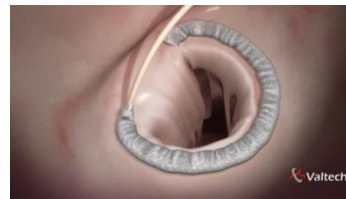


Leaflet correction



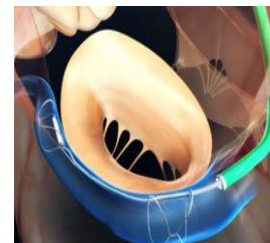
Mitraclip

Direct annuloplasty

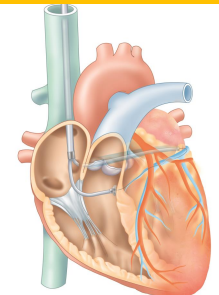


Cardioband

Indirect annuloplasty



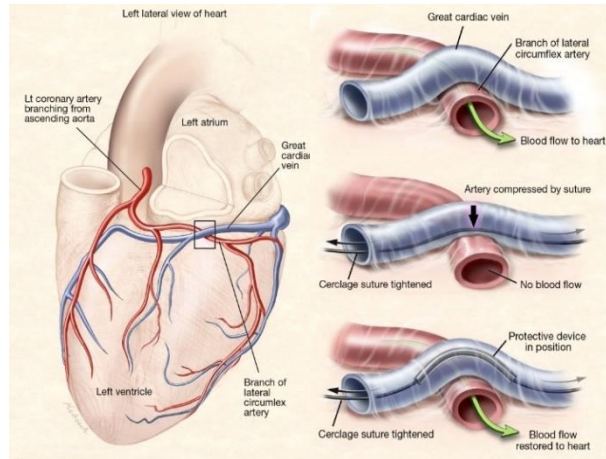
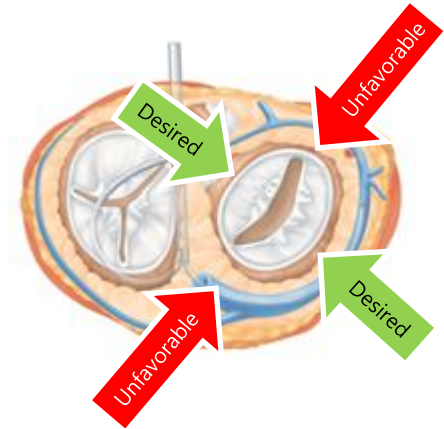
Carillon



Cerclage

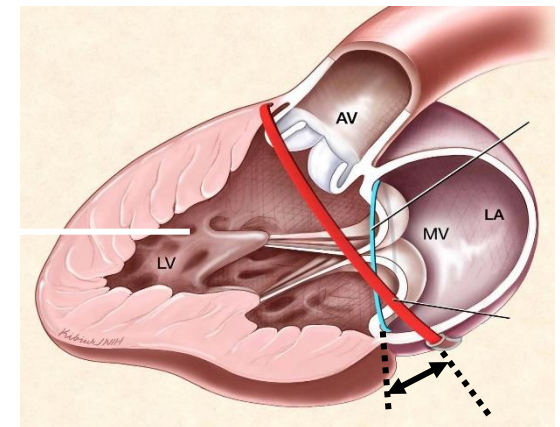
CS approach : limitations and solutions

- 1: hemi-circumferential compression : insufficient
 - Solution: circumferential compression

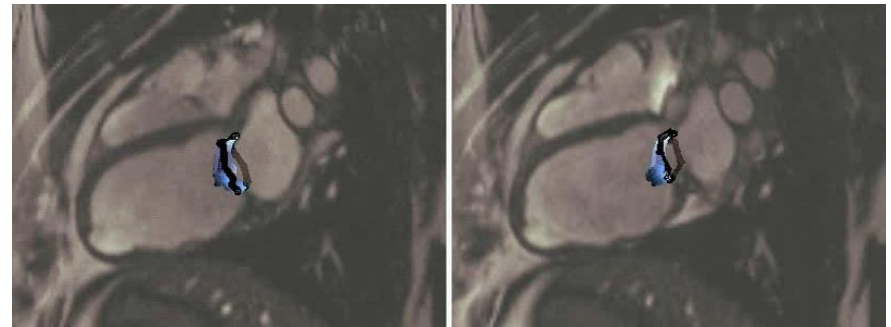
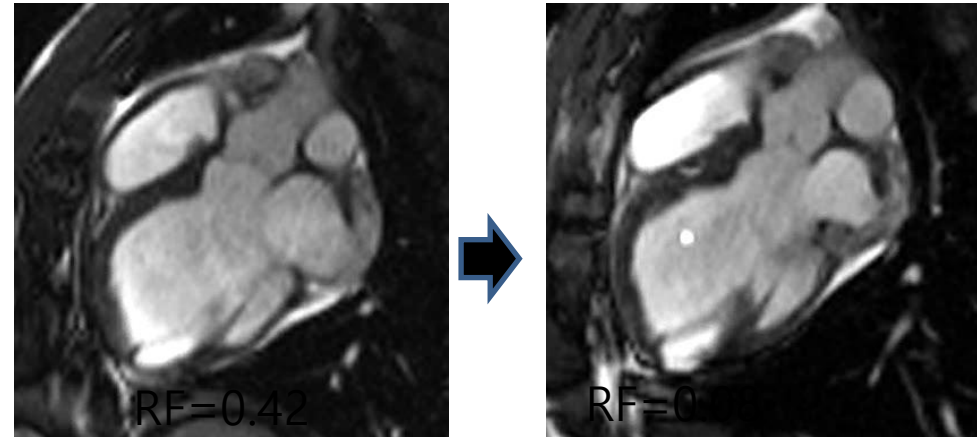
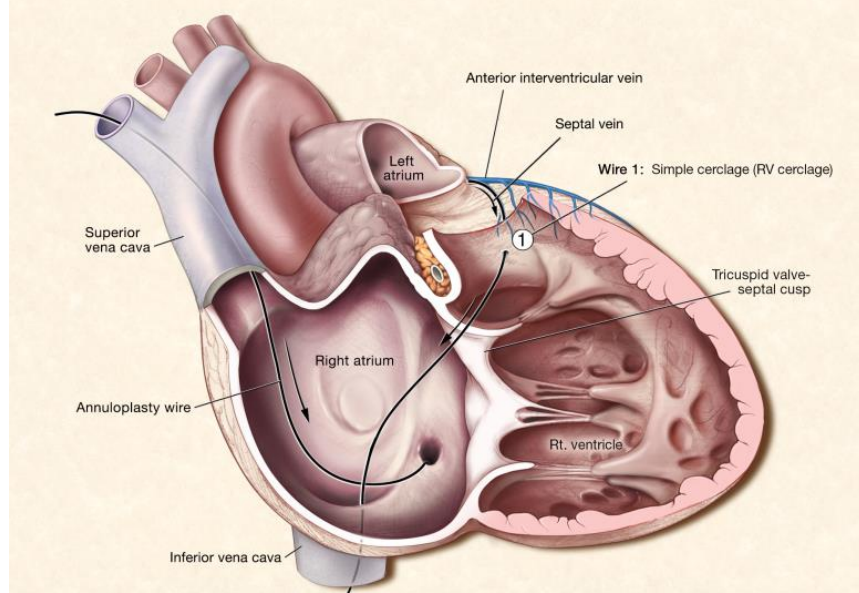
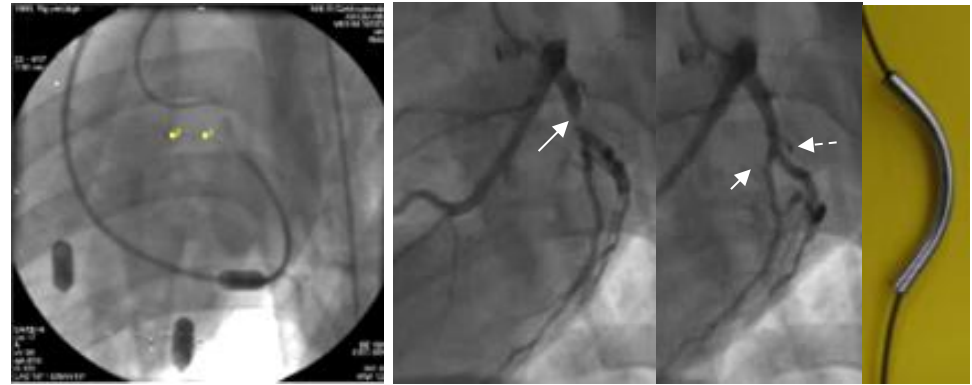
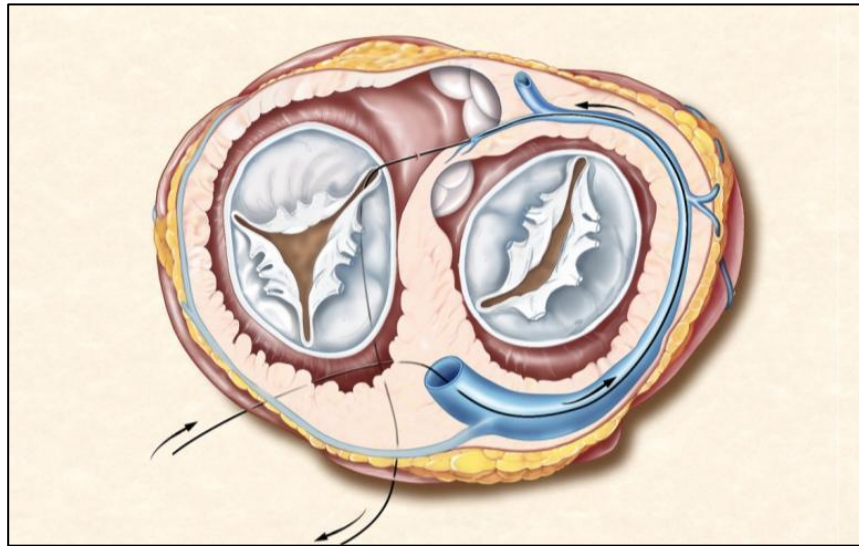


- 2: Coronary artery entrapment
 – Solution: coronary protection

- 3: Coronary sinus far from annulus
 – Solution: "Apical tilt" of plane

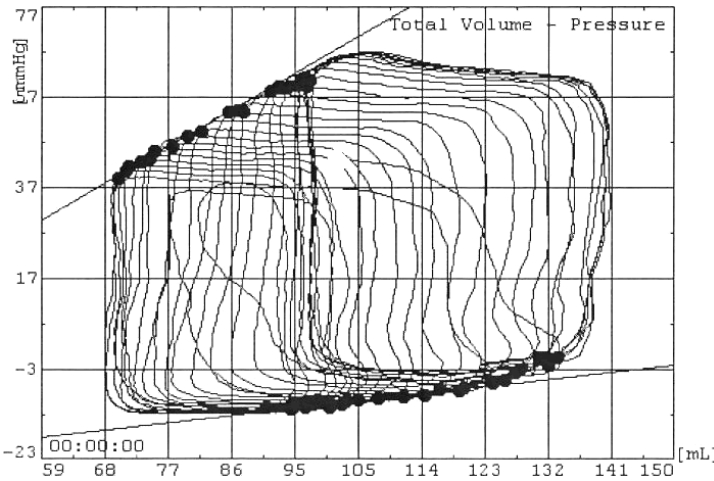


Pre-clinical 'mitral cerclage'

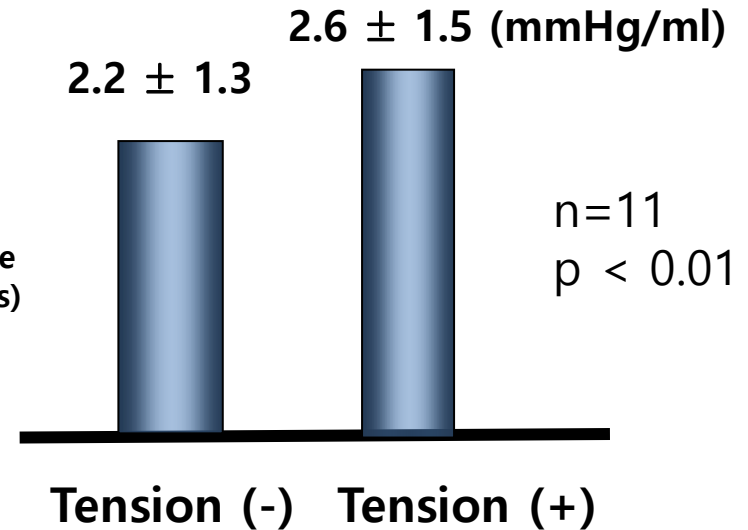


Basal LV squeezing: Is it OK for sick heart?

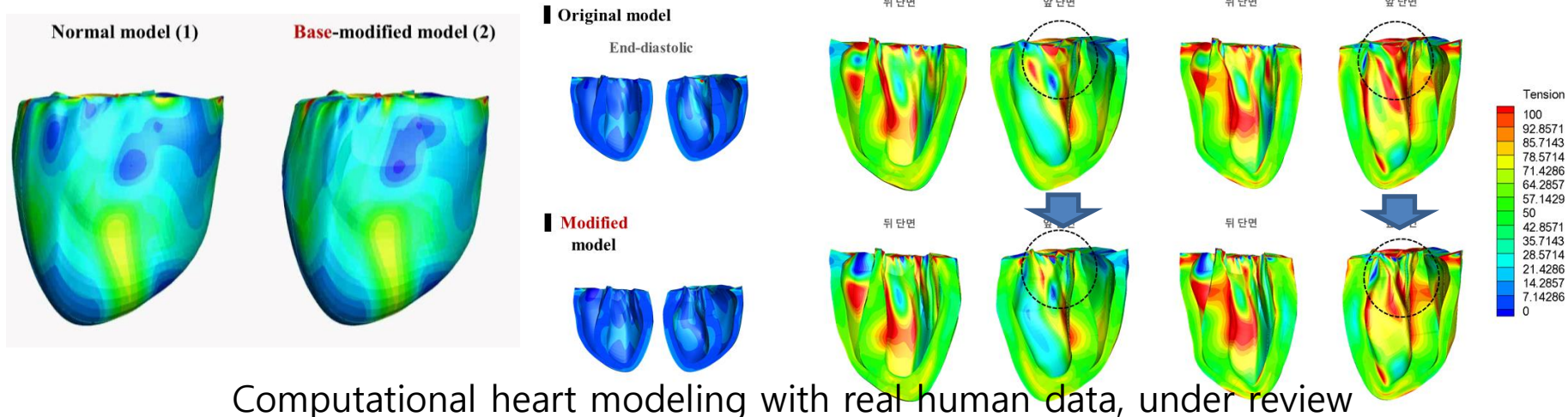
Preserved contractility & reduced LV wall tension



End systolic pressure volume relationship (Ees)




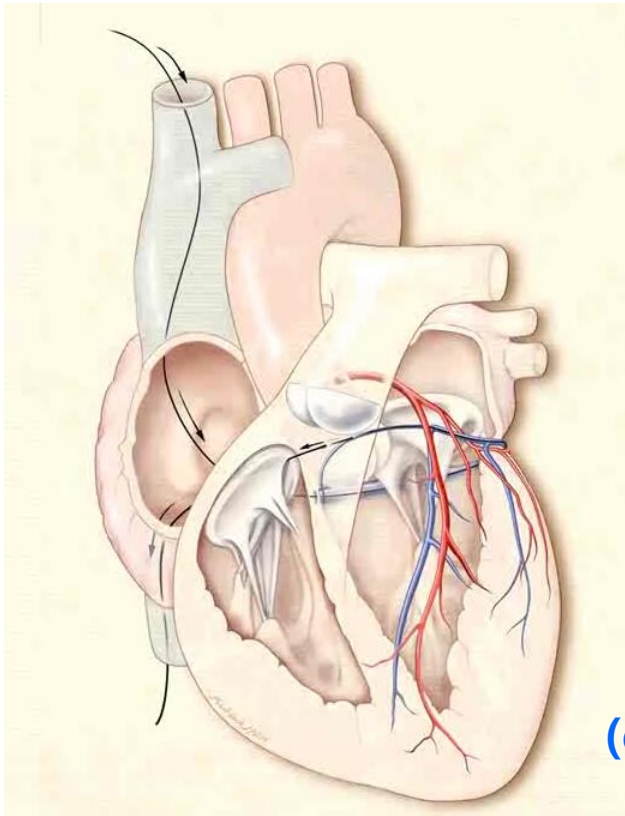
Kim JH, Lederman RJ et al. JACC 2009;54:638



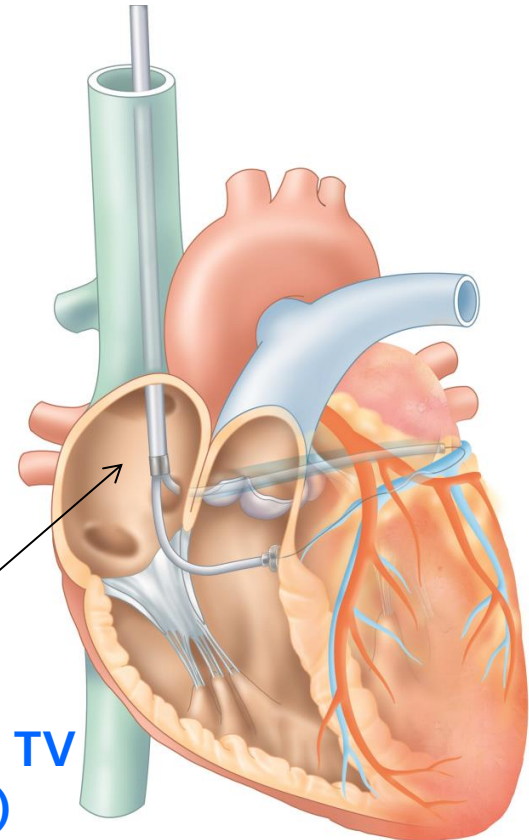
What is Mitral Loop Cerclage ?

- Circumferential tension around MV annulus by LV basal squeezing

- Reinforce of safety issues
- improving technical feasibility



CSTV
(coronary sinus and TV protective device)

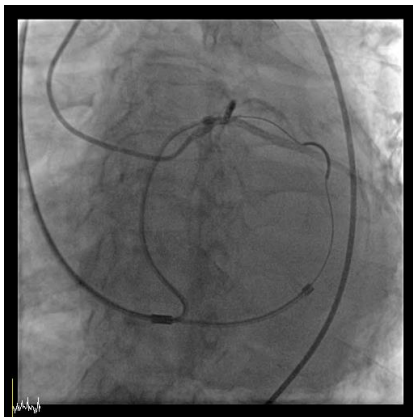
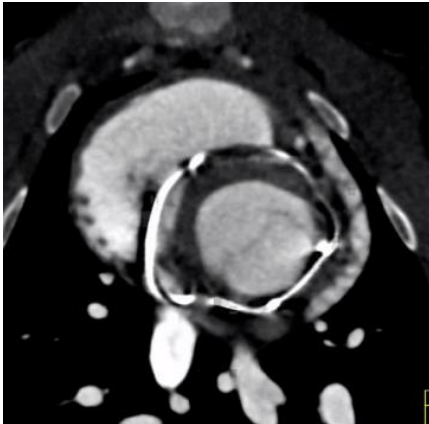

Mitral Cerclage + a bifid appliance = Mitral Loop Cerclage

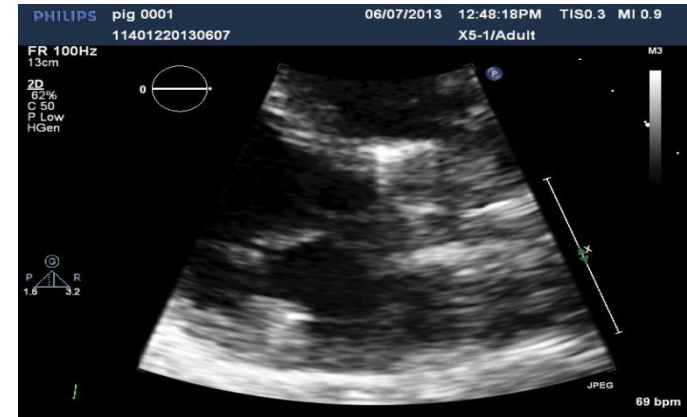
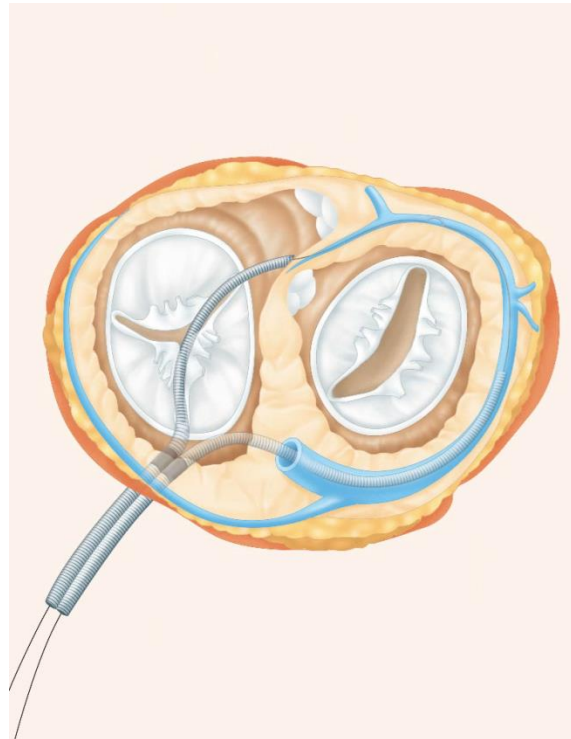
How to function?

(1) TV & conduction protection

(2) Interactive tension adjustment



Arch formation during tension



Septal lateral dimension



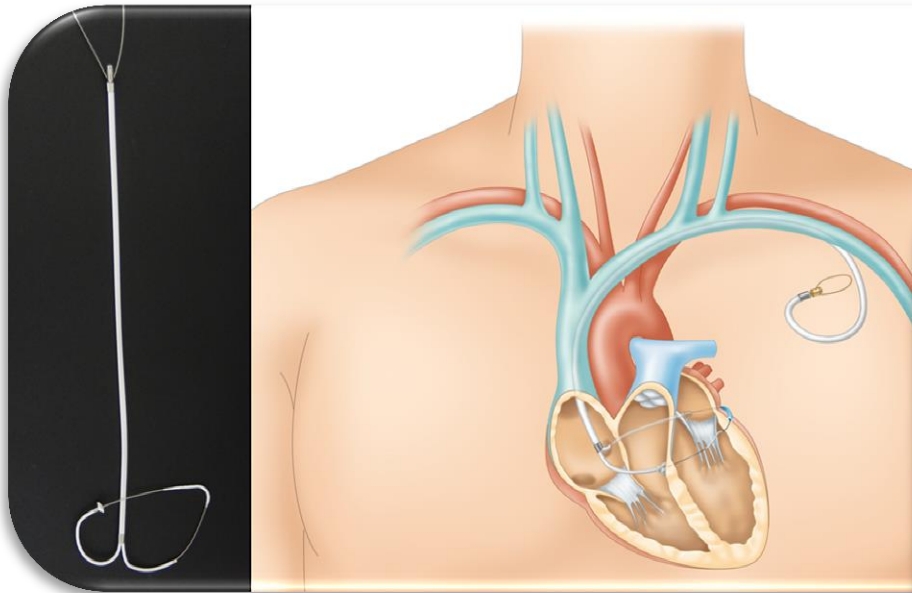
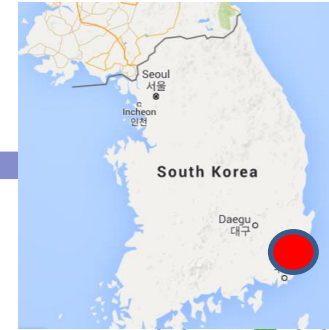
Tensioning through a tip of CSTV loop



(3) Easy re-adjustment of tension when it is needed

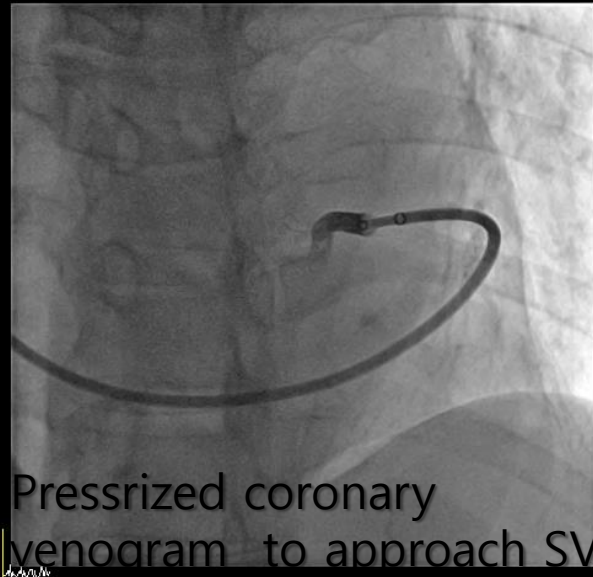
The early feasibility study of Mitral Loop Cerclage (n=5)

The first case of Mitral Loop Cerclage FIM in PNUYH, Korea (July 10th 2015)

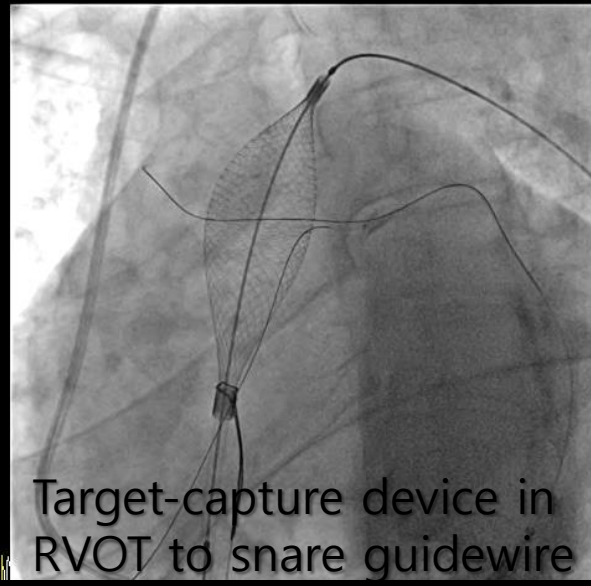


Inclusion : NYHA class III or IV dyspnea due to severe functional MR in spite of optimal medical TX at least for 3 months

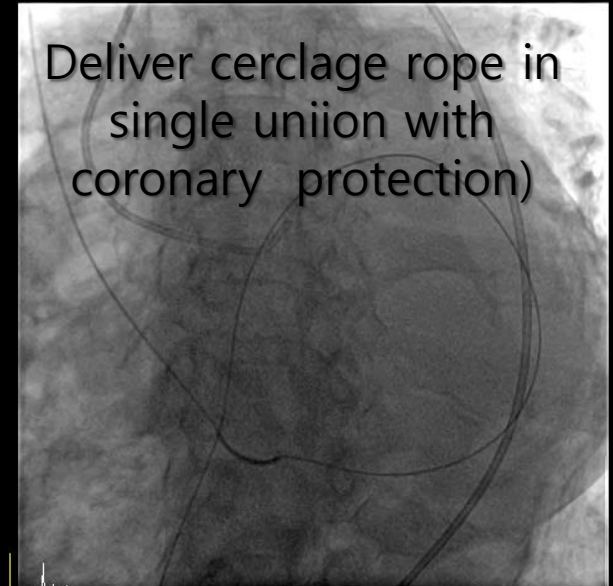
mitral loop cerclage procedure



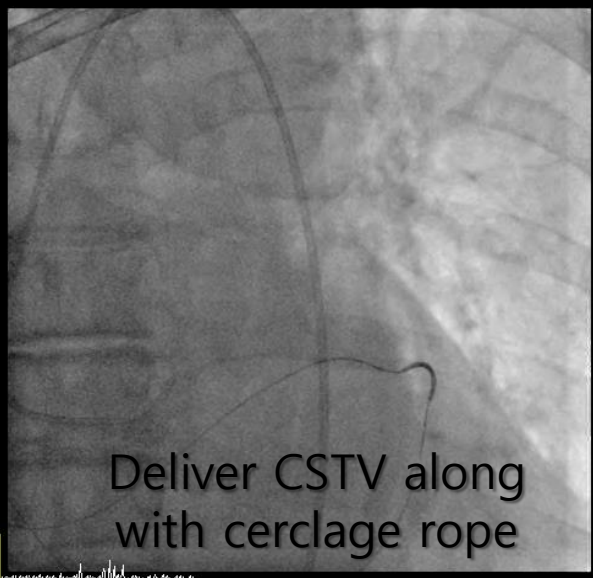
Pressurized coronary venogram to approach SV



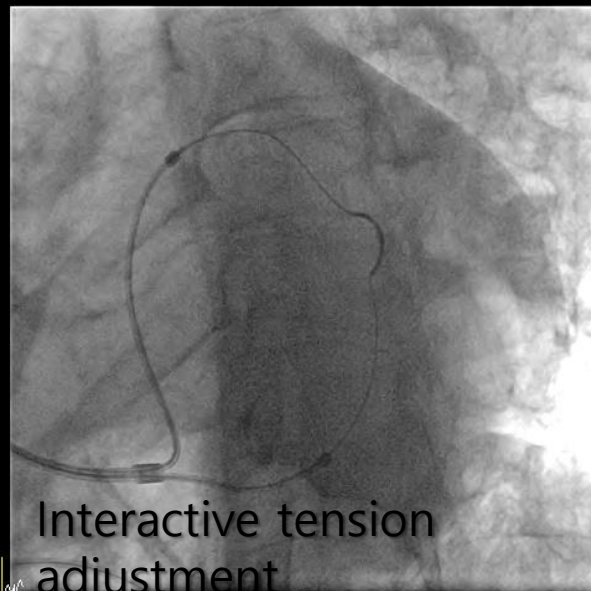
Target-capture device in RVOT to snare guidewire



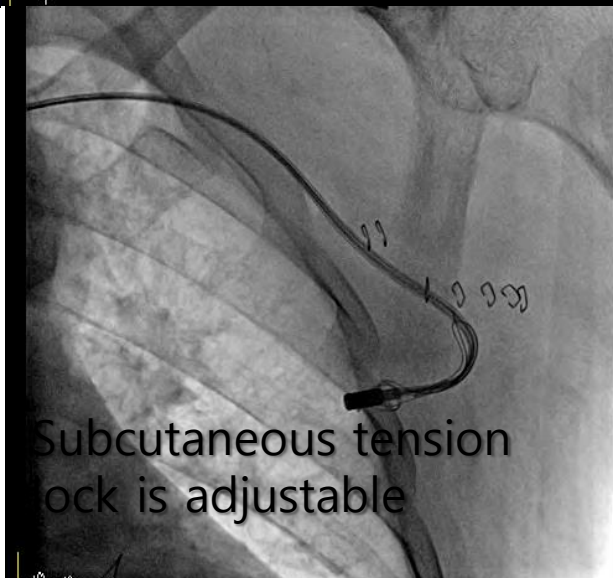
Deliver cerclage rope in single union with coronary protection)



Deliver CSTV along with cerclage rope



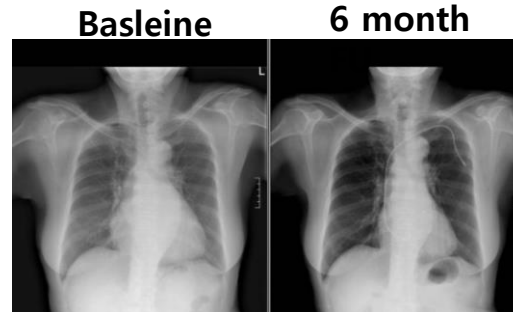Interactive tension adjustment



Subcutaneous tension lock is adjustable

FIM result of Mitral Loop Cerclage (n=5)

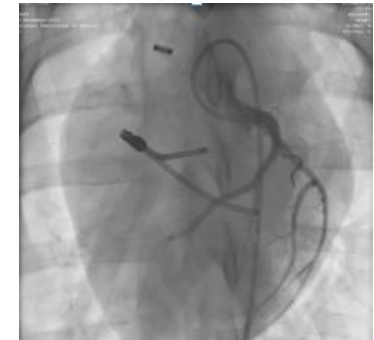(2) Reverse remodeling



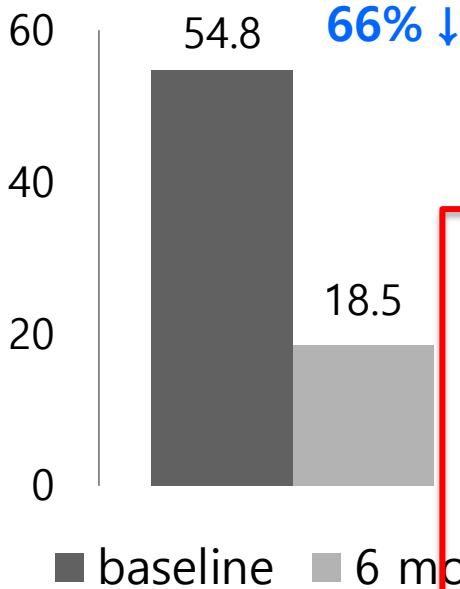
LVESV	39% ↓
LA vol	34% ↓

USA ceclage human trial in 2018

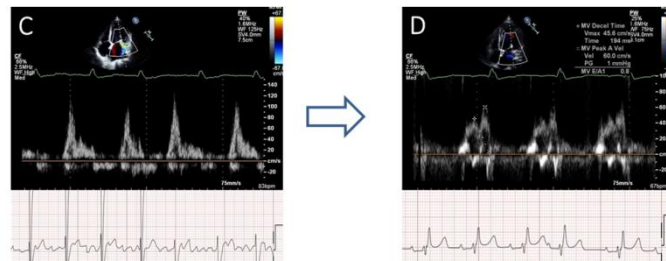
- NIH-Transmural IDE
- Intra-cardiac locking



(1) Regurgitant Volume (RV, mL)



(3) Electrical remodeling (n=2)



AF reverted to NSR in all cases of chr AF

2nd Clinical trial in Korea Underway

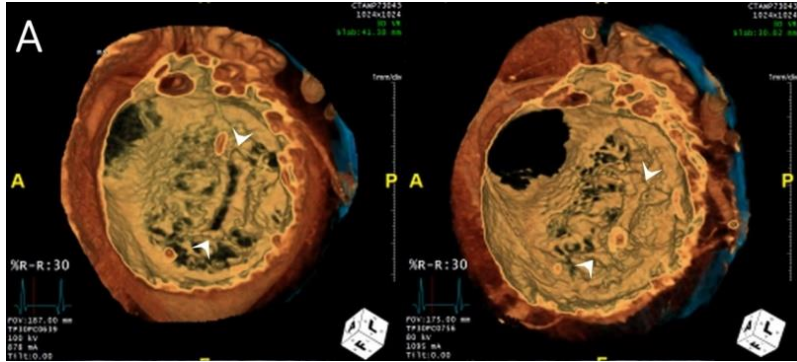
- Inclusion criteria
- Function MR with Chr AF

AFRICA study

: AF Reversion to sinus In Cerclage Annuloplasty

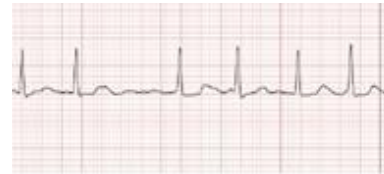A Representative Case:

74F, NICM, NYHA IV dyspnea despite aggressive medical therapy for 1yr

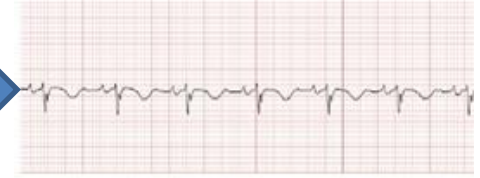

Baseline

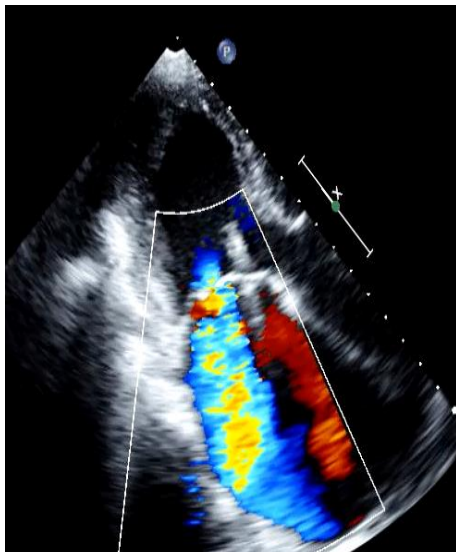
1 month



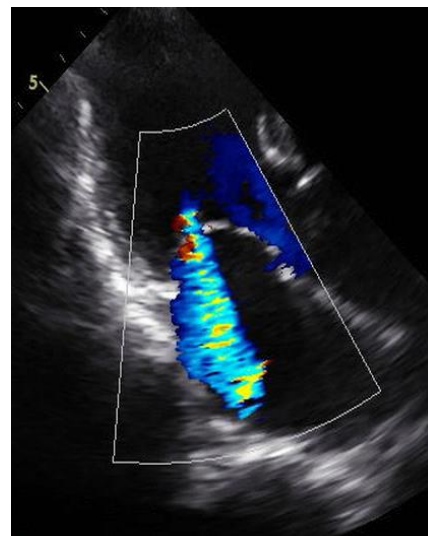
Chronic AF



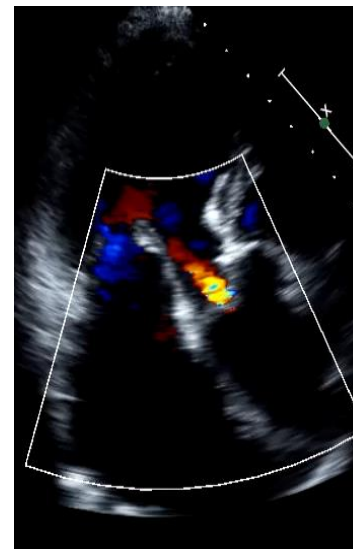
Normal sinus rhythm



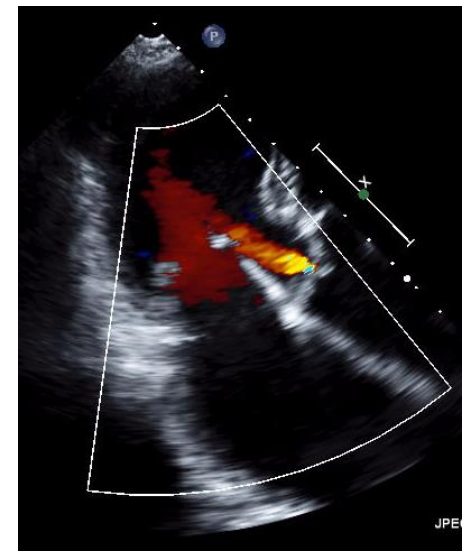
- ERO 0.34 cm²
- RV 63 ml
- Atrial fibrillation



- ERO 0.14 cm²
- RV 25 ml
- Normal sinus R



- ERO 0.10 cm²
- RV 23 ml
- Normal sinus R



- Mild MR
- Normal sinus R

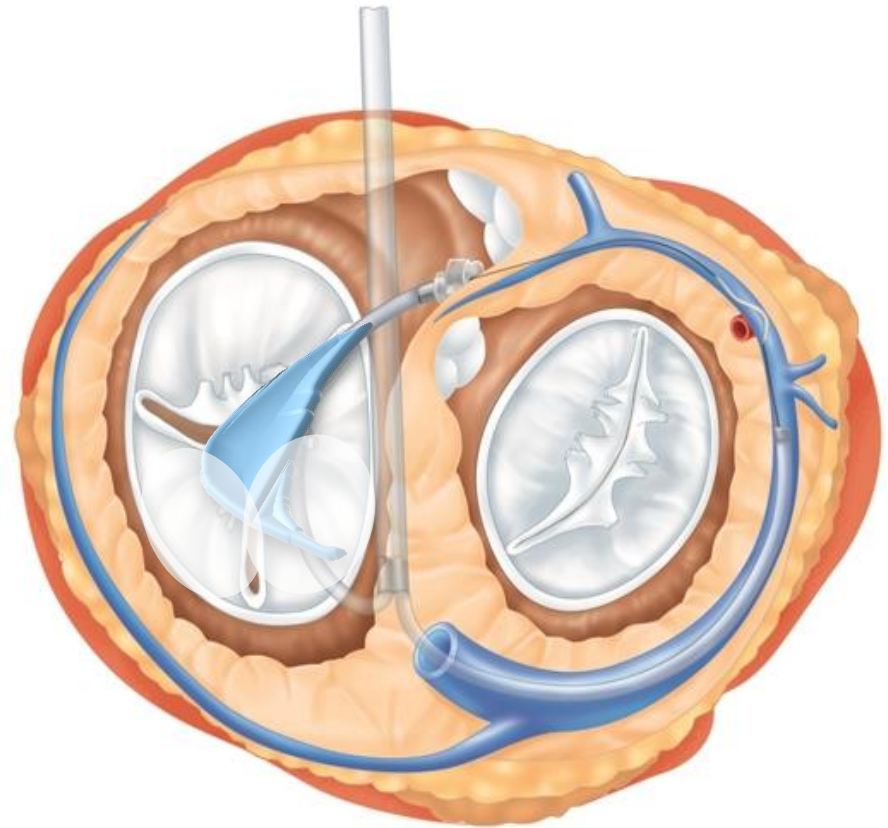
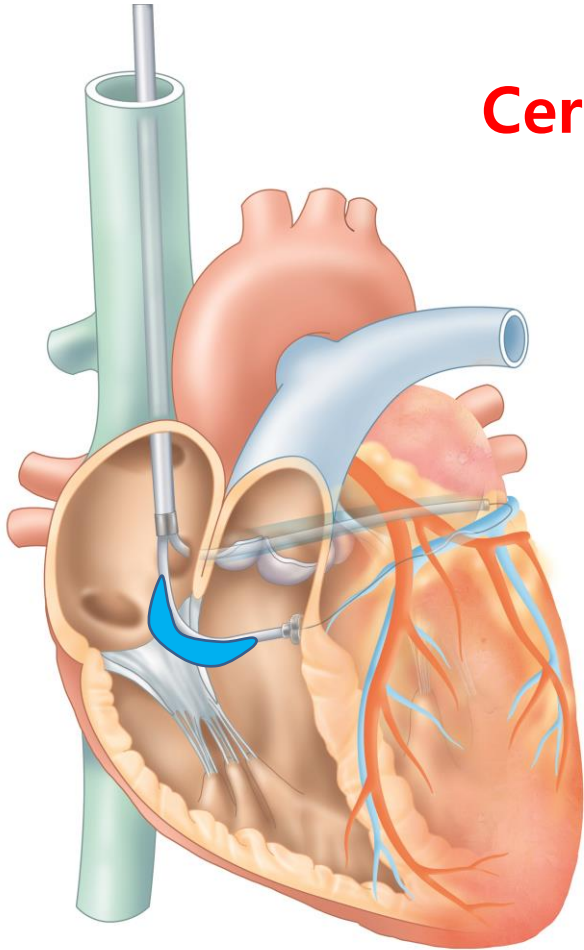
Extension of Mitral Loop Cerclage to treat TR

Mitral Loop Cerclage

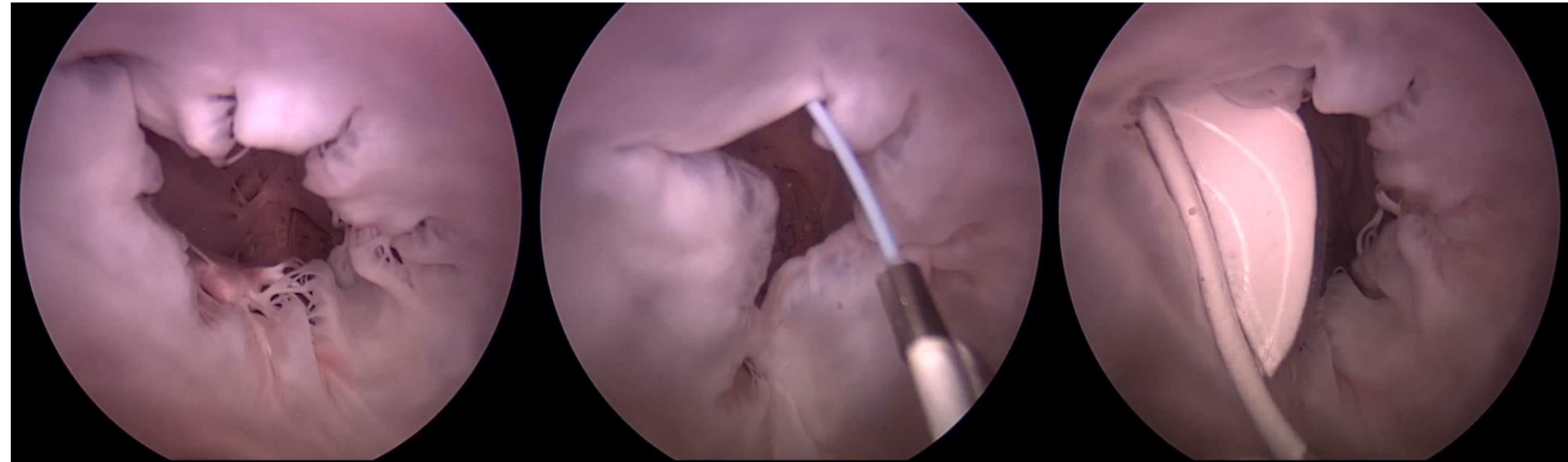
+

Septal leaflet extension on CSTV

Cerclage TR Block

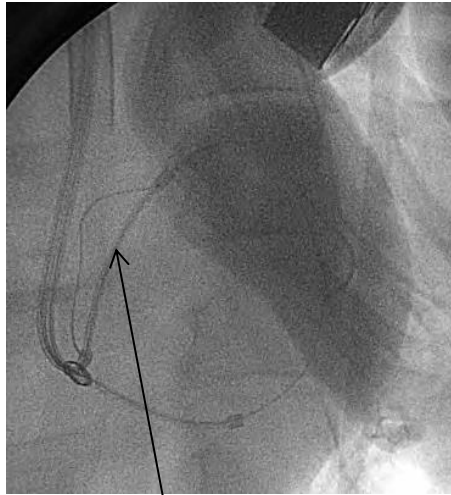

Cerclage T-leaflet for severe TR Functional TR model

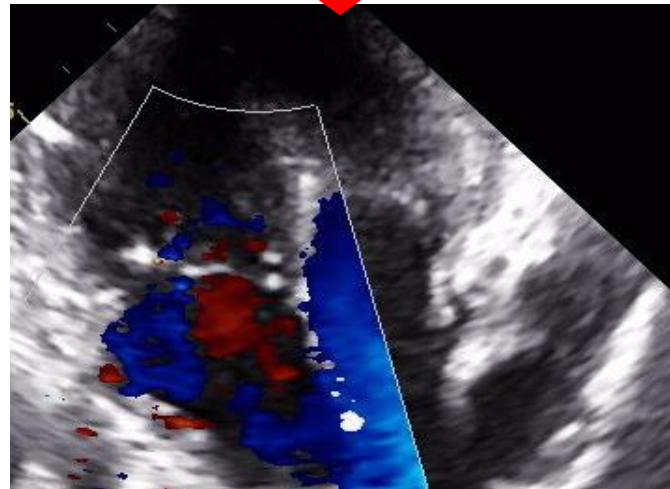
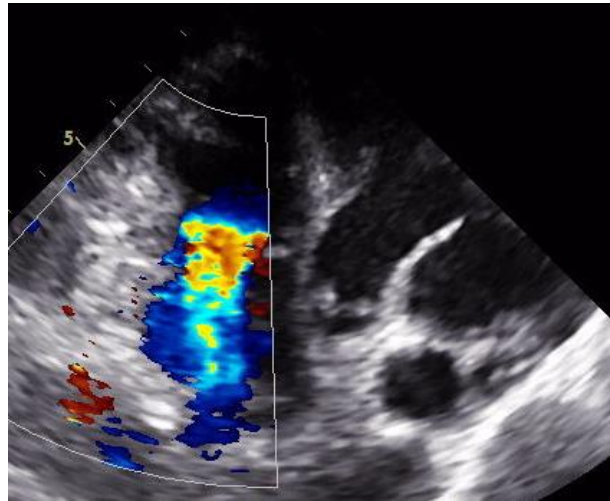


*Isolated porcine heart model with mechanical pumping system

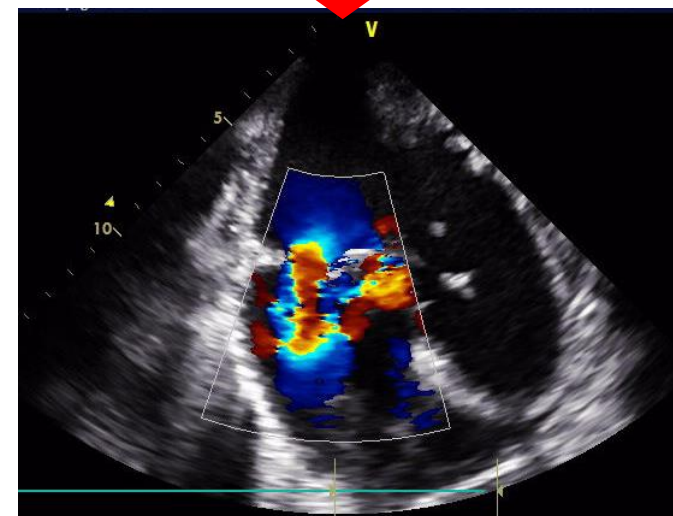
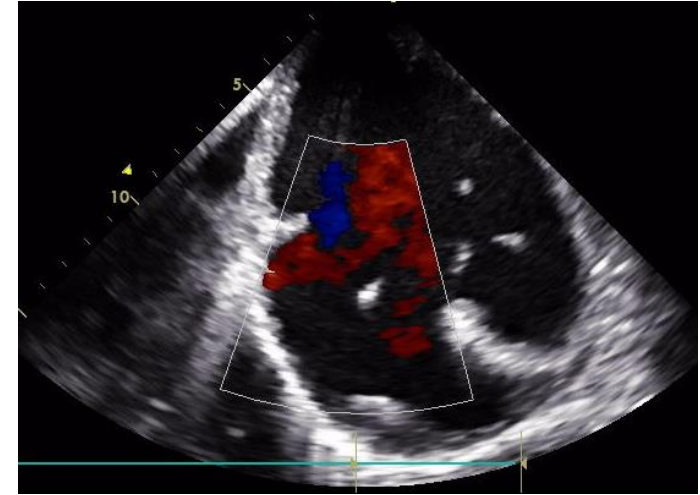
Cerclage TR Block : Animal study



Septal leaflet extension on CSTV



Functional TR



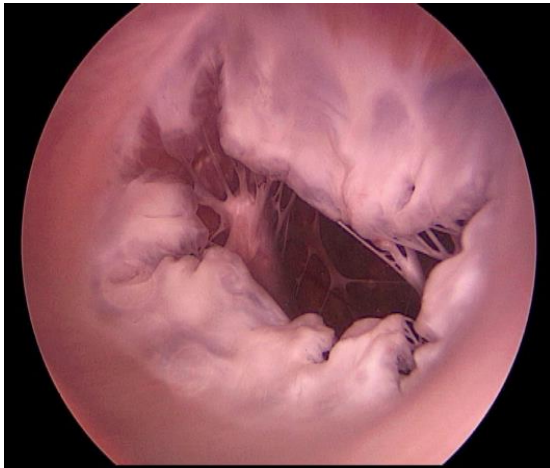
Torrential TR : valve destruction

One device treats two valves at once

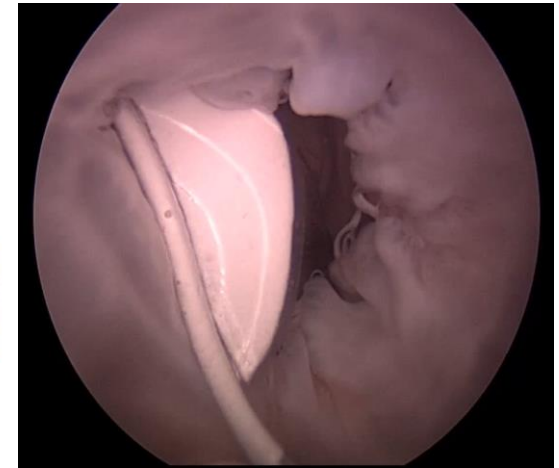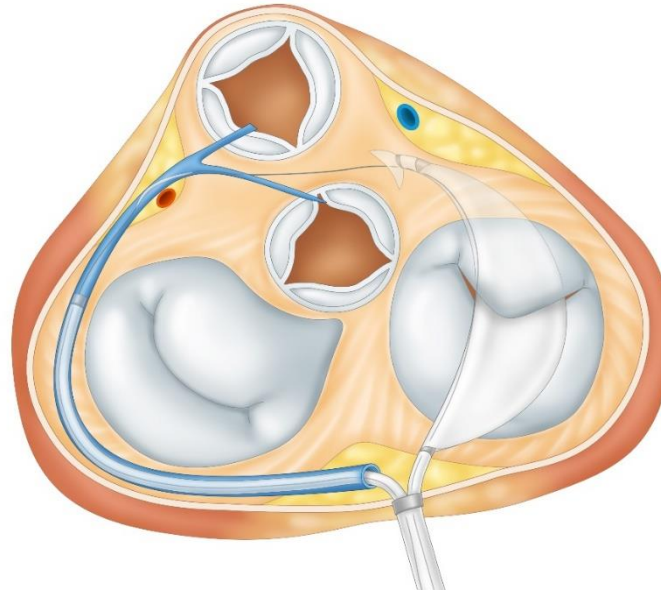
Mitral Loop Cerclage (MLC)

+

Septal leaflet extension on MLC platform



Functional MR being treated with cerclage tension



Functional TR being treated with cerclage T-leaflet

One procedure with **one** device for treating both MR/TR at once

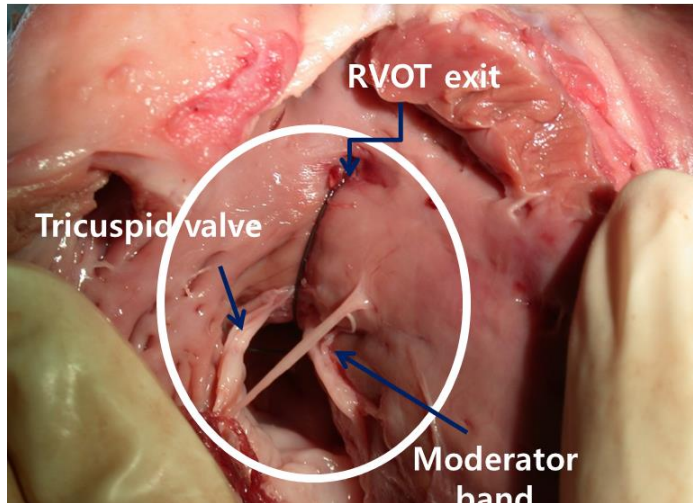
'BUY 1 GET 2' Procedure

Summary

- Mitral Loop Cerclage has shown significant reduction of functional MR & reverse remodeling of LV/LA
- Septal leaflet extension on Mitral Loop Cerclage may have potential to treat both MR/TR simultaneously

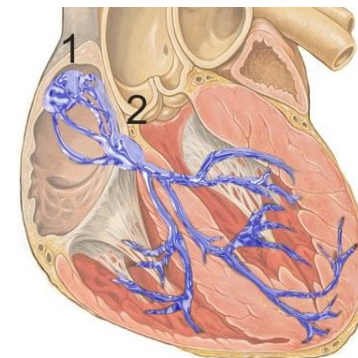
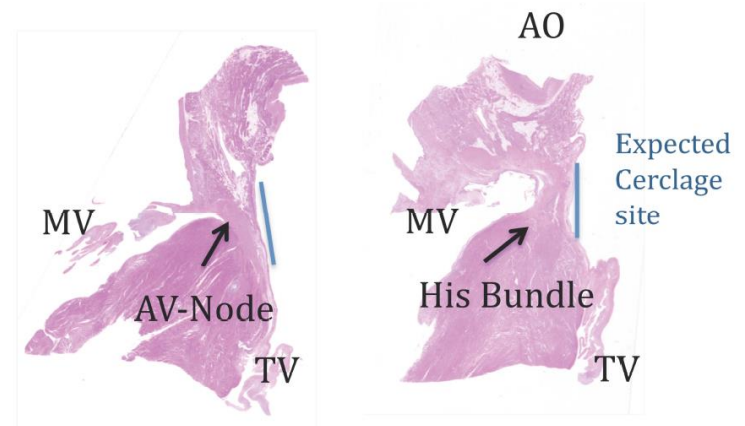
Mitral cerclage : safety issues

TV damage



Porcine Heart

Conduction block



Human Cadaver Heart