

Magnetocardiography as a new diagnostic tool to define ischemia

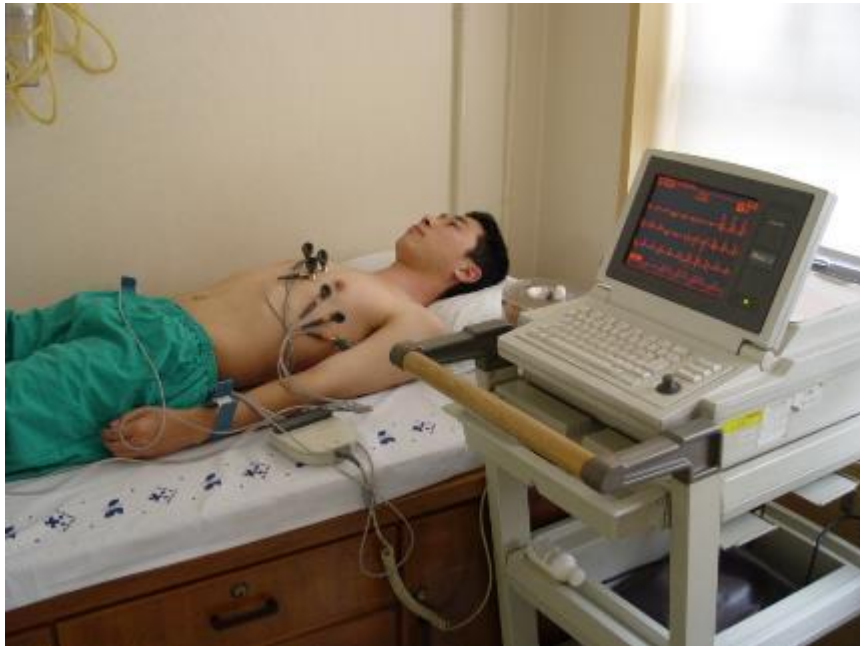Jai-Wun Park, MD

**Klinik für Kardiologie
Campus Benjamin Franklin
Charité - Universitätsmedizin Berlin**

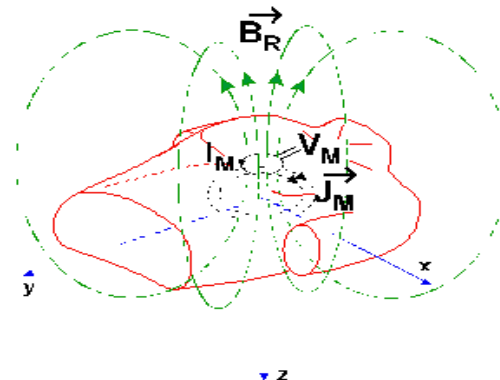
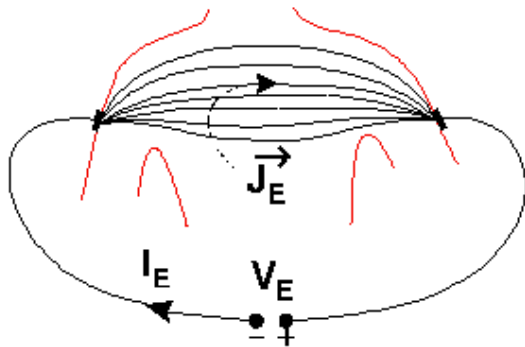
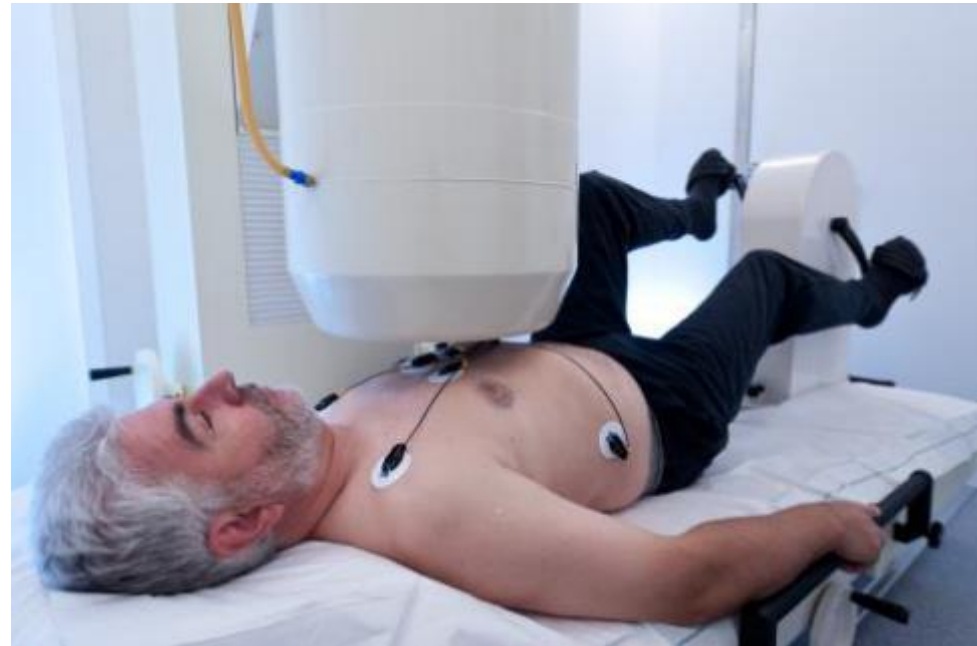**JCR Busan, Korea
2018, December 8th**

ECG vs. MCG

Conventional ECG



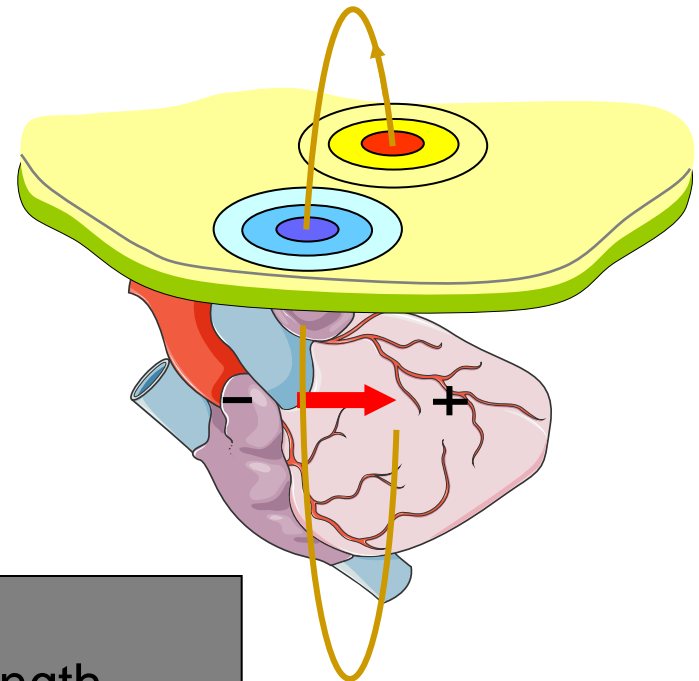
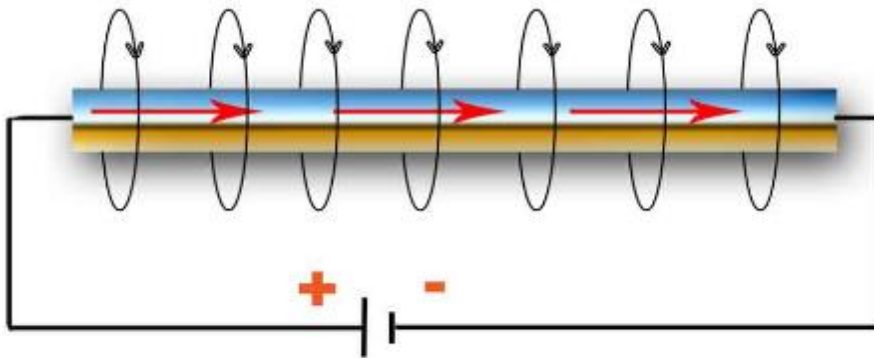
Magnetocardiography



Basics MCG

Electrophysiological currents generate magnetic fields

Magnetic field around current flow



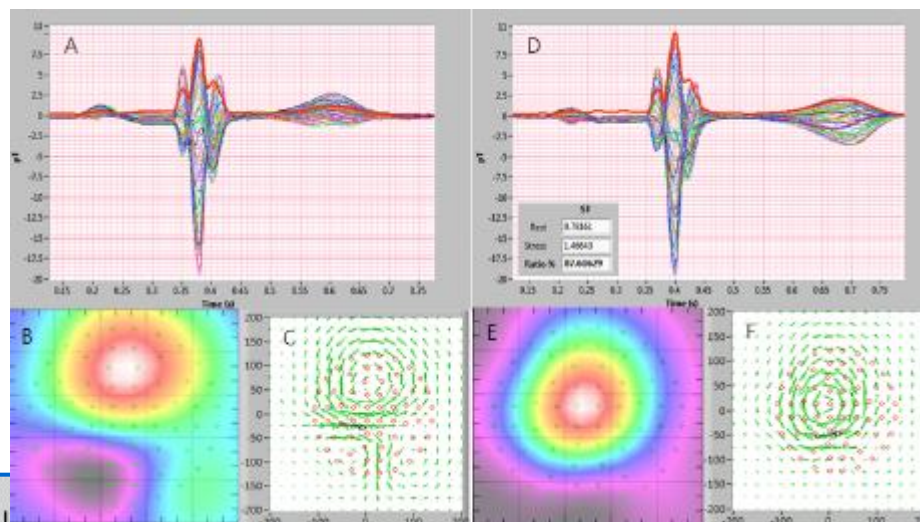
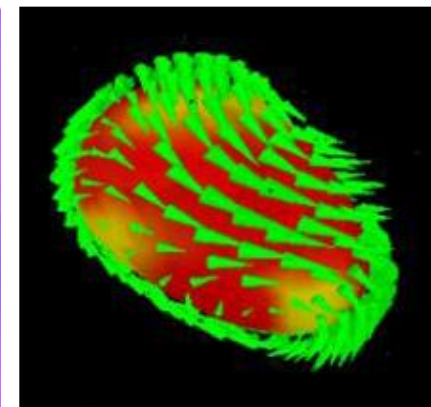
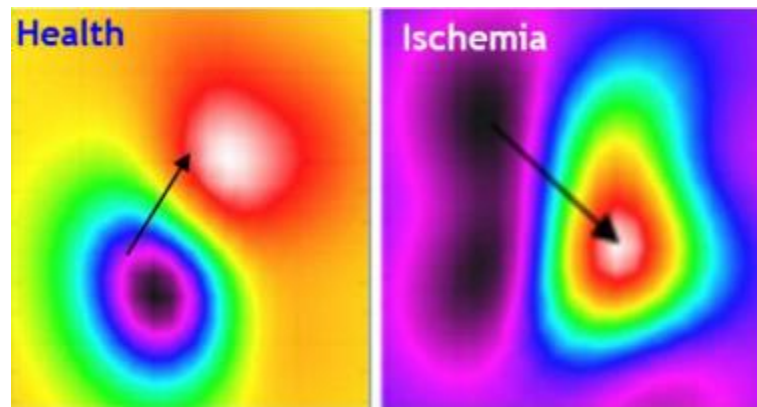
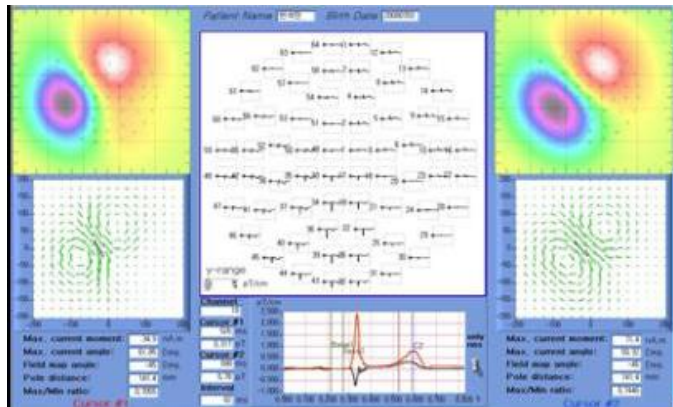
Magnetic field strength
is proportional to current strength

Highly Sensitive Heart-Signal Sensing

MCG measurement

Field mapping

3D mapping



- **Coronary Artery Disease**

- **Acute**

- **Differentiate cardiac/non-cardiac acute chest pain**

- **Chronic**

- **Screening for asymptomatic or symptomatic patients**
- **Evaluation after revascularization (stenting or bypass surgery)**

- **Microvascular angina**

- **Microvascular dysfunction**

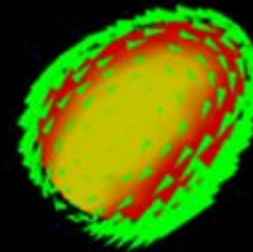
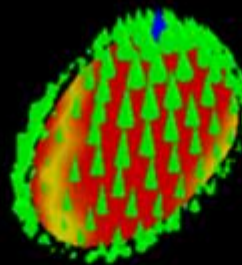
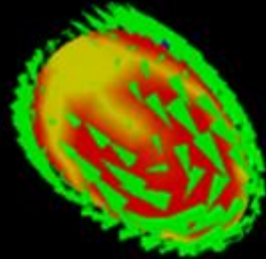
MCG image: 3D mapping

Frontal


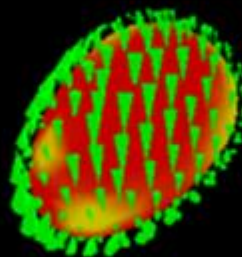
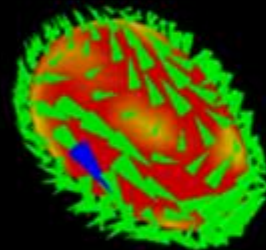
Lateral

Inferior

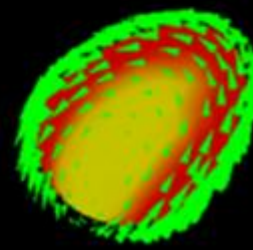
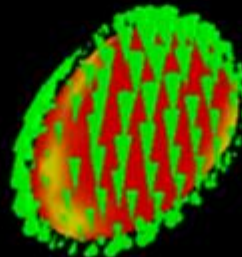
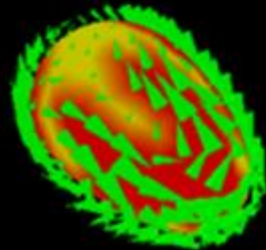
Rest



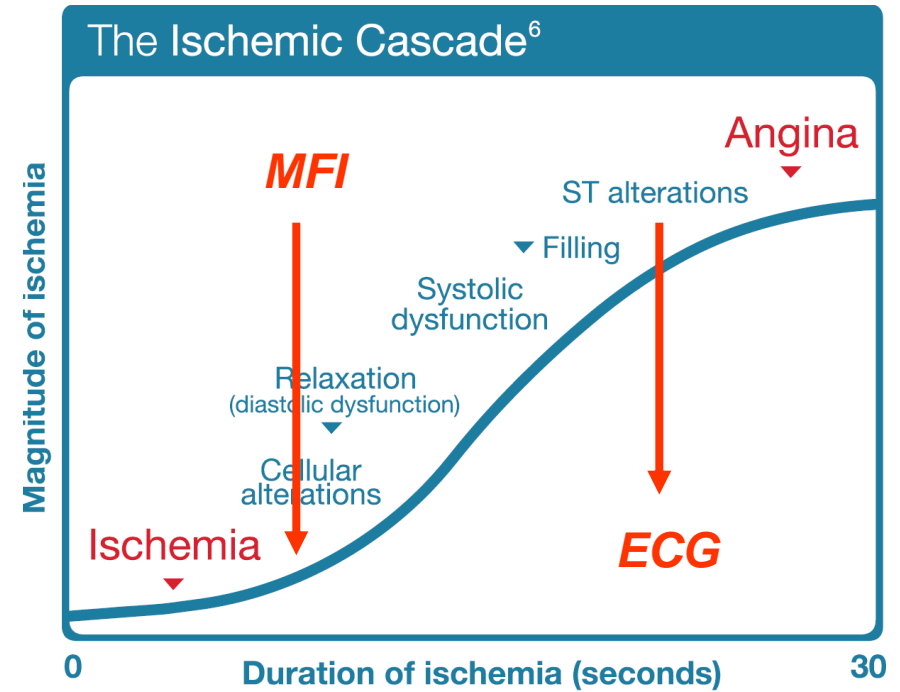
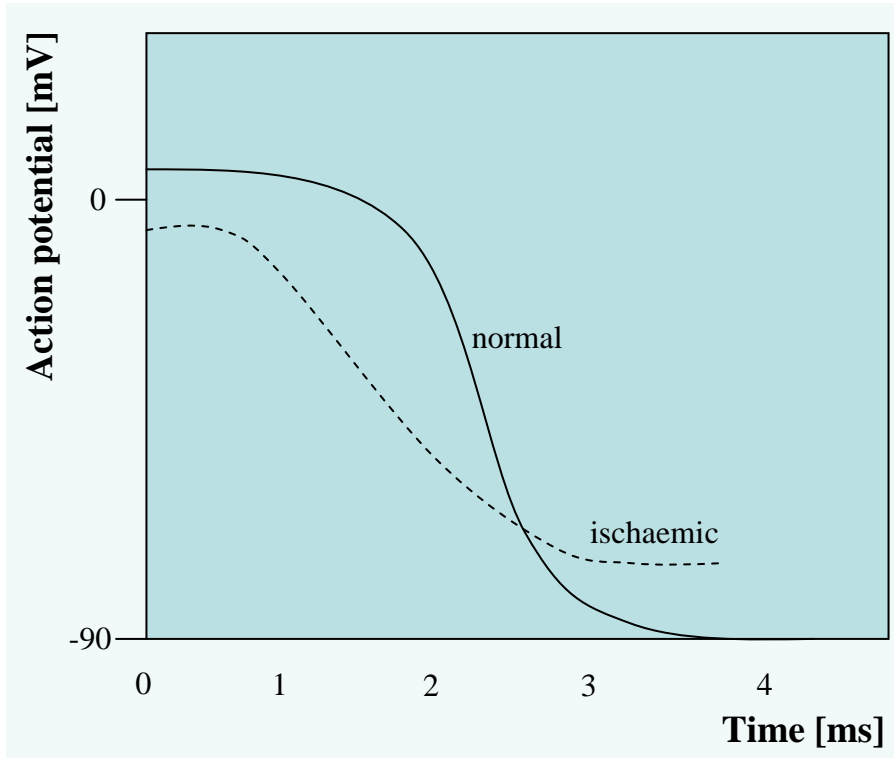
Stress



Subtraction



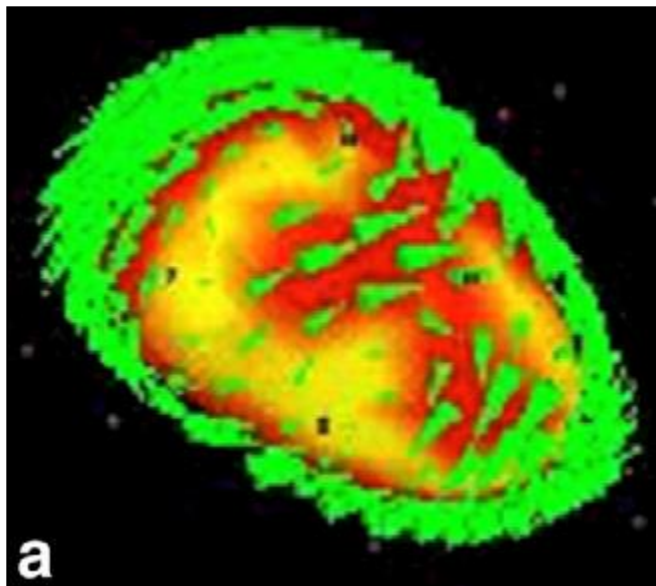
Magnetic Field Imaging (MFI) more sensitive than ECG in Ischemic Cascade



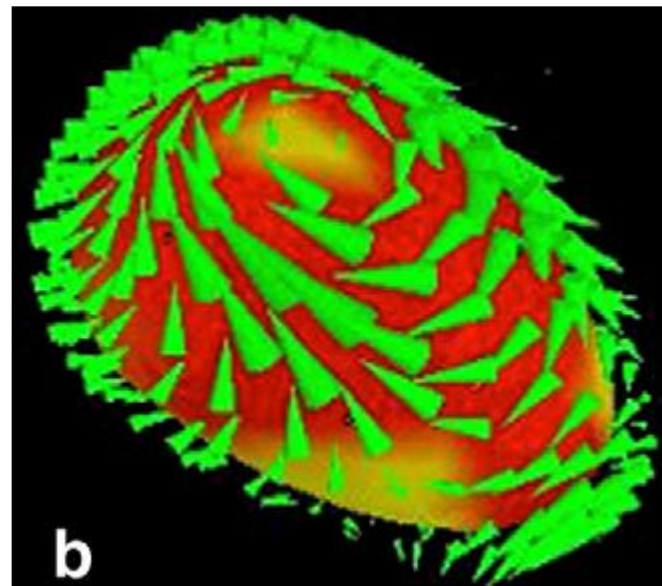
Holland RP, Brooks H. Precordial and epicardial surface potentials during Myocardial ischemia in the pig. A theoretical and experimental analysis of the TQ and ST segments. *Circ Res* 1975; 37: 471-480.

Kern MJ. Coronary blood flow and myocardial ischemia. In: Zipes DP, Libby P, Bonow RO, Braunwald E, eds. *Braunwald's Heart Disease: A Textbook of Cardiovascular Medicine*. 7th ed. Philadelphia, PA: Elsevier Saunders; 2005:1103-1128.

Stress-induced reduction of current strength in LAD



Restoration of current strength after LAD stenting

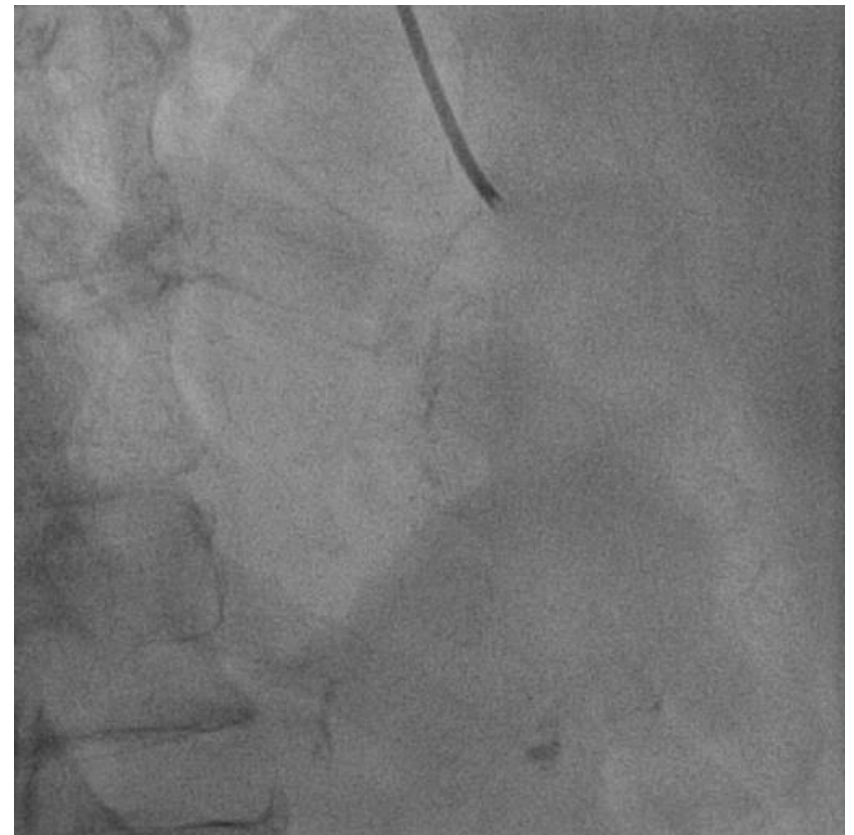
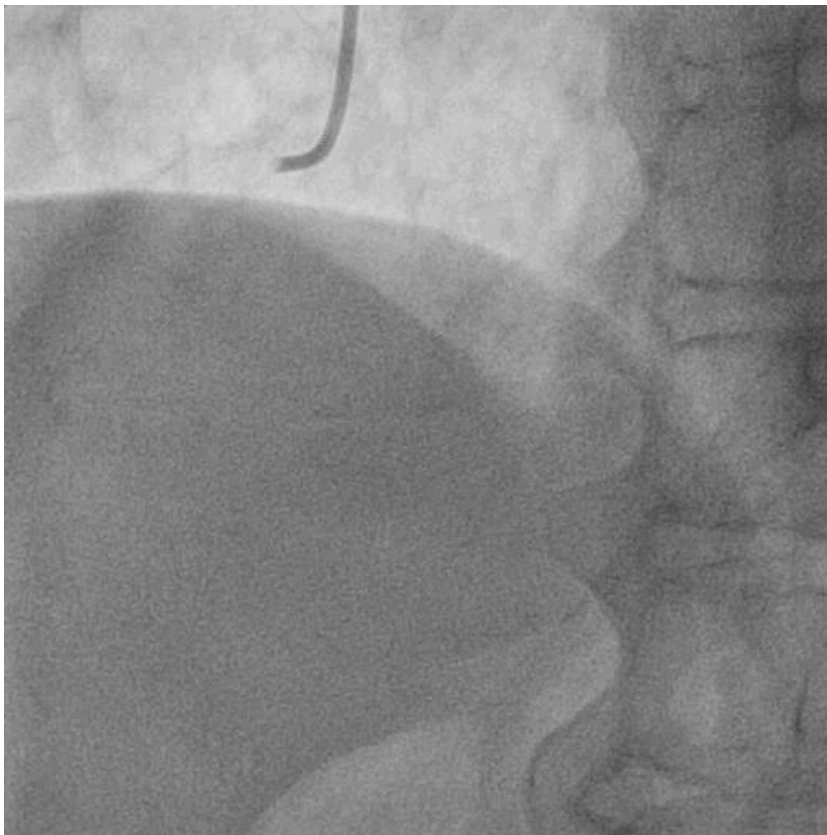

difference between rest and stress phase

Int J Cardiol 2013 Jan 18

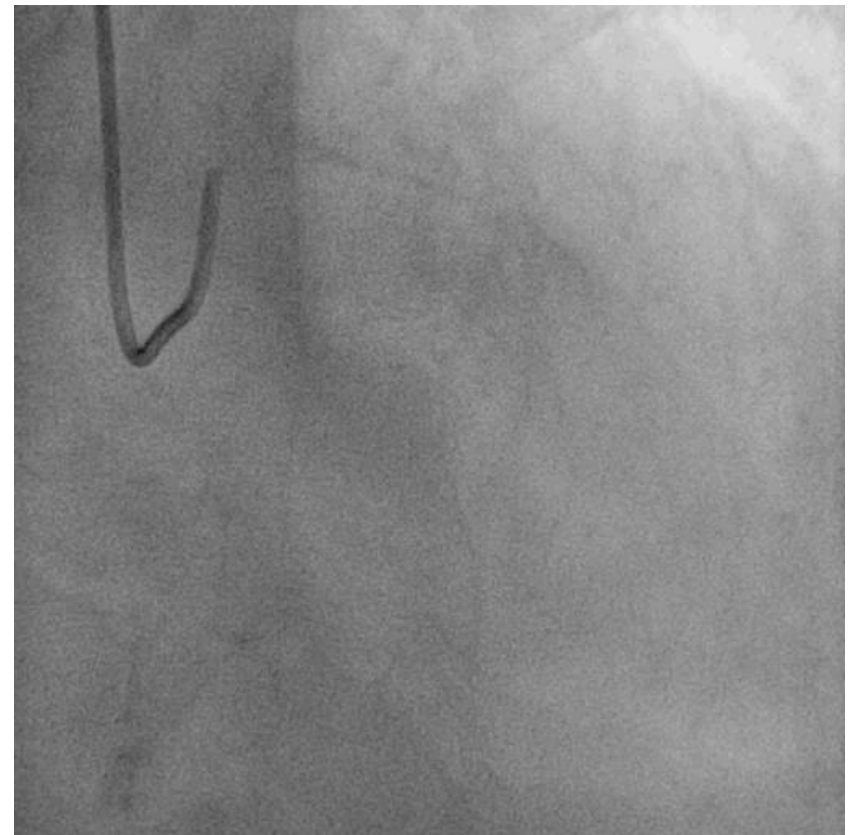
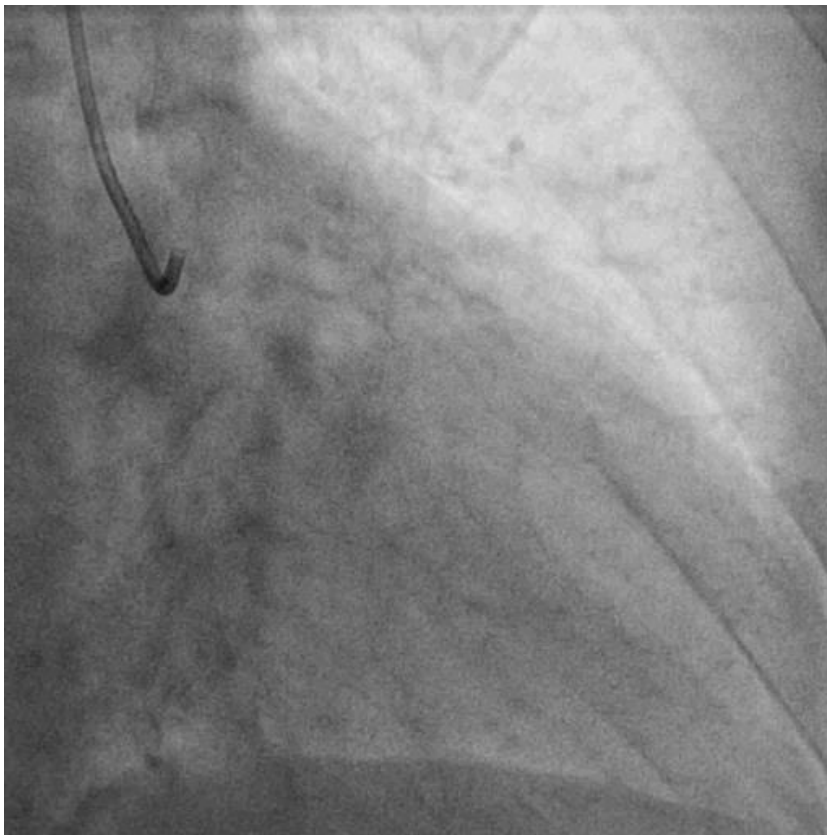
Representative Case 1: M/77yrs

FFR: RCA = 0.89



Representative Case 1: M/77yrs

FFR: LAD = 0.76



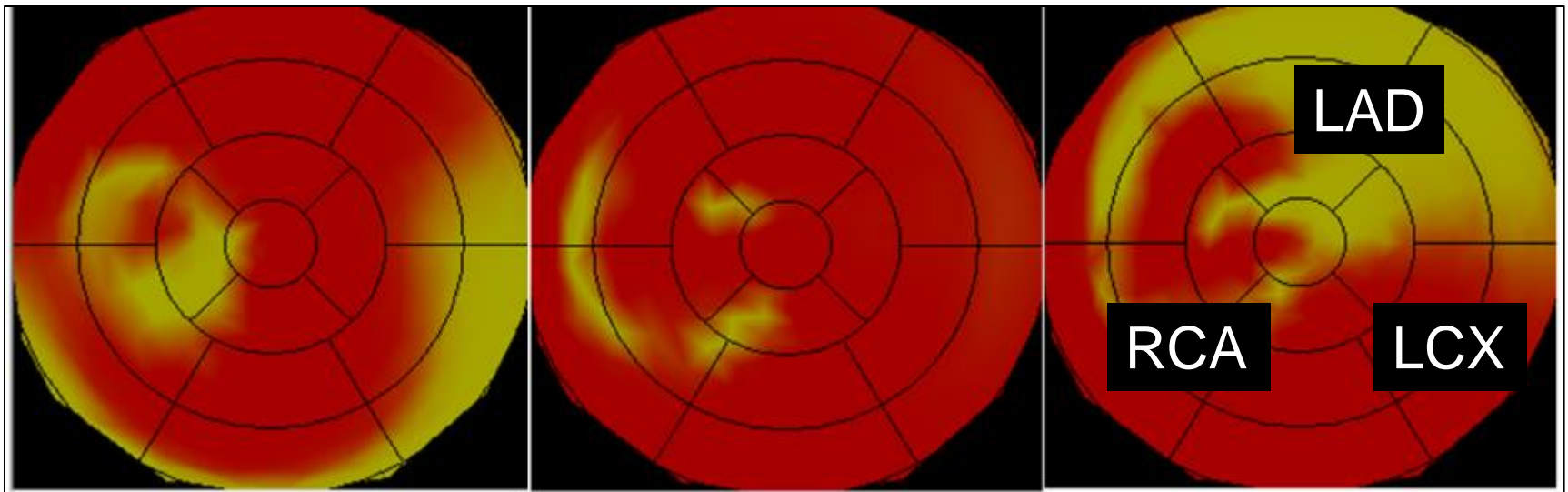
FFR: LAD = 0.76

MCG image: Bull's-eye mapping

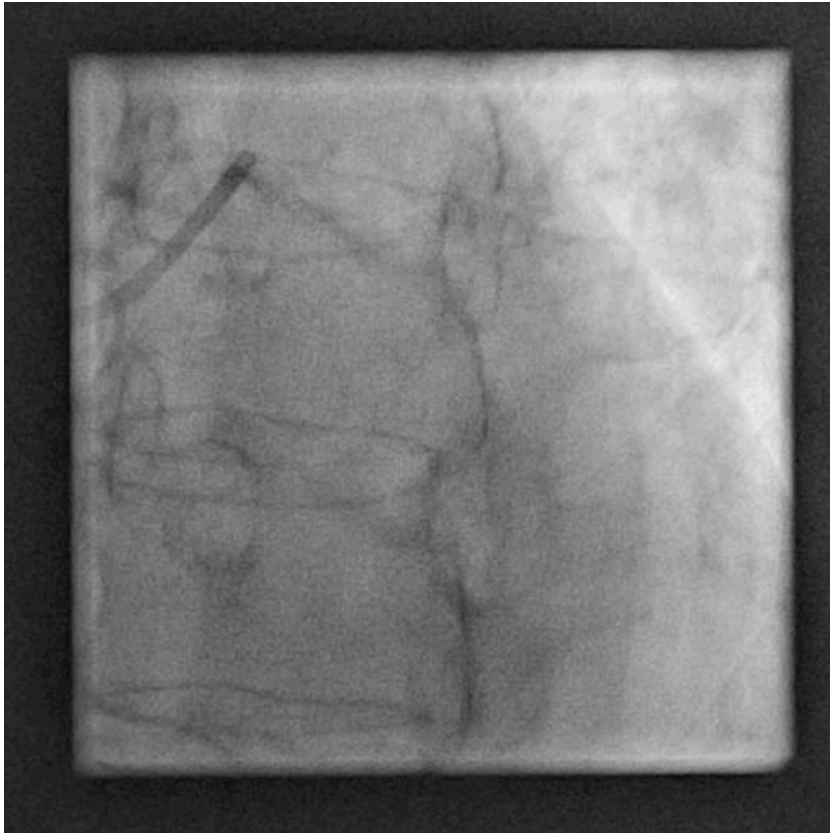
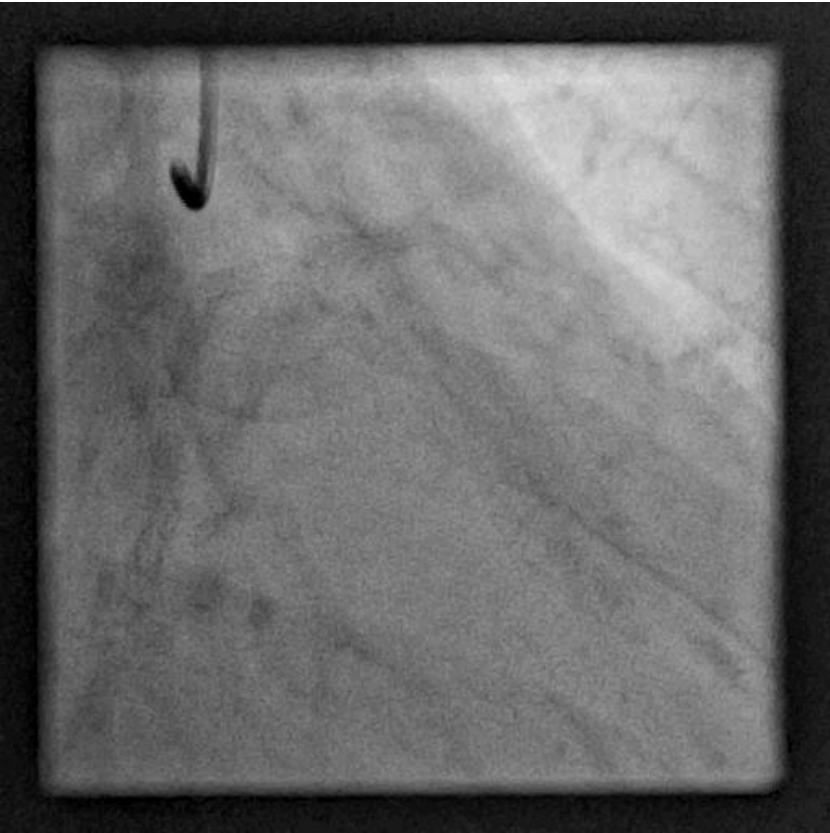
Rest

Stress

Subtraction



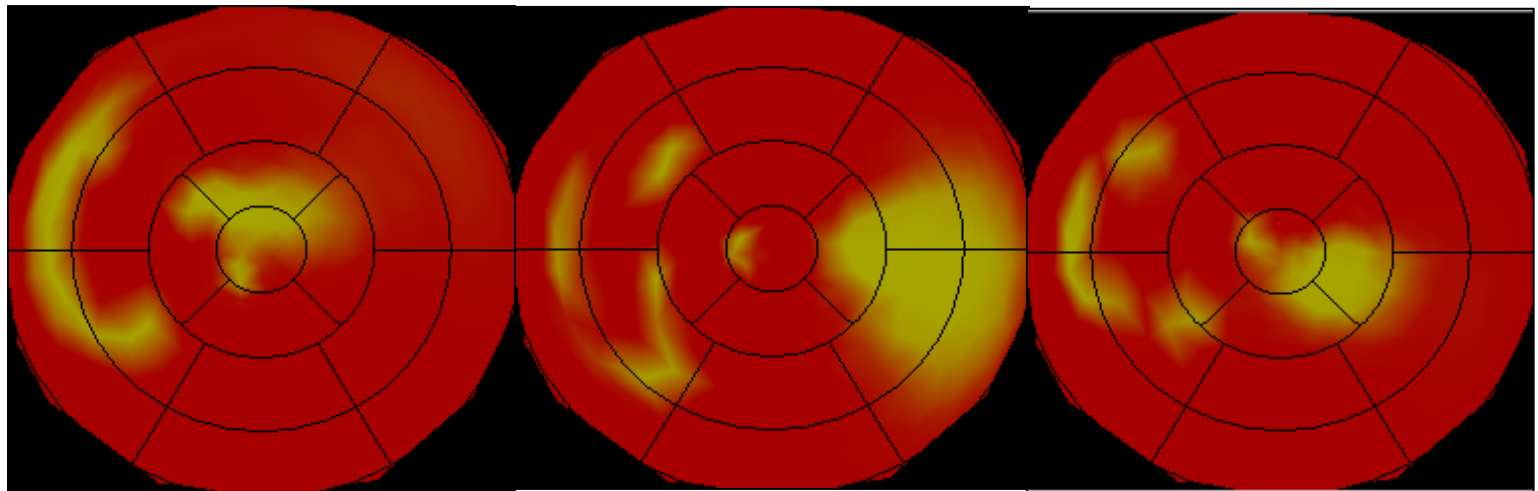
Representative Case 2: F/69yrs



FFR: LAD = 0.82

MCG image: Bull's-eye mapping

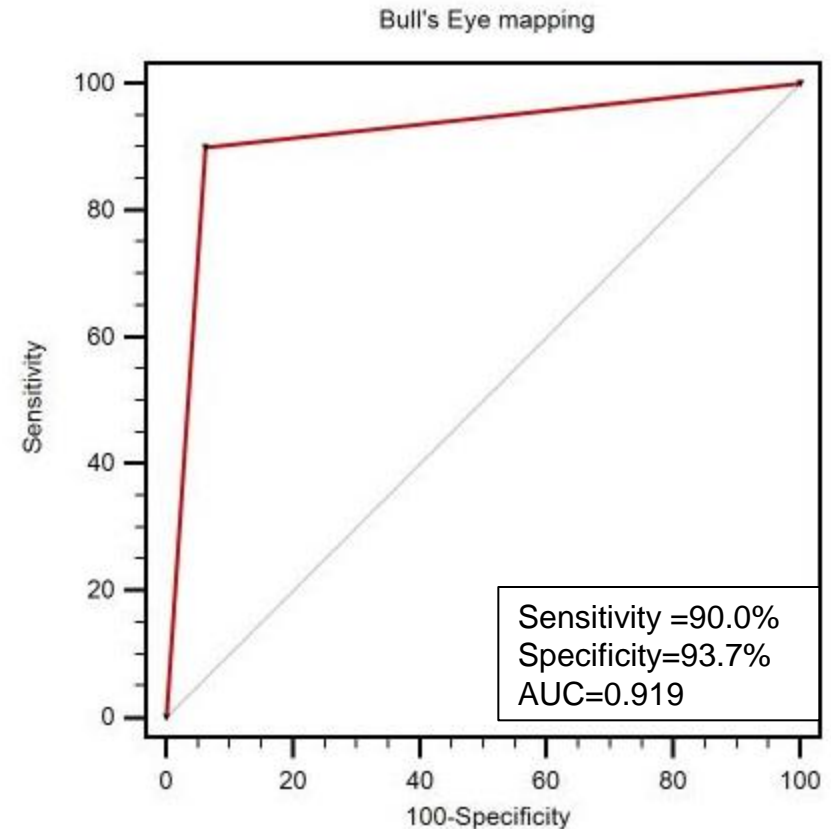
Bull's-eye
mapping



Sensitivity & Specificity of MCG vs. FFR on Coronary Territory Basis (n=52)

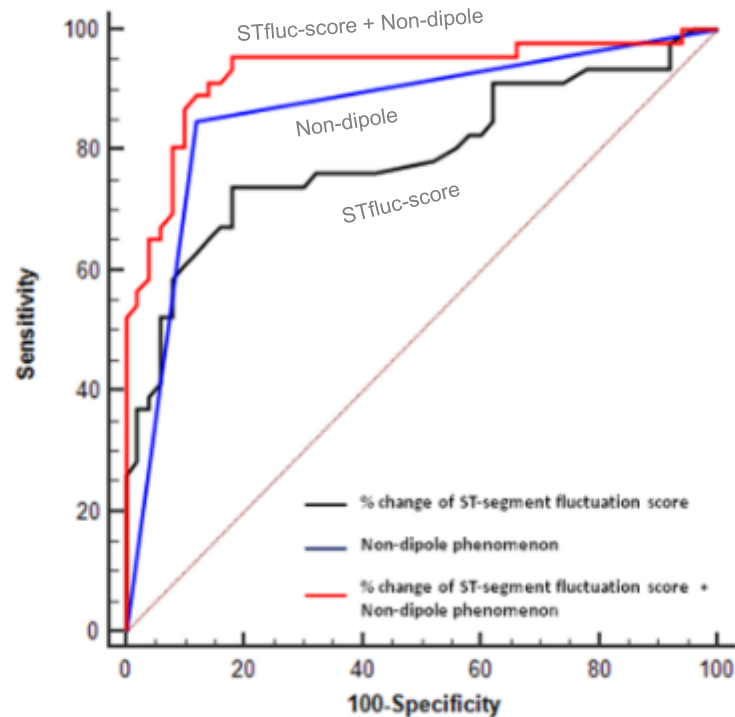
ROC Curves

Bull's-eye mapping	FFR positive	FFR negative
MCG positive	18	2
MCG negative	2	30
	Value	95% CI
Accuracy	91.9%	68.3-98.8
Sensitivity	90.0%	79.2-99.2
Specificity	93.7%	79.5-98.0



Park J-W, Shin ES, et al. Clin Hemorheol Microcirc 2015;59:267-281.

ROC curves for STfluc-score and non-dipole phenomenon



	C-Statistics	95% CI	p Value
% change of ST-segment fluctuation score	0.790	0.695 - 0.867	<0.001
Non-dipole phenomenon	0.864	0.779 - 0.925	<0.001
% change of ST-segment fluctuation score and Non-dipole phenomenon	0.930	0.860 - 0.972	<0.001

Shin E-S et al. IJC 2017;228:948-952.

Ischemia-scores

- **ST-T-Score: xxx (abnormal):** angle dynamic pos
 • distance dynamic pos
 • ratio dynamic pos).
 (possible scores: 0-3)

- **VMCG-ST-Score:** xxx (Tbeg-Tmax)
 xxx (RT1/2 - Tmax). Normal <0.05.
 (possible scores: 0-2)

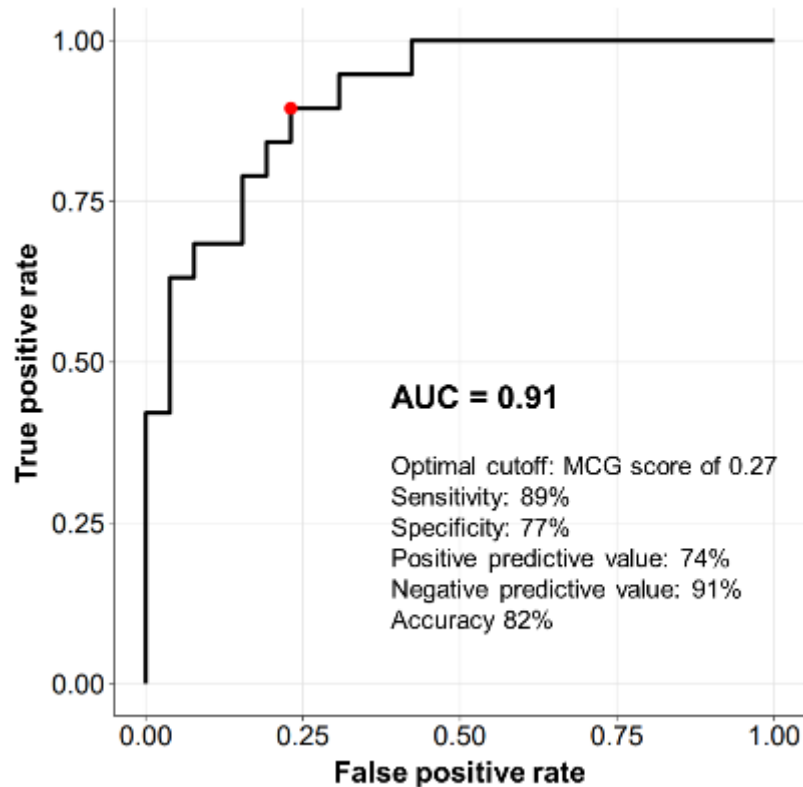
- **PLP-curve:** decrease (normal)
 • horizontal(normal)
 • increase(abnormal).
 (possible scores: 0-1)

- **T-dispersion:** xxx. (normal <8.0)
 (possible scores: 0-1)

- **STfluc-score (solely at exercise: normal <40%**
 (possible scores: 0-1)

- **Possible total scores at rest: 0-7 Possible total scores at exercise: 0-8**

Receiver-operating characteristic curve



The magnetocardiography score had a very robust area under the curve (AUC). The sensitivity, specificity, positive predictive value, negative predictive value, and accuracy at the optimal cutoff are included.

MCG defines ischemia



Microvascular Angina Diagnosis with Magnetocardiography?

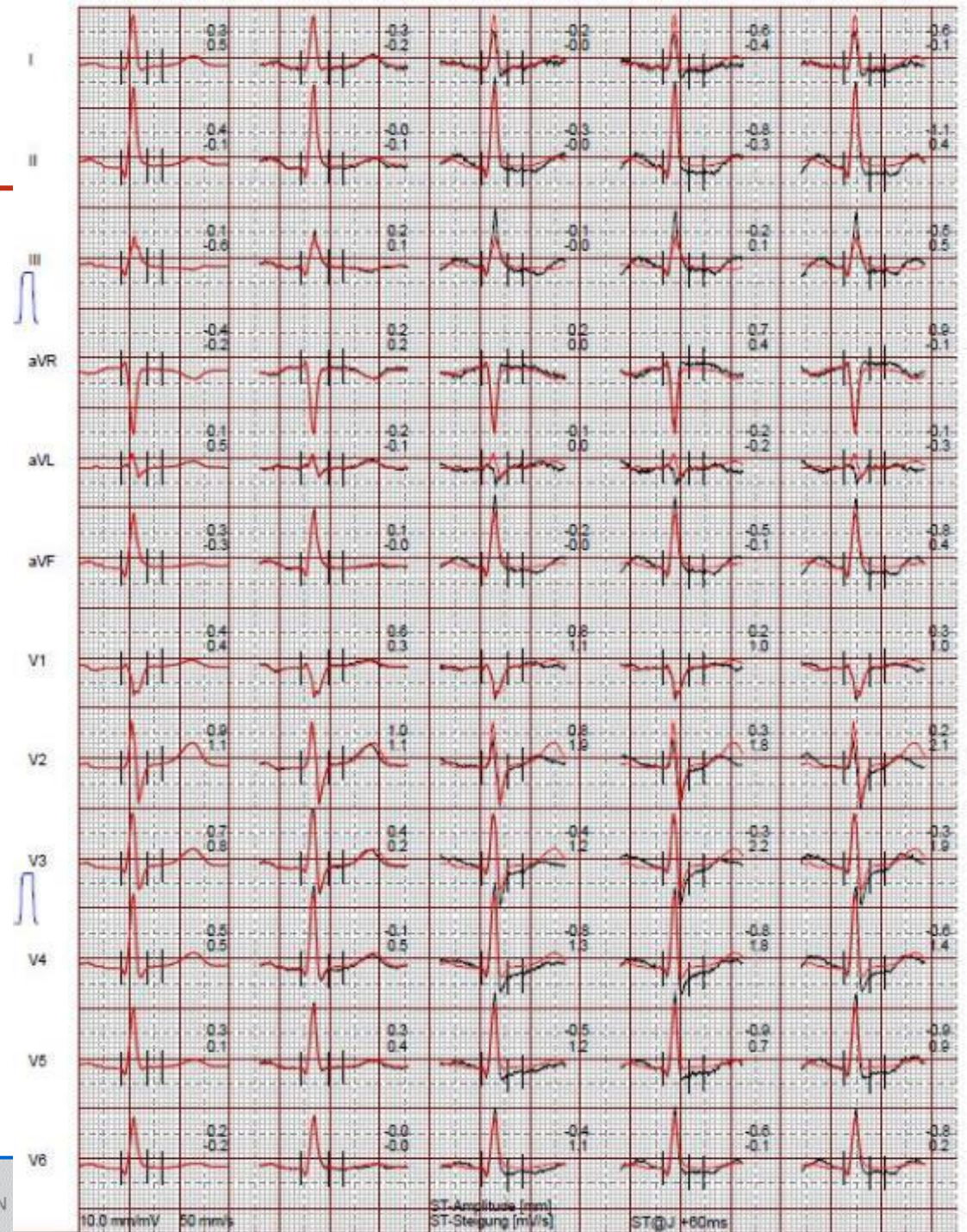
D.K., male, 60yrs, 178cm, 85kg



typical effort angina CCS II

- CVRF:**
- DM**
 - hypertension**
 - hypercholesterolemia**
 - smoking**

**D.K., male, 60yrs,
178cm, 85kg**



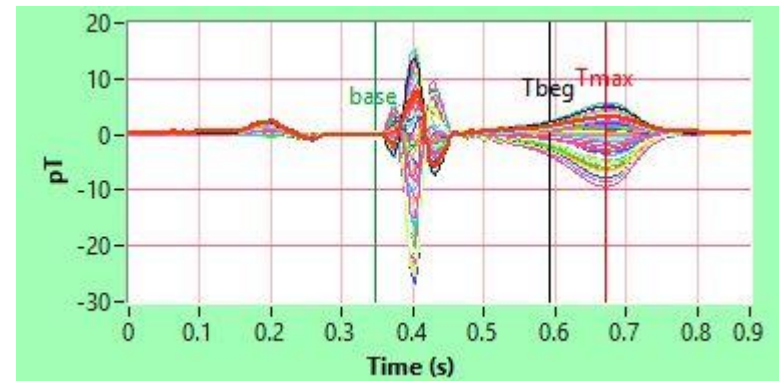
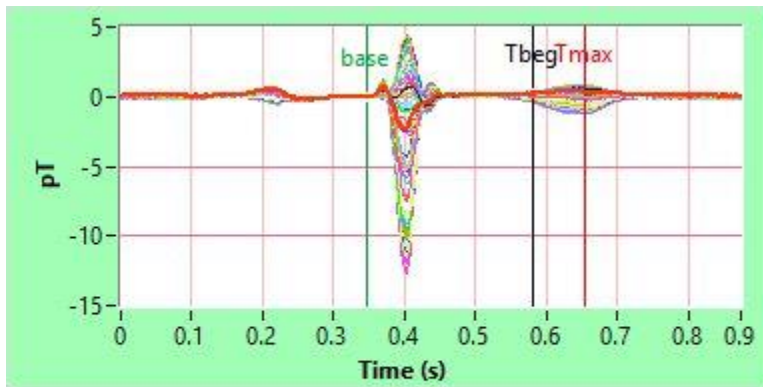
D.K., male, 60yrs, 178cm, 85kg



T-score rest

D.K., male, 60yrs, 178cm, 85kg

healthy, male, 60yrs, 178cm, 79kg



	Value	Score
Current moment dynamics	1.94	0.00
Current angle maximum	80.07	0.00
Current angle minimum	18.28	0.00
Current angle dynamics	57.61	0.00
Map angle maximum	-66.04	0.00
Map angle minimum	-78.69	0.00
Map angle dynamics	7.26	0.00
Distance dynamics	19.57	0.00
Ratio dynamics	0.26	0.00
Total score	Normal	0.00

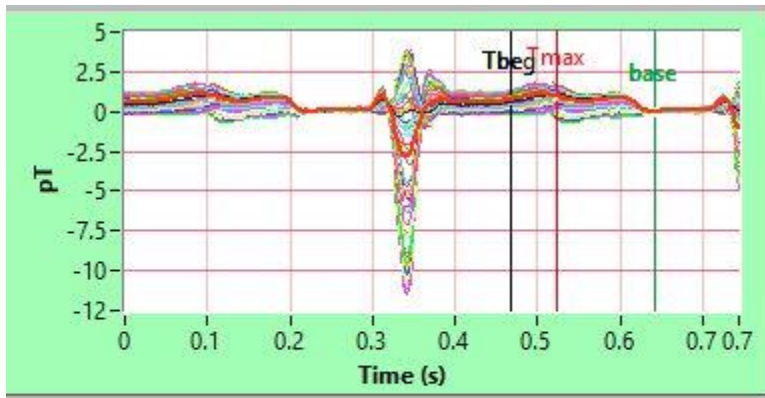
0

	Value	Score
Current moment dynamics	14.40	0.00
Current angle maximum	33.54	0.00
Current angle minimum	29.90	0.00
Current angle dynamics	2.17	0.00
Map angle maximum	-60.26	0.00
Map angle minimum	-60.26	0.00
Map angle dynamics	0.00	0.00
Distance dynamics	0.00	0.00
Ratio dynamics	0.04	0.00
Total score	Normal	0.00

0

T-score stress

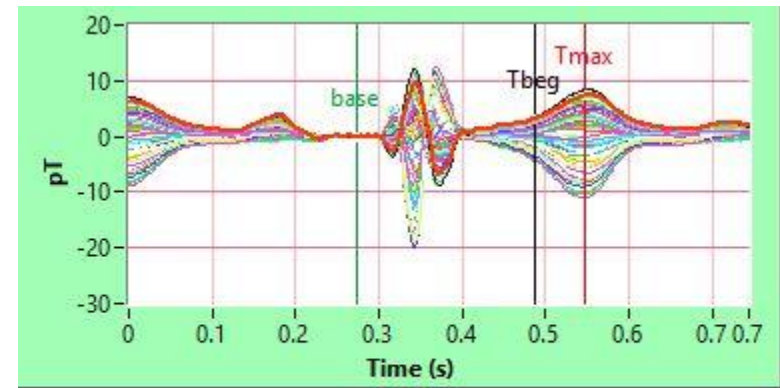
D.K., male, 60yrs, 178cm, 85kg



	Value	Score
Current moment dynamics	1.53	0.00
Current angle maximum	4.32	0.00
Current angle minimum	-120.25	0.00
Current angle dynamics	121.52	0.00
Map angle maximum	155.56	1.00
Map angle minimum	-90.00	0.00
Map angle dynamics	245.56	1.00
Distance dynamics	60.77	1.00
Ratio dynamics	11.20	1.00
Total score	Suspicious	4.00

3

healthy, male, 60yrs, 178cm, 79kg



	Value	Score
Current moment dynamics	29.26	0.00
Current angle maximum	36.41	0.00
Current angle minimum	25.24	0.00
Current angle dynamics	6.52	0.00
Map angle maximum	-66.80	0.00
Map angle minimum	-69.44	0.00
Map angle dynamics	2.64	0.00
Distance dynamics	18.56	0.00
Ratio dynamics	0.10	0.00
Total score	Normal	0.00

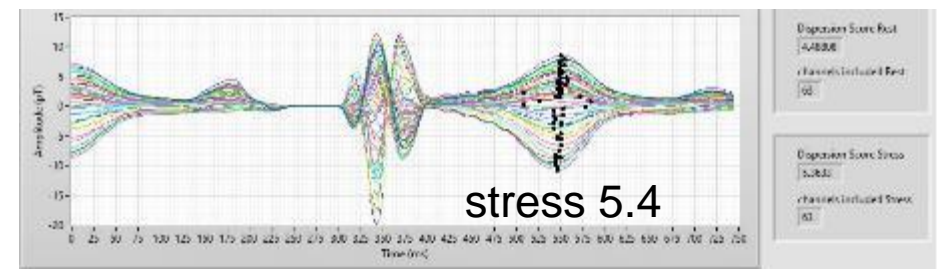
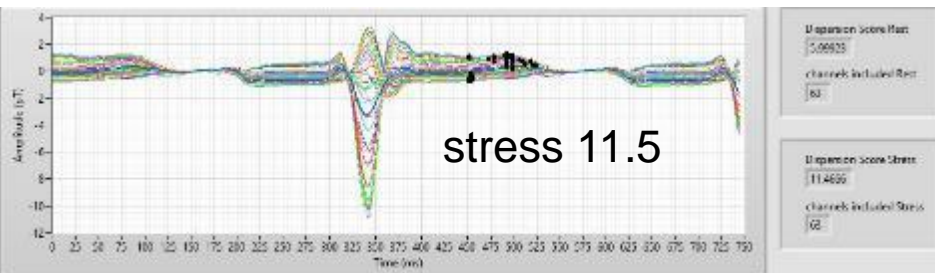
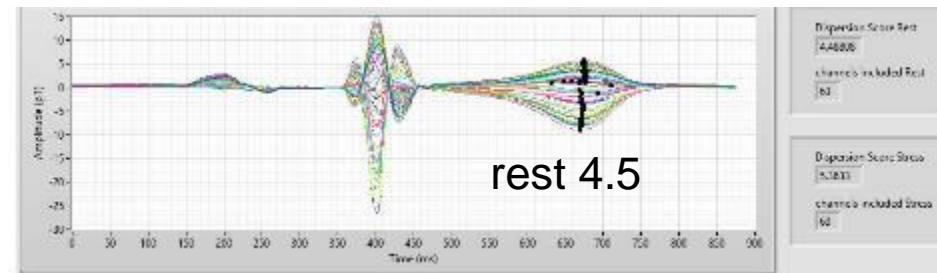
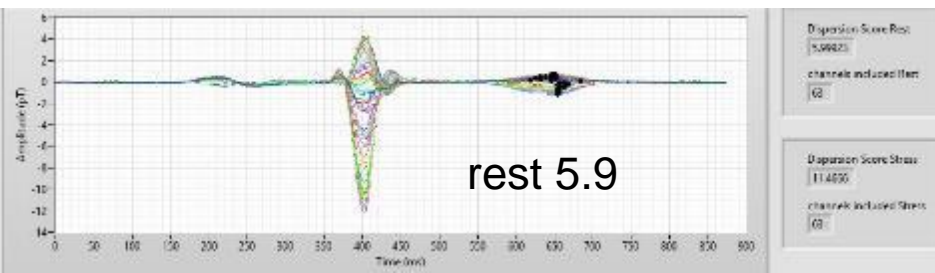
0

T-dispersion score



D.K., male, 60yrs, 178cm, 85kg

healthy, male, 60yrs, 178cm, 79kg

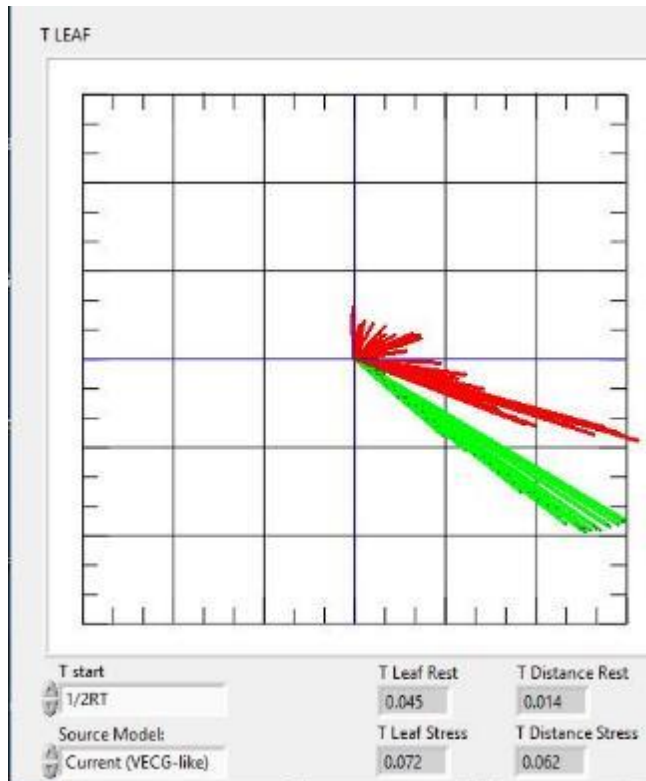


rest 0 stress 1

rest 0 stress 0

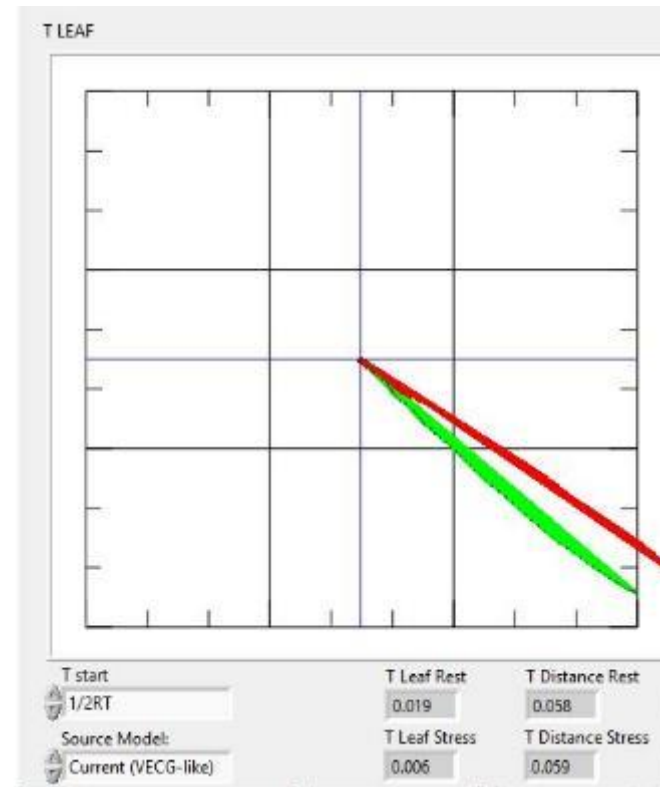
VMCG-score R-T/2

D.K., male, 60yrs, 178cm, 85kg



rest 0 stress 1

healthy, male, 60yrs, 178cm, 79kg

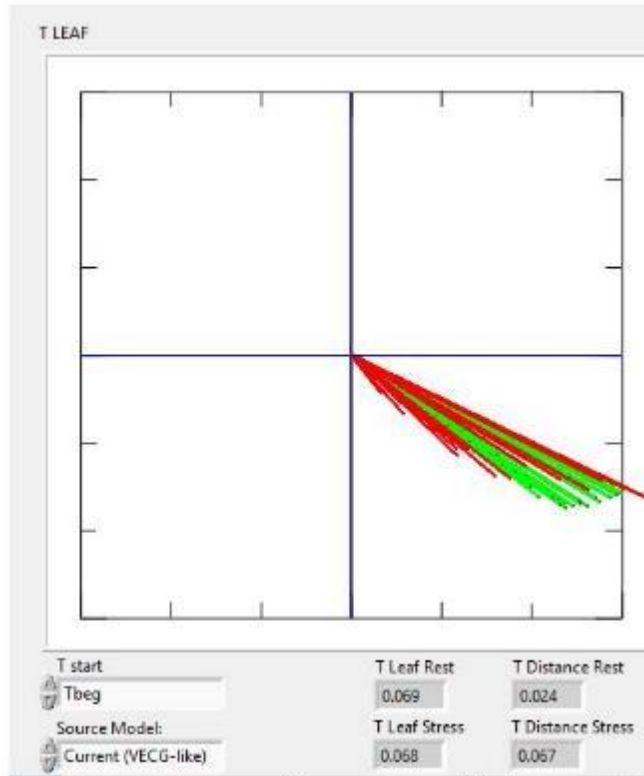


rest 0 stress 0

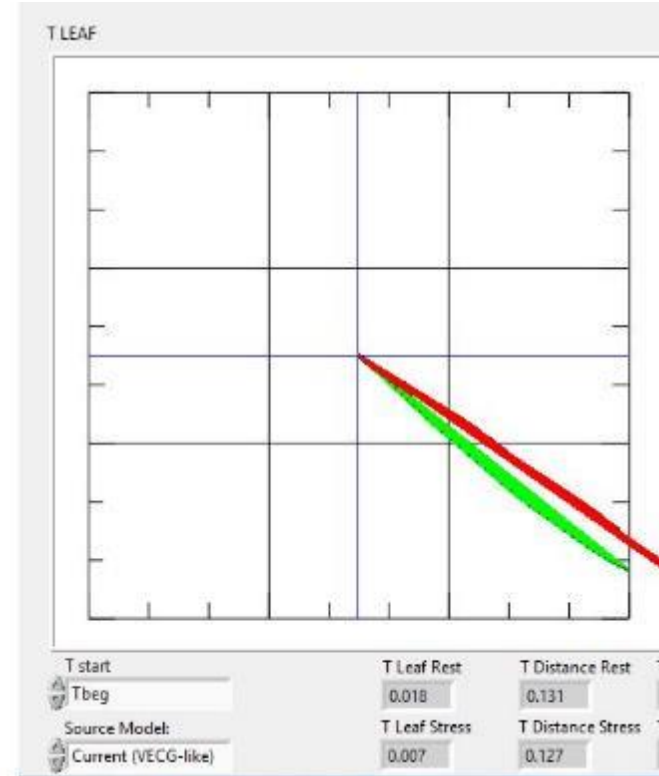
VMCG-score Tbeg



D.K male, 60yrs, 178cm, 95kg



healthy, male, 60yrs, 178cm, 79kg



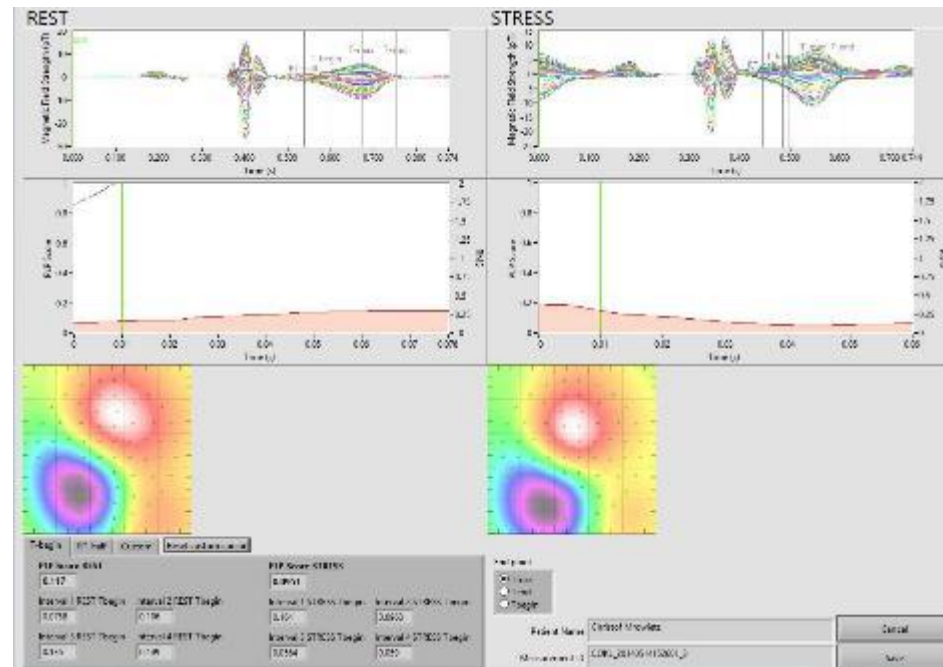
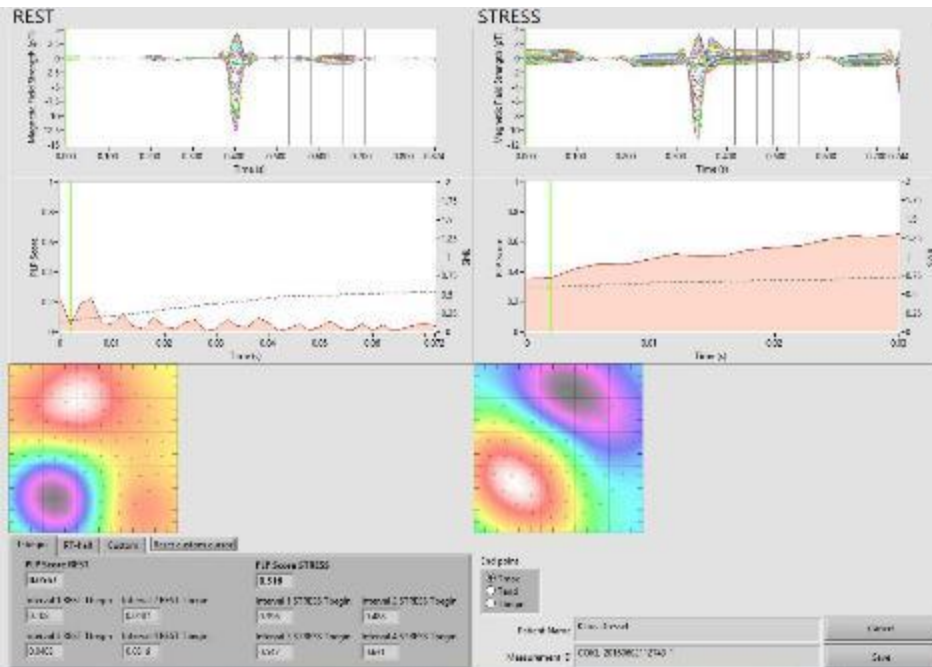
rest 1 stress 1

rest 0 stress 0

PLP-score

D.K., male, 60yrs, 178cm, 85kg

healthy, male, 60yrs, 178cm, 79kg



rest 0 stress 1

rest 0 stress 0

total MCG-score



D.K., male, 60yrs, 178cm, 85kg

healthy, male, 60yrs, 178, 79kg

rest 1/7

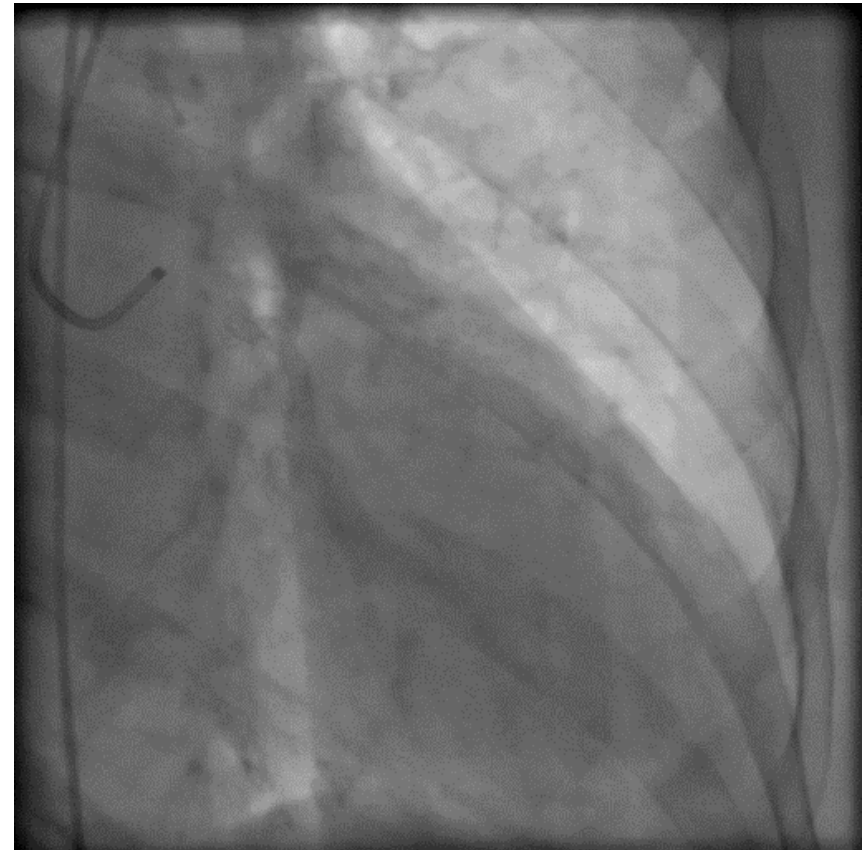
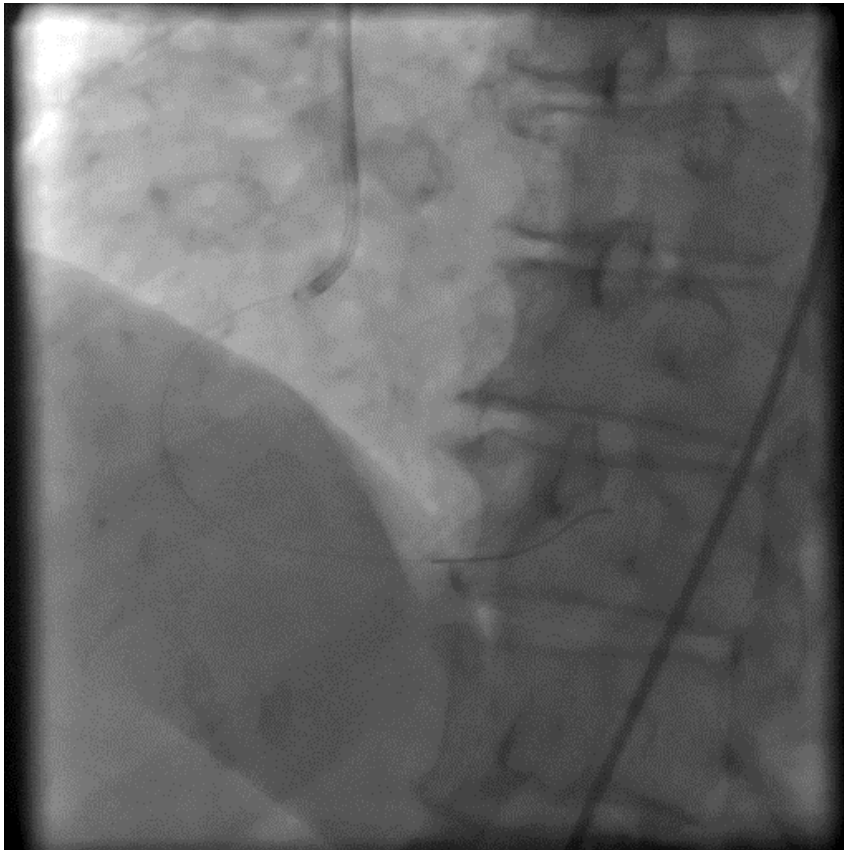rest 0/7

stress 7/7

stress 0/7

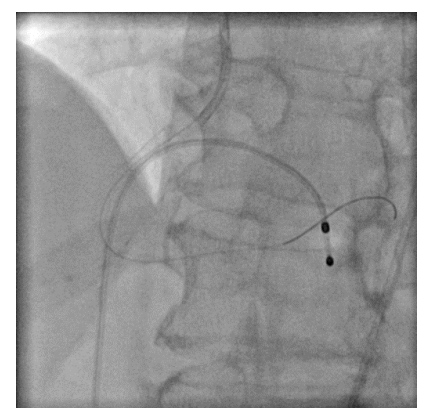
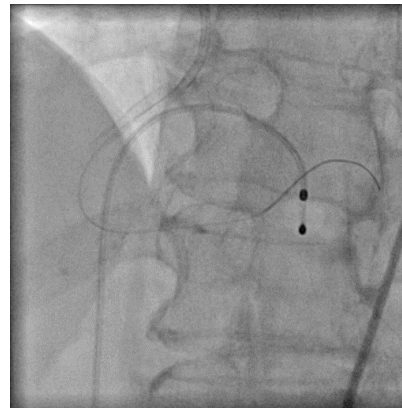
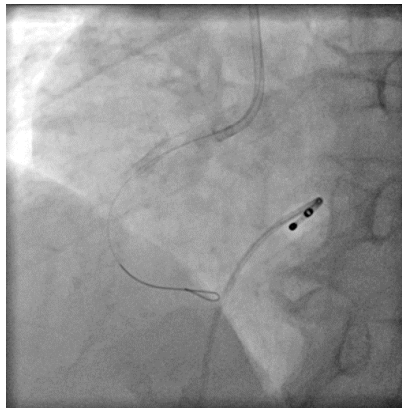
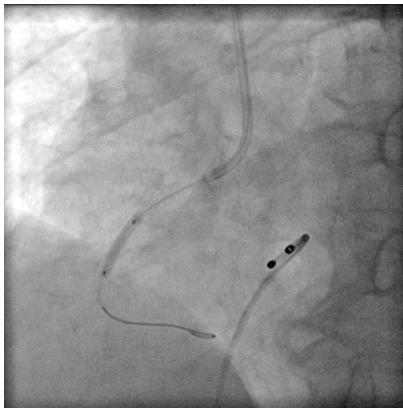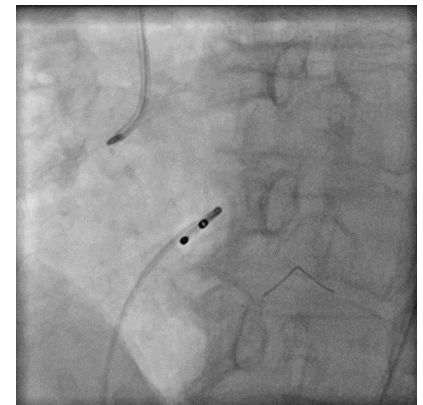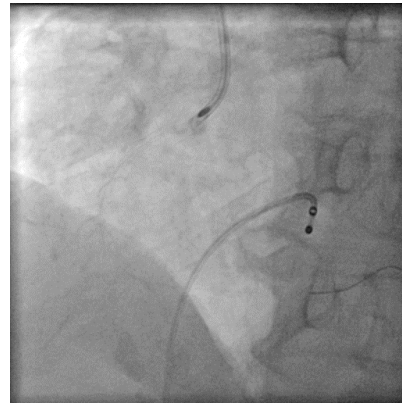
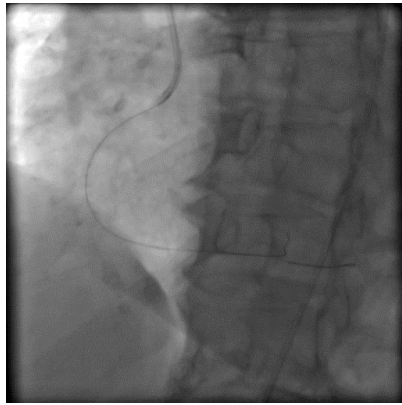
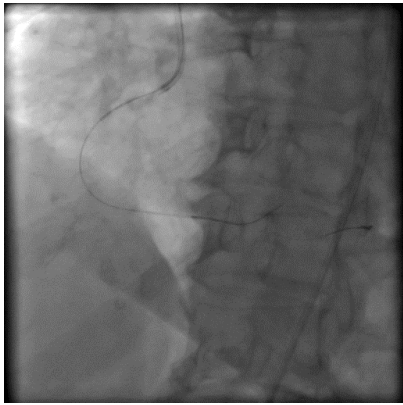
Microvascular dysfunction

S.M. ♀, 80 yrs, 2-VD, asymptomatic



Microvascular dysfunction

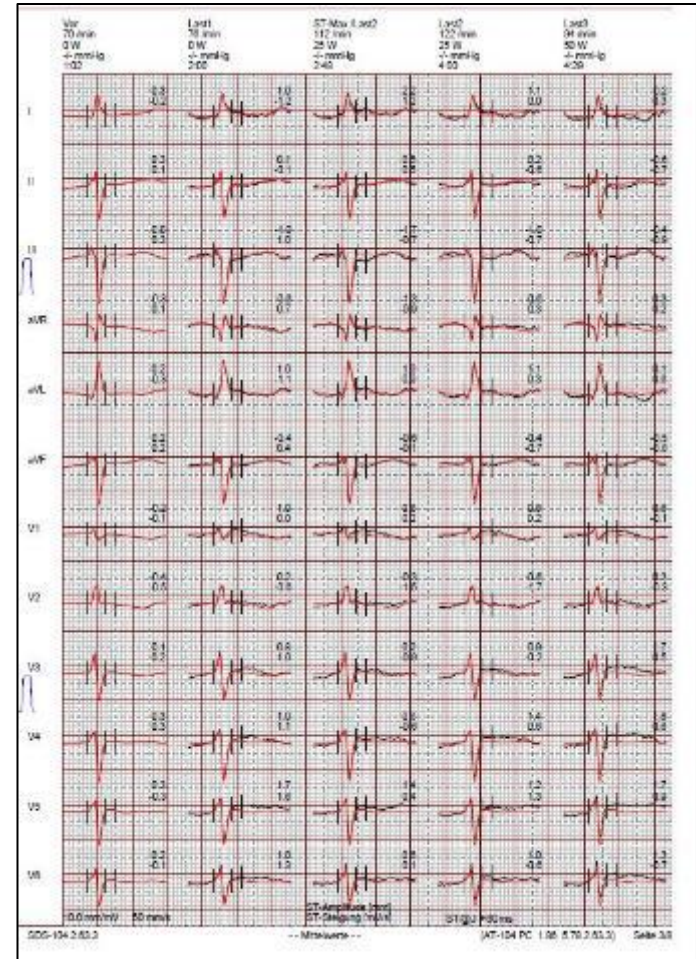
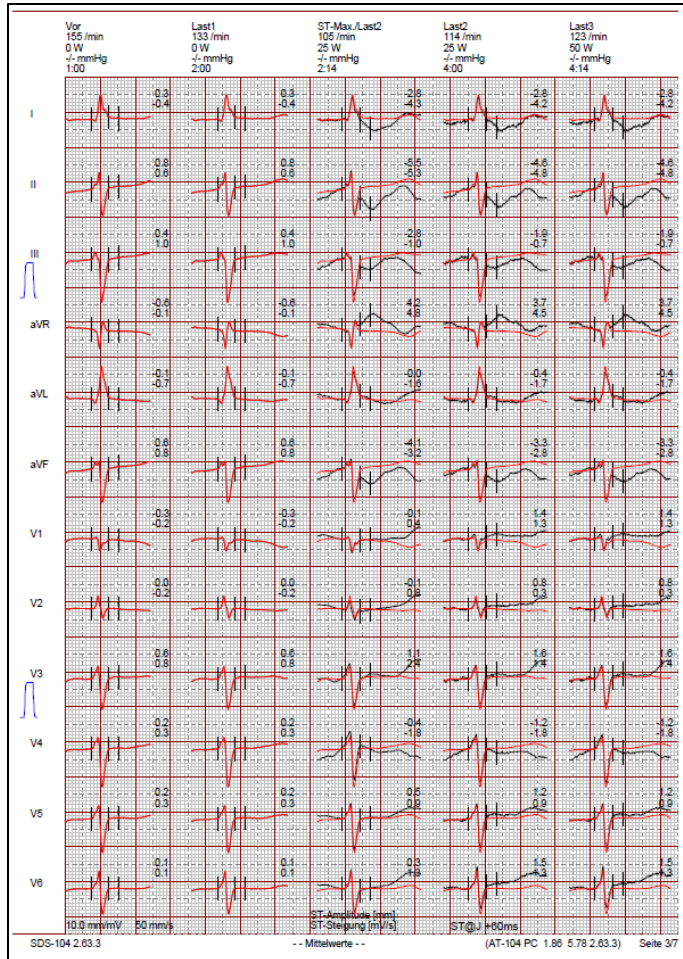
S.M. ♀, 80 yrs, 2-VD, asymptomatic
multiple PTCA, multiple rotablations, multiple stents



Microvascular dysfunction

S.M. ♀, 80 yrs, 2-VD, angina post PCI

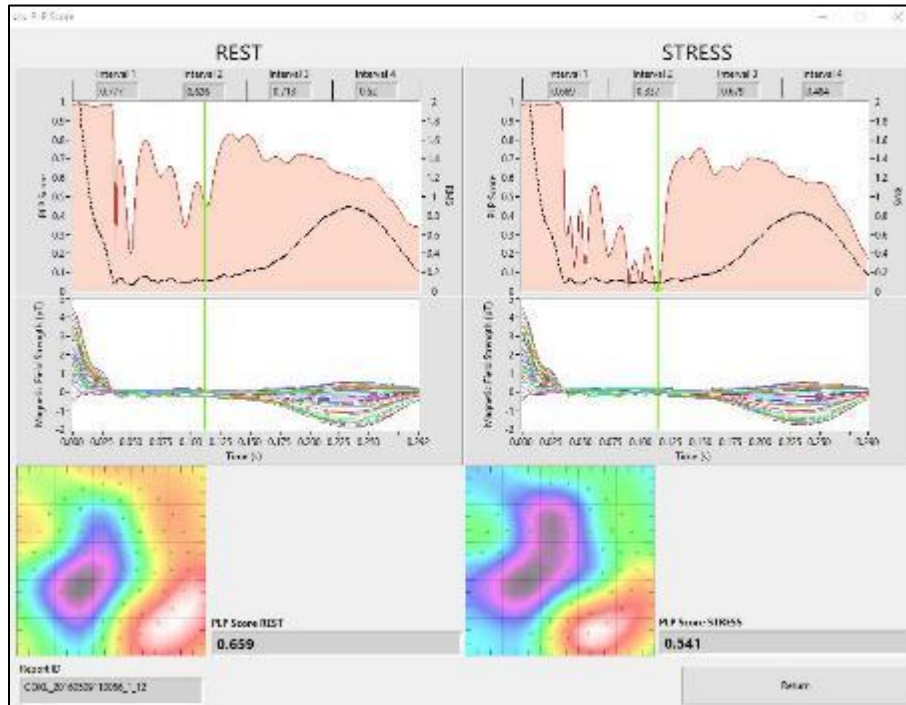
12-lead exECG



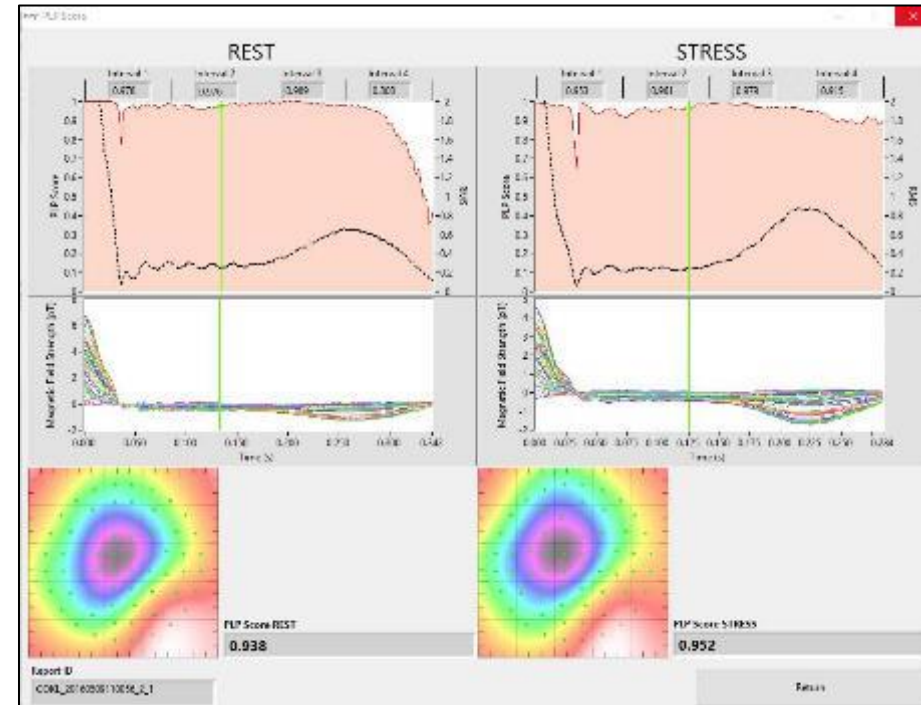
Microvascular dysfunction

S.M. ♀, 80 yrs, 2-VD, angina post PCI

magnetic field ratio



Pre-PCI



Post-PCI

Conclusions



- **MCG is an attractive alternative diagnostic tool in CAD and arrhythmias due to its non-invasive, contactless, highly sensitive, and excellent diagnostic accuracy.**
- **For the detection of myocardial ischemia in patients with ACS at admission, MCG was far superior to the ECG.**
- **MCG may become the gold standard diagnostic tool defining myocardial ischemia.**

If you want to know...

Non-invasive, Contactless,
No contrast,
No arterial puncture

